Hospital Library
MAY 1933

OL. XCVII MAY, 1933 No. 5

ANNALS of SURGERY

A Monthly Review of
Surgical Science and Practice

Edited by

LEWIS STEPHEN PILCHER, M.D., LL.D., of New York

Associate Editors

W. SAMPSON HANDLEY, M.S., M.D., F.R.C.S., of London
JAMES TAFT PILCHER, B.A., M.D., of New York
WALTER ESTELL LEE, M.D., of Philadelphia

Official Publication of the American Surgical Association, of the New York Surgical Society and the Philadelphia Academy of Surgery

CONTENTS

n Evaluation of the Tannic-Acid Treatment of Burns—*James B. Mason, M.D., Philadelphia, Pa.*, 641

he Treatment of Old Unhealed Burns—*John Staige Davis, M.D., Edward A. Kitlowshi, M.D., Baltimore, Md.*, 648

Study in Extensive Cutaneous Burns—*Monroe A. McIver, M.D., Cooperstown, N. Y.*, 670

rm-Chest Adhesions and Their Plastic Reconstruction—*Jacob Kulowski, M. D.*, 683

rtificial Inguinal Hernia—*Eske Harry Windsberg, M.D., Providence, R. I.*, 693

ernia Into the Prevesical Space—*Irving J. Walker, M.D., Boston, Mass.*, 706

tersigmoid Hernia—*Denver M. Vickers, M.D., Stanley T. Fortuine, M.D., Cambridge, N. Y.*, 713

trangulated Femoral Hernia—*Virgil S. Counseller, M.D., Forest W. Cox, M.D., Rochester, Minn.*, 717

trangulated Femoral Cystocele—*Anthony P. Vastola, M.D., Waterbury, Conn.*, 724

steomyelitis of the Skull—*Ira Cohen, M.D., New York, N. Y.*, 733

The Use of Continuous Intravenous Infusions in Acute Abdominal Crises—*Isidor S. Ravdin, M.D., Charles G. Johnston, M.D., Philadelphia, Pa.*, 749

Tropacocaine Hydrochloride in Spinal Anæsthesia—*Joseph A. Lazarus, M.D., Chas. J. Pick, M.D., Arthur A. Rosenthal, M.D., New York, N. Y.*, 757

Torsion of the Omentum—*Charles E. Farr, M.D., R. F. Bachmann, M.D., New York, N. Y.*, 766

Bilateral Snapping Thumbs—*Edward L. Compere, M.D., Chicago, Ill.*, 773

Transactions of the New York Surgical Society—*Stated Meeting held November 9, 1932*, 778

Transactions of the Philadelphia Academy of Surgery—*Stated Meeting held October 3, 1932*, 786

Brief Communications—An Inter-ringed Clamp—*William L. Wolfson, M.D., Brooklyn, N. Y.* Progressive Lenticular Degeneration—*Francis J. Halford, M.D., Honolulu, Hawaii.* The Principle of the Loop in Bandaging—*Victor Carabba, M.D., New York, N. Y.* Removal of Brilliant Green Stains—*Joseph K. Narat, Chicago, Ill.*, 794

. B. LIPPINCOTT COMPANY
ONTREAL PHILADELPHIA LONDON

Entered at the Post Office at Philadelphia and admitted for transmission through the mails at second-class rates. Price $10.00 a year.

LAST CHANCE TO GET

ADAIR—CANCER

$10.00

THIS book of international contributions to the study of Cancer, in honor of James Ewing, is arranged in four parts: Cancer in its General Relations; Cancer Research; Regional Cancer; Radium and Roentgen Ray Therapy. Has fifty-three articles contributed by the leaders from America, Belgium, Canada, England, France, Germany, Italy, Holland and Sweden. Limited edition.

Edited by FRANK E. ADAIR. 493 pages. Illustrated.

J. B. Lippincott Company

Philadelphia, Since 1792

London, Since 1875 *Montreal, Since 1897*

FIVE TIMES STRONGER THAN MORPHINE

Dilaudid

dihydromorphinone hydrochloride

Dilaudid possesses several advantages over morphine as an analgesic and sedative in pre-operative and post-operative procedure - acts quicker, has less marked secondary effects, and does not constipate. It is used in doses of 1/32 to 1/16 grain. : : : : : :

Hypodermic ampules and tablets, 1/32 grain
Oral tablets, rectal suppositories, 1/24 grain
Powder, readily soluble.

Further information upon request. Send your narcotic order for a sample tube of 20 hypodermic tablets 1/32 grain each.

BILHUBER-KNOLL CORP. - 154 OGDEN AVENUE JERSEY CITY, N. J.

ANNALS *of* SURGERY

Vol. XCVII MAY, 1933 No. 5

AN EVALUATION OF THE TANNIC-ACID TREATMENT OF BURNS*

By James B. Mason, M.D.
of Philadelphia, Pa.

It is desired to contrast and evaluate certain results obtained in the treatment of two series of burn cases at the Presbyterian Hospital. Particular attention is directed to the mortality statistics in children, statistics of late fatal secondary infection, and to the hospitalization as a feature of economic significance. The one series of patients received tannic therapy, while the other group was treated by a variety of methods.

Review of Experimental Literature.—While it was hardly considered within the scope of this paper to discuss the physiology of burns, there has been so much recent noteworthy experimental work that a brief mention of certain papers will serve to correlate the newer physiological concept of burns with the tannic-acid therapy. In this field the researches of Underhill and his co-workers and of Blalock and his associates have been outstanding.

When tannic acid was introduced into burn therapy, the belief was, and is yet widely held to, that this agent by coagulating the burned tissues prevented the absorption of poisonous products, and thus lessened the toxæmia. Underhill,[9] working with dogs, has presented several bits of evidence that controvert this older contention. He found that absorption from the untreated burned surface was markedly retarded over normal skin as measured by the rate of disappearance of certain dyes. Underhill,[10] in endeavoring to refute the burn toxin theory, showed that the extracts of burned tissues and like preparations of normal skin produced almost identical reactions, when injected into test animals. He stated that the altered physiology caused by blood concentration would adequately explain the toxæmia. In substantiation of Underhill's contention Harrison and Blalock[8] have recently reported that the grafting of burned skin on a fresh wound in a healthy dog was not productive of toxæmia, and further that the transfusion of whole blood obtained from a severely burned canine donor did not produce symptoms of toxæmia in a normal dog.

Following an experimental burn there is a rapid accumulation of an œdema in the adjacent tissues. Underhill, *et al.*,[11, 12, 13] and Beard and Blalock[2] have shown that this œdema fluid has essentially the chemical composition of blood plasma. In dogs, due to the structure of the skin, the œdema fluid does not escape, as in humans, into large blebs. It is gradually

* Read before the Philadelphia Academy of Surgery, October 3, 1932.

resorbed. This anatomical characteristic of the dog's skin presented a means of determining the degree of fluid loss from the circulation to the œdema. It was shown in animals, in which about one-sixth of the body area had been burned,[11] that there was a marked loss of fluid from the blood plasma amounting to 70 per cent. in one dog. This work was confirmed by Blalock[4] who found that the average total fluid loss from the volume of circulating blood in eighteen animals, which had received exactly one-half of the body area burned, was 57 per cent. He suggested that the beneficial effects of tannic acid in man were probably a result of the prevention of fluid loss, rather than by the prevention of absorption of toxins.

The review of the experimental literature has brought forth certain bits of evidence, which are in harmony with, and aid in the interpretation of, clinical results of tannic-acid therapy. The concept may be adopted that the impervious non-irritating coagulum bars the loss of fluid from the circulation by preventing bleb formation, as suggested by Blalock. This lessens the degree of blood concentration somewhat, and aids in ameliorating the toxæmia attending this phenomenon. Further, the protective coagulum effects a "chemical debridement" by promptly fixing all of the devitalized cells and the underlying tissue presents a most favorable surface for the rapid ingrowth of epithelium.

Study of Mortality.—It is well known that mortality statistics have been greatly improved following the adoption of tannic-acid therapy. Beekman's[3] mortality fell from 27.8 per cent. to 14.9 per cent., and Bancroft and Rogers[1] reported a reduction of from about 40 per cent. to about 20 per cent., Glover[6] recently reported a mortality of 9.6 per cent. in a study of 310 burned patients treated by tannic acid during the years 1926 to 1931, whereas a series of 121 cases treated from 1922 to 1926 by numerous methods showed a 14 per cent. death rate.

The technic of local application of tannic acid and the general treatment of the patients have been too often described to merit discussion.

The methods of treating burns in this hospital with tannic acid was discussed in 1928 by Griffith.[7] The only deviation from Griffith's description of technic has been in the use of stronger aqueous solutions of tannic acid than the 2½ per cent. solution recommended by Davidson.[5] We are in agreement with Glover and others that the coagulum is more rapidly formed by the 5 per cent. and 10 per cent. fresh aqueous solutions. We have used the preparations of tannic acid suspended in water-soluble jelly base on but few cases and while the results have been uniformly satisfactory, the number of cases is too small for comment.

The many clinical benefits which Davidson and others described are too well known, and have been so often confirmed that their mention in this paper would be superfluous.

In the series of cases from the Presbyterian Hospital, there were ninety-one patients treated by many methods during the period January 1, 1922, to November 17, 1925; and ninety-seven cases treated by tannic acid during

the period November 17, 1925, to December 31, 1931, inclusive. In certain of the data, children and adults have been separated, the former comprising all patients of thirteen years and under.

Many of the adult deaths noted in Table I were the result of industrial accidents. It may be stated in this regard, that hospitals deriving their casualties largely from factories and other industries will have higher mortality rates, and this variation as to source of burned patients explains the variance of mortality figures in the literature.

The total mortality for the first series was twenty-six deaths in ninety-one patients or 28.5 per cent. Further classification showed forty-seven adults

TABLE I

Mortality

	Total Cases	Deaths	%	Adult Cases	Adult Deaths	%	Children	Deaths	%
1922	18	4	22.2	6	2	33.3	12	2	16.6
1923	35	12	34.3	19	5	26.3	16	7	44.4
1924	16	6	37.5	10	4	40.0	6	2	33.3
1925	24	4	18.1	12	2	16.6	10	2	20.0
Total	91	26	28.5	47	13	27.4	44	13	29.5
1925	6	0	0	1	0	0	5	0	0
1926	14	4	28.5	8	3	37.5	5	1	20.0
1927	12	2	16.6	5	1	20.0	7	1	14.1
1928	20	2	10.0	12	2	16.6	8	0	0
1929	12	1	8.3	7	0	0	5	1	20.0
1930	16	0	0	8	0	0	8	0	0
1931	17	4	23.5	11	3	27.2	6	1	16.6
Total	97	13	13.3	52	9	17.3	45	4	9.3

with thirteen deaths—27.4 per cent.—and forty-four children with thirteen deaths—29.5 per cent.

In contrast, following the adoption of tannic-acid therapy, in this series of ninety-seven patients there were thirteen deaths in all—13.3 per cent., a marked lowering of mortality. A substantial reduction of the death rate was found in the fifty-two adults with nine deaths—17.3 per cent. However, the most striking benefit of this form of therapy was shown in the forty-five children, in which group there were four deaths—9.3 per cent. This reduction of mortality by more than threefold is impressive, since the two series of children were found to be wholly comparable as to types of burns.

Late Fatal Secondary Infection.—In discussing their mortality figures, Glover[6] and Beekman[3] found that the majority of their patients who succumbed died within the first forty-eight hours, and that in the remainder

a fatal termination was the result of secondary infections, sepsis, *etc.*, at various times after this first period. Following the introduction of tannic

CHART I

TOTAL DEATHS	26	
WITHIN 48 HRS.	17	65.4%
WITHIN 6-10 DAYS	7	26.9%
AFTER 10 DAYS	2	7.7%

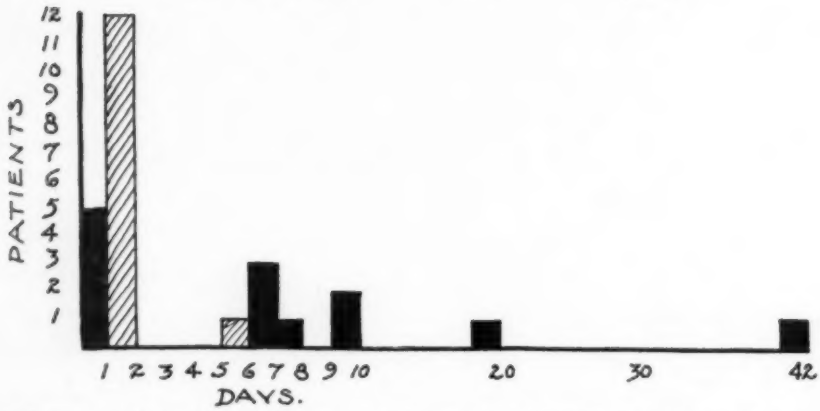

acid they noted fewer deaths from infections, and rightly concluded that this therapy was a factor in lowering the incidence of infections. A similar study has been made, with the results appearing in Charts I and II. It will be

CHART II

TOTAL DEATHS	13	
WITHIN 48 HRS.	11	84.6%
WITHIN 6-10 DAYS	1	7.7%
AFTER 10 DAYS	1	7.7%

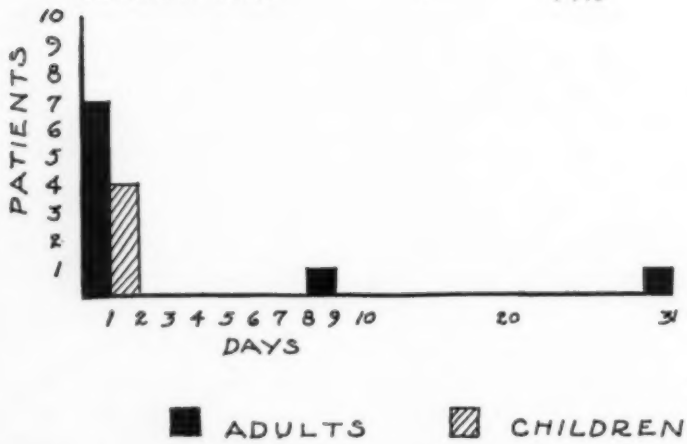

observed in these charts that before the employment of tannic acid, seventeen patients (65.4 per cent.) succumbed directly to the burn within forty-eight hours and that nine deaths (26.9 per cent.) were from infections, after the

first forty-eight-hour period. Contrasting with these percentages are those obtained from the series treated by tannic acid; eleven deaths occurred within forty-eight hours (84.6 per cent. of the deaths) and two deaths (15.4 per cent.) occurred after the first forty-eight hours. From these figures and on the basis of reports of other observers it is evident that tannic acid has exerted a definite influence in lowering the incidence of late fatal secondary infection of burns.

Consideration of the Morbidity and Hospitalization.—In order to determine the efficacy of a therapeutic agent, the effect upon morbidity must be obtained following a comparison of statistics of periods prior to and following its introduction. A lowering of morbidity is of definite economic consequence.

In order to determine whether the period of hospitalization was shortened following the introduction of tannic acid, it was decided to select patients from both groups, who had 20 per cent. or more of the body involved by the burn, and to study them from this point of view.

It is exceedingly difficult to foretell the length of hospitalization when the extent and degree of the burn is known. The age, sex of the patient, location and degree of the burn, infection, and the unknown factor spoken of as resistance, are all factors affecting the rate of healing. However, bearing these uncontrollable features in mind and realizing that they will affect hospitalization periods of individual patients unpredictably, we may avail ourselves of the data for discussion of this economic phase of the paper.

The increase of extensively burned patients from eleven to nineteen represents a gain of 72 per cent. (Table II.) Among both adults and children there has been a gratifying increase in the saved columns of those suffering with extensive burns. This is accomplished in some instances at the expense of increased hospitalization, although in the main, as later figures will bring out, the period of hospitalization was definitely shorter.

There seems not the slightest doubt that the little boy of four—for example—who suffered a 50 per cent. plus burn, first, second, and third degrees, and who had a total hospital stay of 525 days and who for weeks was in attendance at surgical clinic, would have succumbed to his lesion with other preliminary treatment than tannic acid.

Data on periods of hospitalization were secured from abstracts of the histories in each group. The first series showed eleven patients with 679 days spent in the hospital, an average of 61.7 days per patient. The second series of nineteen patients spent 1,016 days in the hospital, an average of 53.5 days per patient. There is an average saving of 8.2 days per patient for the tannic-acid treated series, which represents a small but definite shortening of hospitalization per patient. Were the little boy, who was hospitalized 525 days omitted, the total hospital days for the tannic-acid series would be reduced to 491 days, or an average of 27.2 days per patient, and would represent a marked reduction in morbidity and hospitalization of 34.5 days.

Similar series would probably show a figure higher than 8.2 days but less than 34.5 days. It must be apparent that there is a definite reduction of hospitalization in burn patients treated by tannic acid, and that both the patient and the hospital budgets are beneficiaries. Another economic feature

TABLE II

Morbidity

ADULTS				CHILDREN			
Age	Degree of Burn	% Body Area	Days in Hospital	Age	Degree of Burn	% Body Area	Days in Hospital
1st Series 1922-November 1925							
22	1 & 2	25	24	7	2	20	120
24	1 & 2	40	28	21 mo	1,2,3.	20	41
				4	1 & 2	33 1/3	75
				4	2	30	140
				5	1 & 2	25	57
				7 mo	1 & 2	20	33
				6	1	20	11
				5	2	20	72
				22 mo.	2	40	65
2nd Series November 1925-1931							
23	1 & 2	30	31	2	1 & 2	30	40
18	2 & 3	25	24	2	1	20	4
40	2	20	7	3	2	20	59
23	2 & 3	20	92	4	1 & 2	20	11
29	2	25	13	7 1/2	1,2,3.	20	55
37	1,2,3.	50	70	5	2	25	26
37	1 & 2	20	9	5	3	20	27
55	1,2,3	20	40	4	3	50	525
				6	2 & 3	25	37
				2	1 & 2	25	29
				2	1	20	17

SUMMARY

of tannic-acid therapy may be briefly alluded to—the lessened cost of therapeutic agents and apparatus, and the saving of time by hospital personnel in caring for patients as contrasted to the other forms of therapy. These features represent a considerable saving per patient to the hospital.

(1) A brief review of the recent experimental work on the physiology of burns* with relation to tannic-acid therapy has been given.

(2) The analysis of mortality statistics showed a reduction of total mortality following the introduction of tannic-acid therapy of from 28.5 per cent. to 13.3 per cent. Of especial interest was the group of children in whom there was marked reduction from 29.5 per cent. to 9.3 per cent.

(3) Further analysis of deaths showed in the first series that 65.4 per cent. occurred within forty-eight hours and 34.6 per cent. occurred in the sepsis period, while in the second series 84.6 per cent. died within forty-eight hours, and 15.4 per cent. succumbed during the infection period.

(4) Morbidity and hospitalization were discussed and contrasted on the basis of two groups of patients, who suffered extensive burns amounting to 20 per cent. or more of the body area. In the first group there were eleven patients, who were hospitalized an average of 61.7 days per patient, while in the group treated by tannic acid there were nineteen patients, who were hospital inmates an average of 53.5 days. In this second group there was an average decrease of 8.2 hospital days per patient, which represented a small but definite economic benefit.

BIBLIOGRAPHY

[1] Bancroft, F., and Rogers, C.: The Treatment of Cutaneous Burns. ANNALS OF SURGERY, vol. lxxxiv, pp. 1–18, 1926.

[2] Beard, J. W., and Blalock, A.: The Composition of Fluid That Escapes from the Blood after Burns. Arch. Surg., vol. xxii, pp. 617–625, 1931.

[3] Beekman, F.: Tannic Acid Treatment of Burns. Arch. Surg., vol. xviii, p. 803, 1929.

[4] Blalock, A.: The Importance of Local Loss of Fluid in the Production of Low Blood Pressure after Burns. Arch. Surg., vol. xxii, pp. 610–616, 1931.

[5] Davidson, E. C.: Tannic Acid Treatment of Burns. Surg., Gynec., and Obst., vol. xli, pp. 202–221, 1925.

[6] Glover, D. M.: Six Years of the Tannic Acid Treatment of Burns. Surg., Gynec., and Obst., vol. liv, pp. 798–805, 1932.

[7] Griffith, G. C.: Therapy in Burns in the Presbyterian Hospital in Philadelphia. Internat. Clin., vol. iv, pp. 129–131, 1928.

[8] Harrison, W. G., and Blalock, A.: A Study of the Cause of Death Following Burns. ANNALS OF SURGERY, vol. xcvi, pp. 36–39, 1932.

[9] Underhill, F. P., Kapinow, R., and Fisk, M. E.: Changes of Capillary Permeability Induced by Superficial Burns. Am. Jour. Physiol., vol. xcv, pp. 315–324, 1930.

[10] Underhill, F. P.: The Alleged Toxin of Burned Skin. Jour. Lab. and Clin. Med., vol. xvi, pp. 823–830, 1931.

[11] Underhill, F. P.: The Composition of the Edema Fluid Resulting from Superficial Burns. Am. Jour. Physiol., vol. xcv, pp. 330–333, 1930.

[12] Underhill, F. P., Fisk, M. E., and Kapisnow, R.: The Extent of Edema Fluid Formation Induced by Superficial Burns. Am. Jour. Physiol., vol. xcv, pp. 325–329, 1930.

[13] Underhill, F. P., Fisk, M. E., and Kapisnow, R.: Relation of Blood Chlorides to Chlorides of Edema Fluid. Am. Jour. Physiol., vol. xcv, pp. 334–338, 1930.

* The burns considered were due to fire, steam, boiling water or other liquids, and electricity.

THE TREATMENT OF OLD UNHEALED BURNS

By John Staige Davis, M.D.

and

Edward A. Kitlowski, M.D.

of Baltimore, Md.

The purpose of this paper is to call attention to that group of old (extensive) burns, which have been treated unsuccessfully elsewhere, whose healing has for one reason or another been delayed, and who have been admitted to the hospital from months to years after the original burns occurred. We will consider only the problem of healing the granulating areas and not the permanent relief of scar contractures.

These cases are seldom received with enthusiasm in a general surgical clinic on account of the length of time they must stay in the hospital and because of the great amount of medical, surgical and nursing care they require. Nevertheless, one or more of these old burns can usually be found in every large clinic, and inasmuch as they eventually have to be treated by the Plastic Division, it has become the custom here to refer them to us in the unhealed state. We believe this is a wise solution as we are interested in the healing of intractable wounds, in preventing avoidable scar contractures and in relieving these contractures when they occur.

The problem which usually presents itself is a patient in extremely poor physical and mental condition with more or less extensive unhealed areas, which are frequently complicated by serious scar contractures, or beginning scar contractions. The continuous loss of fluids through the granulating areas and the absorption from these areas, which are always infected, added to the pain and invalidism, have caused the patients to lose ground steadily and by the time they are admitted they have reached a stage of lowered vitality where progressive healing has ceased, where the granulations are unhealthy and where grafting or other operative procedures cannot be carried out successfully without a long and careful building-up process.

In order to illustrate some of the difficulties met in treating these old unhealed burns and to show the methods which were used to induce healing and which have been successful in our hands, we have selected six cases from our series at the Union Memorial Hospital, which will give an idea of some of the types encountered. Three of these patients are children and three are adults, and, for convenience, we will consider them in these two groups.

Case Reports

Group I.—Case I.—An eleven-year-old boy was admitted to the Union Memorial Hospital in Baltimore, June 8, 1929. In June, 1928, his clothes caught fire and he was severely burned on the right side of the body. He was taken to a hospital elsewhere for treatment and remained there for five months. He was then cared for at home until

his admission about one year after the accident. He was extremely emaciated and anæmic and was lying on his left side with his legs and thighs flexed. There was an unhealed area involving the right shoulder, arm and forearm down to the wrist with only one patch of epithelium about two by four centimetres just above the elbow. The forearm was flexed at the elbow and was adherent to the arm. The arm and forearm were both adherent to the chest-wall, causing complete obliteration of the axilla. The elbow was drawn backward beyond the chest-wall, thus preventing the patient from

Fig. 1A.

Fig. 1B.

Figs. 1A and B.—(Case I.) Condition of the patient on admission one year after being burned. Note the extensive unhealed areas, also the contractures of the right arm, thighs and legs.

lying upon his back. There was some motion in the fingers and the wrist could be partially extended passively. The hand rested upon the granulations on the chest-wall. The chest-wall and the upper abdominal wall on the right side were covered with unhealthy granulations. The right hip and right thigh on its lateral aspect were covered with very pale, œdematous and exuberant granulation tissue. Both thighs were flexed on the abdominal wall, both legs on the thighs, and could not be extended. (Figs. 1 and 2.) There were some chest râles and a cough. The temperature ranged to 101° Fahren-

heit daily. *Urinalysis* was negative. *Blood Examination.*—Hæmoglobin, 48 per cent. Leucocytes, 8,900. Clotting time, six minutes. The Wassermann reaction was negative. The blood group was IV.

FIG. 2A.

FIG. 2B.

FIGS. 2A and B.—(Case I continued.) The right arm and forearm are adherent to each other and to the chest-wall. Note the angle at which the arm is adherent to the chest causing the elbow to be thrown backwards and preventing the patient from lying upon his back. The hand can be raised, but there was no active motion in the wrist. There is a small area of skin on the forearm near the elbow.

Progress in Hospital.—He was placed in bed upon sterile sheets under a tent kept at about 99° Fahrenheit by electric bulbs, and the granulating areas were treated in preparation for grafting. A transfusion of 250 cubic centimetres of whole citrated blood was given June 24, sixteen days after admission, which raised the hæmoglobin to 50 per cent.

Two days later small deep grafts were taken from the normal skin on the right abdominal wall under ½ per cent. novocaine anæsthesia and were scattered over the whole granulating area several centimetres apart. The treatment of the grafts under closed

FIG. 3A.

FIG. 3B.

FIGS. 3A and B.—(Case I continued.) One month after admission. The larger grafts had been transplanted nine days and the smaller grafts two days. Note the area upon the abdominal wall from which the first set of grafts was taken.

dressings for the next few days caused an increase in the temperature and a drop in the hæmoglobin until it fell to 43 per cent. July 5, eight days after the first grafting, small deep grafts were taken from the right lumbar region under local anæsthesia and placed in the intervals between those previously planted. (Fig. 3.) These were again suc-

cessful and the general condition of the patient began to improve so that six days after the second grafting the hæmoglobin had risen to 47 per cent. and the areas were rapidly covering with epithelium. July 15, ten days after the second grafting, another transfusion of 230 cubic centimetres of whole citrated blood was given and two days later, under nitrous oxide and oxygen anæsthesia, the adhesions between the arm and the chest-wall were partly separated, so that the arm could be brought forward. There was loss of blood and the hæmoglobin fell to 40 per cent. two days after the operation. The patient could now be placed upon his back and extension apparatus was applied to the legs to overcome the contractures. July 31 a third transfusion of 300 cubic centimetres of whole citrated blood was given and the hæmoglobin rose to 68 per cent. August 2 an attempt was made to straighten the arm at the elbow. This was only partly successful because of the danger of breaking the atrophied bones and tearing the blood-vessels and nerves. Traction was applied to the arm. August 29, small deep grafts were taken from the right buttock and placed upon the chest-wall and the arm where the adhesions had been broken. September 5, the legs were nearly straight and the hæmoglobin was 80 per cent. To hasten the healing of the few remaining uncovered areas more small deep grafts were taken from the abdominal wall under ½ per cent.

FIG. 4A.

FIG. 4B.

FIGS. 4A and B.—(Case I continued.) Three days before discharge. Healing is complete except for an area over the elbow. Note that the arm is loosened from the chest-wall. The type of healing can be seen on the thigh.

novocaine anæsthesia and were applied in the usual manner. By October the hæmoglobin had risen to 91 per cent. and the patient was permitted to sit up in a chair. An area in the axilla which had not healed entirely was grafted October 10 with small deep grafts taken from the left abdominal wall. By the end of November, the patient was able to walk and was discharged with some contracture of the elbow and in the right groin which will have to be dealt with later. There was a single unhealed area about three centimetres in diameter over the elbow. The duration of the hospitalization was one hundred and seventy-two days. (Fig. 4.)

One year later, the patient returned for further operative work and had a well-healed durable scar. (Fig. 5.)

CASE II.—A white boy, aged three years, was admitted to the Union Memorial Hospital June 12, 1931. Seven months before admission, he was severely burned when his clothes caught fire. He was treated at home by a physician. Three weeks before admission, a fine rash appeared over the body, the face became swollen, and he ran a high temperature. The rash disappeared in a few days but the burned area began to drain much more profusely and his general condition became very much worse. He was an anæmic, emaciated boy lying upon his back with the legs flexed so that the

soles of his feet rested upon the bed. There was some œdema of the face and scrotum. The legs could be extended with a little force, but the patient could not extend the right thigh completely. There was an unhealed area involving the right side of the body from the axilla to the groin and the inner side of the right arm almost to the elbow. The granulations were exuberant, pale, very œdematous and infected. (Fig. 6.) The temperature was 100° Fahrenheit. *Urinalysis* was negative excepting for some actively motile bacilli. *Blood Examination.*—Red cells, 3,160,000; white cells, 14,000; hæmoglobin, 45 per cent. The Wassermann reaction was negative. The blood group was IV.

Progress in Hospital.—The patient was placed in bed upon sterile sheets under a tent heated and lighted with electric bulbs to 99° Fahrenheit. Traction was applied to

FIG. 5A. FIG. 5B.

FIGS. 5A and B.—(Case I continued.) One year after discharge from the hospital. The healing is satisfactory and the scar is durable. Note the areas upon the abdominal wall and the buttock from which the small deep grafts had been taken. The patient has been serving a paper route since his discharge from the hospital and has returned for further work upon the elbow and wrist and right groin.

the left arm and leg in an attempt to combat contracting scar. The granulating surfaces were treated in preparation for grafting. June 17, 1931, a transfusion of 175 cubic centimetres of whole citrated blood was given. Two days later the hæmoglobin was 58 per cent. and the urine was negative. June 22, ten days after admission, small deep grafts were taken from the right thigh under ½ per cent. novocaine anæsthesia, and were scattered over the whole area. These were successful and by July 4 the hæmoglobin was 61 per cent. and the general condition was much improved. The area was about one-half the original size by July 10 (Fig. 7) when small deep grafts were again taken from the thigh under ½ per cent. novocaine anæsthesia and placed in the intervals between the original grafts. Both operations were done with the patient in his own bed

in about thirty minutes. The extension apparatus completely corrected the contracture of the leg (Fig. 8) and probably minimized the contraction in the axilla. In the latter part of July, a few additional small deep grafts were placed on an area near the axilla

FIG. 6.—(Case II.) Condition on admission seven months after the burn. The burn involved the right side of the body from the shoulder to the groin and the inner side of the right arm and also the axilla, almost to the elbow. The right leg could not be extended completely.

and on one near the groin to complete the healing. The patient was entirely healed and walking by the 5th of August and was discharged ten days later. (Fig. 9.) The total stay in the hospital was sixty-four days.

FIG. 7.—(Case II continued.) Five weeks after admission and three weeks after grafting was begun. The area is about one-half the original size. The arm had been kept in extension to combat contraction.

It will be necessary for this patient to return for the relief of scar contractures after six months of massage and passive motion.

CASE III.—A white girl, aged four years, was admitted to the Union Memorial Hospital October 14, 1930. In August, 1930, two months before admission, her clothes caught fire causing severe burns on the ears, neck, chest, arms, upper abdominal wall and on the left thigh. She had been treated elsewhere with Unguentine ointment for the first two days and then with tannic acid until October 6. Then attempts were made to remove the slough which caused pain and bleeding. The temperature began to rise as high as 104° daily and her general condition became so much worse that she was brought to Baltimore for treatment. She was an anæmic-looking girl lying in bed with the left leg flexed so that the sole of the foot rested upon the bed. There was an unhealed area involving the neck, anterior chest-wall, upper abdominal wall and both arms. The umbilicus, both nipples and the apex of the left axilla had escaped destruction. The granulating area extended to the wrist on the inner side of the left arm and to the cubital space on the right arm. There was an unhealed area five by ten centimetres on the outer aspect of the left thigh. The ears were healed. The granulations everywhere were œdematous, pale, very exuberant and infected. (Fig. 10.) There were two ulcers on the scalp over the occiput about two centimetres in diameter

FIG. 8.—(Case II continued.) Ten weeks after admission. The area is almost healed. Note the extension apparatus on the leg and the arm. The leg and thigh are completely extended. The contraction in the axilla has been minimized.

which extended down to the periosteum and there was marked œdema of the surrounding scalp. The rectal temperature on admission was 102°. *Urinalysis* showed a faint trace of albumen, positive acetone and a few granular casts. *Blood Examination.*—Red cells, 3,960,000; white cells, 11,000; hæmoglobin, 61 per cent. The grouping was IV. The Wassermann reaction was negative. The physical examination otherwise was unimportant.

Progress in Hospital.—She was placed in bed upon sterile sheets under a tent heated to 99° Farhenheit with electric bulbs. Extension apparatus was applied to the left leg and arm. Sandbags were placed under the shoulders to extend the neck but these were only partly effective because of the very painful rapidly spreading ulcers in the scalp which had been caused by pressure. The œdema became worse and the attempts at extension of the neck had to be given up. In four days the urine was negative. She was extremely nervous and very difficult to handle and the granulations responded very slowly to treatment. In ten days the ulcers in the scalp began to improve and the extension of the neck was again started. Albumen and pus-cells appeared in the urine and the temperature rose as high as 102° daily. Râles developed in the lungs and the hæmoglobin fell to 50 per cent. A transfusion of 100 cubic centi-

metres of whole citrated blood was given under nitrous oxide and oxygen anæsthesia. The general condition began to improve again and by the end of November the hæmoglobin was 70 per cent. In spite of every effort the patient continued extremely nervous, so that all the treatment was carried out with great difficulty. (Fig. 11.) On December 2, under nitrous oxide and oxygen anæsthesia, small deep grafts were taken from the thigh and scattered over the chest, arms and the abdominal wall and Ollier-Thiersch grafts were placed on the neck after the adhesions had been divided, the granulations removed and neck extended. The Ollier-Thiersch grafts were only partially successful. The small deep grafts took nicely and two weeks later other small deep grafts were taken from the thigh, under avertin supplemented by nitrous oxide and oxygen anæsthesia, and were placed in the intervals between the small deep grafts previously applied. Improvement was rapid until December 22 when albumen and pus-cells again appeared in the urine and the temperature remained high. This continued for a month despite treatment and the hæmoglobin fell to 55 per cent. A transfusion of 210 cubic centimetres of whole citrated blood was given under general anæsthesia. During the following month the hæmoglobin gradually rose to 65 per cent. and the urine cleared up. February 20, under general anæsthesia, small deep grafts were taken from the thigh and placed on the few remaining small unhealed areas. These were successful. There was a recurrence of the high temperature and the urinary condition for several weeks, after which the improvement was rapid. By March the hæmoglobin was 60 per cent. and by the end of the month it was 80 per cent. The patient was permitted to sit in a chair and was discharged June 7 after a stay in the hospital of eight months. (Fig. 12.) The use of general anæsthesia of some sort was essential in this case whenever any special procedure was carried out on account of the extreme nervousness of the child.

FIG. 9.—(Case II continued.) The wound healed. Note the source of the grafts on the left thigh. Subsequently there will probably be some contraction of the scar in the groin and axilla, which will require relaxation at a later date.

This patient has since returned to the hospital for the relief of scar contractures of the neck and axilla. While at home in the interval, she has been perfectly well and has gained weight.

Analysis of Cases I, II and III.—The first three cases will be grouped as they are all children, their ages being, Case I, eleven; Case II, three; Case III, four years.

They had all been burned with fire respectively one year, seven months and two months before admission. One had had hospital and home treatment and the two others home treatment. All of this group of children were highly nervous, had learned to dread the dressings and it was very difficult

to gain their confidence. All were emaciated, anæmic and in very poor general condition.

FIG. 10.—(Case III.) Condition on admission two months after the burn. There was a granulating area extending from the chin to the lower third of the abdominal wall. The right axilla was not involved. The apex of the left axilla was intact. The anterior axillary fold on the left side was covered with granulations. The left arm had been burned to the wrist and the right arm to the elbow. There was an unhealed area involving the outer aspect of the left thigh. The left leg was held flexed at right angles.

Apparent intense pain was present in all these cases. The hæmoglobin was 48 per cent., 45 per cent. and 61 per cent. respectively on admission.

FIG. 11.

FIG. 12.

FIG. 11.—(Case III continued.) Six weeks after admission. The granulations are firm and red. The right arm is healed. Much progress has been made in healing. There is already some contracture of the neck. Note the growth of epithelium from the nipples and the umbilicus, which were not destroyed. Because of the ulcers on the back of the head and on account of the general bad condition of the patient, the neck and arm could not be kept extended sufficiently to combat the scar contraction.

FIG. 12.—(Case III continued.) Condition at time of discharge. Note the contracture of the neck and some contracture of the left anterior axillary fold. The individual small deep grafts can be seen on the trunk. The healing is stable and the scar is soft. The patient was sent home for several months of massage and passive motion in order to prepare for subsequent plastic work on the neck and axilla.

All were in blood group No. IV. The Wassermann reaction was negative in all. The granulations were badly infected in all and varied from sluggish to exuberance in each case.

Marked scar contraction was already present in the eleven-year-old and three-year-old patients, who had been burned respectively one year and seven months before admission, and was well started in the four-year-old girl, who had been burned only two months before admission. Every effort was made in each case by means of extension apparatus and posture to prevent further contraction and to overcome that which had already taken place.

All of these patients were transfused, Case I, three times; Case II, once and Case III, twice.

All were grafted with small deep grafts, Case I, five times; Case II,

FIG. 13A. FIG. 13B.

FIGS. 13A and B.—(Case IV.) Condition on admission three and one-half months after the burn. The head was almost completely denuded of skin. There is marked ectropion of both eyelids of both eyes. The granulations were pale, exuberant, very œdematous and infected. The patient's general condition was extremely poor. The entire unhealed area was exquisitely sensitive.

three times and Case III, three times; in addition, Ollier-Thiersch grafts were placed on the neck of Case III with only partial success.

In all of these cases, the main lesions were on the trunk and extremities. In only one case, III, was the neck involved. The hospitalization necessary was in Case I, one hundred seventy-two days; Case II, sixty-four days; and Case III, two hundred forty-five days.

In Case III the course of the treatment was interrupted by a number of attacks of pyelitis with high temperature and other disturbing symptoms such as extreme mental instability and nervousness. After the treatment was well started steady general improvement was noted in all. Our object in all of

these cases was to heal the lesions; to combat scar contractions as far as were able, then to send the patient home for massage and general building up. It was necessary for each one of them to return subsequently for the relief of scar contractions. It is probable that these contractions were considerably more marked than they would have been had we had control of the treatment from the beginning, but the situation, extent and depth of these burns and the condition of the patients would have made it very difficult for us to prevent contractions even had every precaution been taken early. In other words, scar contractions following deep burns may be impossible to prevent.

FIG. 14.—(Case IV continued.) Condition at time of discharge. The head is quite well healed but the skin is not very firm. Taking into consideration the condition at time of admission much progress had been made, but still much remained to be done. Small deep grafts were used on this case in order to cover the wound with skin so that future work could be done. From the standpoint of appearance, this was not the type of graft to use, but it was the only type which had the slightest chance of taking in this case.

GROUP II.—CASE IV.—A white male, aged forty-three years, was admitted to the Union Memorial Hospital April 1, 1928. In December, 1927, three and one-half months before admission, in a gasoline explosion, he was severely burned on the head, face, chest, upper extremities and the right leg. He was treated at home by a physician, during which time the hands healed. His general condition had become steadily worse and he came to Baltimore for treatment. The skull was denuded of skin excepting for a small patch over the left parietal region and the unhealed area was exquisitely painful. There was intense photophobia. Both ears were destroyed. The tip of the nose and the alæ had been partly destroyed. There was bilateral ectropion of both eyelids with a corneal ulcer of the right eye. There were extensive unhealed areas on the face and

neck. (Fig. 13. A-B.) The hands were claw-shaped and the fingers stiff and hyper-extended by contracted scar. There was a granulating area on the lateral aspect of the left calf five by seven centimetres in size in the midst of dense scar. The exudate from the granulations on the vertex and forehead ran down into the eyes and caused severe irritation. There was a general glandular enlargement. The heart and lungs were negative. *Urinalysis* was negative. *Blood Examination.*—Red cells, 4,620,000;

A

B

FIGS. 15A and B.—(Case V.) Condition of the inner and outer aspects of the left thigh and leg four months after the burn. The extremity was completely bare of skin from the groin to the ankle except for a patch on the outer side of the thigh and a patch over the tibia. There was scar contracture in the popliteal space. The granulations are of all types and had to be treated differently in different locations.

white cells, 14,000; hæmoglobin, 80 per cent. The Wassermann reaction was negative. The blood group was IV.

Progress in Hospital.—The granulations were prepared for grafting and an ophthalmologist was called to care for the eyes. Three days after admission small deep grafts were taken from the right thigh under ½ per cent. novocaine and placed upon the forehead. This was done first in order to check the exudate from running into the patient's eyes. Three days later small deep grafts were placed over the back of the head

in order to allow the head to rest on the pillow and one week later, April 16, small deep grafts were placed over the right parietal region. April 20, small deep grafts were placed over the right post-auricular region and under the chin. Five days later, the right parietal region was grafted and one week later the crown of the head. All of these graftings were done under local anæsthesia and the grafts were placed on undisturbed granulations. The hands were massaged daily. The grafts were all successful and the healing progressed satisfactorily until July 7, when a slight infection developed on the head and face in the grafted areas. The general condition improved considerably but the patient became homesick and was discharged against our advice on the 24th of July after a hospitalization of one hundred and fifteen days. At the time of discharge the head was almost healed but the eyes could not be closed on account of bilateral

Fig. 16A. Fig. 16B.

Fig. 16A and B.—(Case V continued.) Anterior and posterior views of the leg and thigh at time of discharge. Note that the contracture in the popliteal space has been overcome and that the entire area is healed except two small superficial ulcerations on the leg.

ectropion. (Fig. 14.) Further plastic work on the lids and elsewhere was indicated at some future time.

Case V.—A white male, aged twenty years, was admitted to the Union Memorial Hospital May 4, 1926. In January, 1926, four months before admission, he was severely burned on both hands and the left thigh and leg. He was treated in a local hospital, during which time the burns on the hands healed. Attempts at grafting the left leg and thigh had failed and little progress had been made in healing. The leg was still intensely painful. The patient was then referred to us for treatment. There was some scarring of both hands and the left wrist. The left leg and thigh were covered with unhealthy granulations from the groin to the ankle, except for an area over the upper thigh and a small area over the tibia just below the knee. The leg was flexed at right angles to the thigh. There was much pain. The granulations were pale, exuberant and

infected. (Fig. 15.) *Urinalysis* was negative. *Blood Examination.*—The hæmoglobin was 85 per cent. and the clotting time was three minutes.

Progress in Hospital.—An attempt to overcome the contraction was made by means of an extension apparatus. The granulations were prepared for grafting and three weeks after admission small deep grafts from the right thigh were scattered over those granulating areas which were suitable to receive them. June 4, small deep grafts were again

A

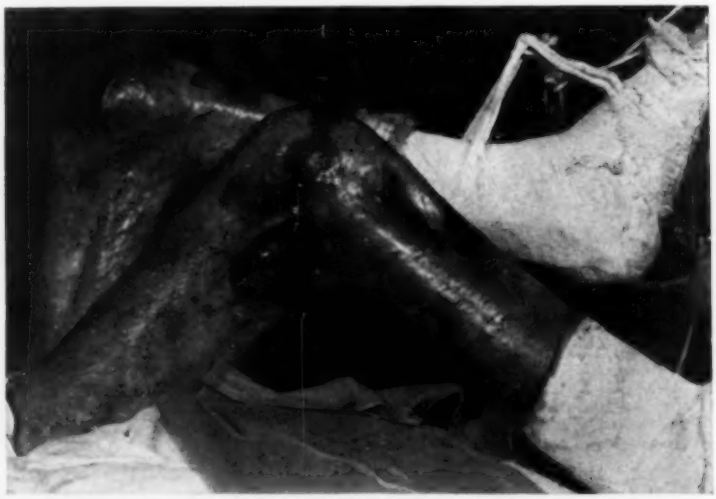

B

FIG. 17A and B.—(Case VI.) On admission two years and eight months after being burned. The deep ulcerations extended down to the femurs just above the knee joints. The hamstring muscles were below these ulcerations. The scar over both knees was ulcerated and the patellæ were immovably anchored about five centimetres below their normal positions. The legs were flexed at the knees at the angles shown and could not be moved. The plaster boots were attached to pulleys on a Balkan frame for traction.

taken from the right thigh and applied in the intervals between those first applied and on other areas now ready to be grafted. These were again successful and the anterior surface of the leg was healing rapidly. June 14, small deep grafts were placed in the popliteal space and July 12 the posterior and lateral aspects of the leg were grafted. These healed uneventfully and the patient was discharged well on August 12, after a stay in the hospital of ninety-eight days. (Fig. 16.)

Six years have elapsed since discharge and the patient has been able to continue his work and has had no further trouble.

CASE VI.—A white male, aged thirty-one years, was admitted to the Union Memorial Hospital November 13, 1931. Two years and eight months before admission, March 17, 1929, his clothes caught fire and he was severely burned on both legs and thighs. He was treated at home for one week and was then sent to a hospital where he remained for twelve weeks. At the end of that time, the legs had gradually become contracted so that the soles of the feet rested upon the bed. He was then sent home where he remained bedridden but was never completely healed. In July, 1931, deep ulcerations began to develop on both sides of both thighs just above the knees. He returned to the hospital where he remained for six weeks. Grafting was tried but was unsuccessful and amputation of both legs was advised. He refused and came to Baltimore for treatment. He was a tall, emaciated man lying upon his back with the legs flexed at the knees so that both soles rested flatly upon the bed. His general condition was very poor. In the dense contracted scar tissue, there were deep, very painful ulcerations extending down to the femurs on both sides of both thighs just above the knee-joints. These ulcerations were between the contracted hamstring muscles and bone. The patellæ were immovably anchored by deep scar about five centimetres below their normal positions. There were unhealed areas over both knees. The skin from the middle of the thighs to the calves was deeply scarred. The muscles were atrophied and "frozen" tight, and the legs were very thin. *Urinalysis* was negative. *Blood Examination.*—Hæmoglobin, 51 per cent.; clotting time, three minutes. The Wassermann reaction was negative. The blood group was IV. (Fig. 17, A-B.)

FIG. 18.—(Case VI continued.) Patient at time of discharge. Note that the contractions at the knees are almost overcome and the areas nearly healed. The deep ulcerations have filled in and the hamstring muscles are in a more normal position. The patient is able to walk with crutches. The dark spots on the skin were mercurochrome.

Progress in Hospital.—Plaster boots were made for both feet and traction applied by means of weights and pulleys on a Balkan bed. The patient was instructed to remove the weights when the pain became too severe. Massage of the healed portions of both legs and thighs was started. The ulcers were treated and improvement was gradual. Two weeks after admission the dense scars on the backs of both legs and thighs both above and below the joints were divided to relieve the tension. The tendons of the hamstrings muscles were partly cut through but not lengthened on account of neighboring infection. This was done with a cautery to prevent bleeding since the hæmoglobin was only 55 per cent. Two days later the patient developed severe pains in the right flank and a röntgenogram revealed two shadows which were diagnosed as stones in the right ureter. A transfusion of 200 cubic centimetres of whole citrated blood was given December 2 and a second transfusion was given one week later. Small deep

grafts were successfully placed on the granulations which were ready on March 14, 1932, and other similar grafts were applied to the remaining unhealed areas on March 30.

The improvement in general condition was gradual. April 20 1932, the legs are now almost straight and all the ulcers are practically healed. The right patella is now quite freely movable and the left patella is gradually loosening.

The patient is beginning to walk about the ward on crutches, and this is the first time for three years that he has been on his feet. He was discharged May 2, 1932, after one hundred sixty-eight days in the hospital. It is probable that further relaxation will eventually have to be done after function is more fully restored, but this will be comparatively simple on account of the improved condition of the tissues and improved general circulation. (Fig. 18.)

Analysis of Cases IV, V and VI.—These cases may also be grouped although their lesions were quite different. All of these were adults, their ages being, Case IV, forty-three; Case V, twenty, and Case VI, thirty-one.

Cases IV and V were burned in gasoline explosions and Case VI in an oil explosion, respectively three and one-half months, four months and thirty-two months before coming under our care.

Case IV had been treated at home, Case V in another hospital and Case VI in another hospital and at home. All of these patients suffered great pain. All were emaciated and in very poor general condition. The hæmoglobin of Case IV was high, 80 per cent., considering his general condition, as was that of Case V, 85 per cent. In Case VI, the hæmoglobin was 51 per cent. All were in blood group No. IV and in all the Wassermann reaction was negative.

The granulations varied in type from sluggish to exuberant and were infected in all. Scar contracture was marked in every case, being of a severe type in Cases IV and VI. Transfusion was done twice, Case VI. All were grafted with small deep grafts, Case IV, six times; Case V, four times and Case VI, twice.

In Case IV, the main unhealed lesions were on the head and extremities. In Cases V and VI, the lesions were on the lower extremities. The hospitalization necessary was, in Case IV, one hundred seventeen days; in Case V, ninety-eight days, and in Case VI, one hundred sixty-eight days.

In Case VI, the treatment was delayed by severe attacks of kidney pain due to stones. Steady marked improvement followed after the treatment was well started. Case IV has not returned for further treatment, although the contractures of the eyelids, *etc.*, would eventually require it. In Case V, further treatment was unnecessary. In Case VI, the patient will have to return for relaxation of the scar contractures in the popliteal space and also of the hamstring tendons.

Discussion.—By the time these patients are admitted to the hospital, their morale is usually badly shattered and every effort must be made to build this up again. Physical weakness makes them irritable and impatient, and the severe pain endured over long periods with painful dressings and the anticipation of further painful dressings is constantly on their minds. It is needless to say that extreme gentleness during dressings is essential and every effort should be made to make these dressings as free from pain as possible.

On admission all dressings were carefully removed and the patient was placed upon sterile sheets in bed and was kept warm by electrically heated and illuminated tents. This in time eliminated the fear of painful dressings, permitted the granulations to dry out and shrink, and checked some absorption from the infection, which was always present. The patients were tubbed whenever their condition was suitable. If this was not feasible, wet dressings loosely laid on saturated with either Dakin's solution; 1-5000 permanganate of potash; 1-5000 acriflavine; normal salt solution; S. T. 37; hypertonic salt solution, 5 to 15 per cent.; 20 to 40 per cent. glucose solution, *etc.*, as seemed best, were applied and changed frequently or were kept wet in order to prevent crusting.

Various antiseptics such as 5 per cent. gentian violet, 2 per cent. dahlia, 2 to 5 per cent. mercurochrome were used when needed, to overcome the infection in the granulating areas. Plain gauze, or bismuth, or iodoform gauze saturated with sterile glycerine was used, as indicated, to shrink exuberant granulations. Violet rays were also used and aided in cleaning up and shrinking the granulations where they were exuberant, and were also helpful in improving the general physical condition. All sloughing tissue, if any remained, was removed as soon as conditions were favorable. No attempts were made to trim off areas of exuberant granulations because we felt that the patients could not afford to lose any blood. Transfusions were given, whenever necessary, to raise the hæmoglobin content of the blood and to combat the infection and toxæmia, and, in many instances, this is a life-saving procedure.

The feeding of the patients was carefully supervised and every effort was made to induce them to take sufficient food of the right type. Fluids were forced to aid elimination and to replace that lost through exudation. Medication was used as indicated to allay pain, relieve nervousness, assure sleep, increase the hæmoglobin and to improve the general physical condition. Medical and pædiatric assistance in these problems was asked frequently as occasion arose.

The most skillful and faithful nursing is necessary in caring for this group of cases and much depends upon this being well done. The care of the healed areas and the unburned skin is very important as much can be accomplished by keeping these areas in good condition.

Inasmuch as all of the wounds had failed to heal under the treatment given them elsewhere and were more or less extensive, the chance of stable, unaided healing was very small. We must, therefore, weigh the different methods of hastening healing. For various reasons, the use of pedunculated flaps would, of course, be inadvisable at this period of reconstruction, so a type of free graft had to be used which could be readily secured under local anæsthesia, or very short light general anæsthesia.

The precarious condition of most of these patients contra-indicated general anæsthesia, especially since repeated grafting had to be done at short intervals.

In very nervous children such as Case III, it sometimes is necessary to use general anæsthesia even though it may be dangerous. The anæsthesia in such a case should be as short as possible and of a type which will be least likely to cause pulmonary irritation.

The larger types of grafts such as Ollier-Thiersch, half-thickness and whole-thickness grafts require a clean field for a successful take and while they can all be placed on a clean, healthy, undisturbed granulating surface and will take, this surface must be in perfect condition. These large grafts are more often placed on the raw surface left after the removal of the granulations or after excising completely the granulating area with its fibrous base. In cases of the type we are considering, we feel that the loss of blood caused by either of these operations, even though it might be small would be undesirable. In addition, the larger operative procedures necessary and the extensive areas of normal skin required to furnish these larger grafts seemed to us to be in these cases inadvisable whether under general anæsthesia or extensive infiltration. Furthermore, in some of these extensive burns, comparatively little normal skin remained which could be used as a source for the large grafts so a type of graft had to be chosen which could be secured in sufficient amounts from limited areas, especially since it was inevitable that repeated grafting would be necessary. Isografts are not sufficiently satisfactory to justify their use in these cases, particularly since there may be marked anaphylactic reaction in certain instances.

We are convinced that the most desirable type of graft to use in these cases is the "small deep graft" often referred to erroneously as the "pinch graft."* These are whole-thickness grafts in the centre tapering to the thickness of Ollier-Thiersch grafts at the edges. These grafts are sometimes confused with Reverdin grafts which consist of the epidermis with only a very thin layer of dermis. The small deep graft differs from a Reverdin graft in the same way that an Ollier-Thiersch graft differs from a whole-thickness graft. The Reverdin graft could be used in this group of cases since the source of the supply and the ability to survive are about the same as the small deep graft, but the Reverdin graft will not give as stable healing as the small deep graft because it does not contain sufficient corium to give durability to the grafted area after it is healed. The small deep grafts are not replaced by scar after healing has taken place and remain as permanently definite patches of skin. The amount of contracture in the healed area can be considerably diminished if the small deep grafts are placed fairly close

* The term *pinch graft* seems to us to be entirely out of date. At one time Reverdin grafts were obtained by pinching up a superficial bit of skin with forceps and cutting or pinching it off with scissors and on account of the method the grafts were called "pinch grafts." One frequently hears the term used also for small deep grafts, but there is no excuse for using it any longer, either for Reverdin or small deep grafts, as the use of forceps and scissors has long been abandoned by surgeons having any respect for tissues, as they cause unnecessary trauma, both in lifting and cutting the graft, and thus violate one of the fundamental surgical principles.

together. The resulting healing is very durable and can be made soft, pliable and movable by massage.

We have not attempted in these cases to bury these grafts under the granulations or use any of the other modifications sometimes suggested, because of the uniform success of the method we employ.

Large numbers of these grafts can be cut from small areas, under small amounts of local anæsthesia, so repeated grafting can be done because the amount of normal skin required to furnish these grafts need not be great. The grafts are cut about five millimetres in diameter in orderly rows leaving a small margin of skin around each graft wound to permit rapid healing in the area from which they are cut. This method conserves the normal skin to the greatest extent and permits the use of skin areas from which larger grafts or flaps could not be secured. These small deep grafts survive in the presence of some infection and can be dressed in twenty-four hours, if necessary, or be left exposed to the air if desired. They take in three or four days and grafting can be rapidly repeated to hasten healing.

As soon as the general condition of the patient was improved and the granulations were in a reasonably fair condition, grafting was commenced. It is seldom that any large granulating wound will be the same condition over its entire area at any one time, and for this reason the likelihood of successful grafting will differ in adjacent parts of the same wound. For instance, the granulations on the upper surface of a thigh may be firm, flat and clean while that on the under surface may be œdematous, infected and unfit. We therefore scattered grafts over the whole wound in suitable areas expecting a reasonable portion to take and thus secured islands of skin which stimulated the healing of the remainder. The presence of the grafts, even though they did not take, stimulated the healing and made regrafting more certain of success. In treating the cases reported, we used the small deep grafts throughout and eventually planted them at intervals of about one centimetre apart. The successive grafts were placed between those previously applied until the areas were healed.

Nature attempts to immobilize the injured parts during healing and the patient often assumes the most comfortable position, which is that of flexion, and in spite of every effort to prevent contractures by means of extension apparatus of various kinds, contractures will often occur in these cases. The extremities, even those uninjured, may be held flexed in a seriously burned case and soon because of disuse the muscles lose their tone, the tendons become shortened and the bones become atrophied. If the extremities are burned, marked deformities may be present which are caused by scar contraction.

It must be remembered that there is some contraction in every healing wound, the extent depending upon the amount of scar formation. In these extensive burns where healing had been delayed, scar formation is usually excessive and every effort must be made to minimize the amount by using

grafts which will heal the area as completely and quickly as possible and thus minimize further scar formation.

In some of these old cases, the contractures already present could not safely be overcome suddenly by force on the operating table because the blood-vessels and the nerves might be shortened and they might tear, causing gangrene and possibly a forced amputation. There was also the possibility of breaking the fragile atrophied bones. On this account an attempt was made to stretch gradually the contractures already present in the old unhealed burns by continued traction. Those which were due to posture and disuse, could be corrected by this method.

Traction was applied by means of weights and pulleys and the extremities gradually extended. The wounds were then healed with the extremities in the extended position. Massage was instituted on all healed and unburned areas and the patient was urged to move the part as much as possible.

The contractures which occurred after scar shrinkage had taken place had to be relaxed at some later date, when the patient was in better condition.

After the wounds have been healed by grafting, it is essential that the patient be sent home for six months, at least, for massage and passive motion as the scars need time for softening and releasing from deep attachments before the relaxing operations should be done. Also the patients have become, in the majority of instances, surfeited with hospital routine and need an entire change of surroundings to say nothing of a new point of view.

It was necessary for five out of six of the group of typical cases reported in this communication to return for subsequent release of scar contractures. In criticism, it might be said that the treatment used could not be particularly effective if these were the results, but when we consider that even at the late date of admission after the injury, it was frequently necessary to exert every resource at our command in order to save the lives of these patients, then an idea of the problems with which we had to deal may be appreciated.

Comments.—The condition of patients with old unhealed burns is usually very poor, both physically and mentally, and they must be thoroughly built up before skin grafting can be done successfully.

The unhealed area should be grafted as soon as the granulations are in suitable condition and healing should be induced as quickly as possible. We have found the "small deep graft" the best type to be used, as they can be obtained from comparatively small areas of skin, some of which could not be utilized to furnish larger grafts.

In these old burn cases, subsequent operative work for the release of scar contractures is almost always necessary. There has been no attempt, in this communication, to consider the methods used to obtain permanent relief of scar contractures following these old burns. Scar contraction must be combatted during treatment by suitable traction apparatus in order to minimize permanent deformity. The operative relief of scar contractures, which often occurs in most carefully treated cases, should not be attempted

for at least six months after healing is complete, which is about the time it takes for the scars to be loosened and softened by massage and passive motion.

From the ultimate results obtained in a considerable number of cases, we feel that the salvaging of these patients is well worth the time, the worry and the hospital days.

BIBLIOGRAPHY

Davis, J. S., and Kitlowski, E. A.: The Immediate Contracture of Cutaneous Grafts and Its Cause. Arch. Surg., vol. xxiii, p. 954, December, 1931.

Davis, J. S.: The Small Deep Graft. ANNALS OF SURGERY, vol. lxxxix, p. 902, June, 1929.

Davis, J. S.: The Small Deep Graft. ANNALS OF SURGERY, vol. xci, p. 633, April, 1930.

A STUDY IN EXTENSIVE CUTANEOUS BURNS*

By Monroe A. McIver, M.D.
of Cooperstown, N. Y.

This paper is based on a study of sixteen patients with extensive cutaneous burns of the body and extremities. In five instances the burns proved fatal.

General Management of Patients.—The burned areas were treated by constant applications of 5 per cent. tannic-acid solution, according to the method of Davidson,[1] until a satisfactory tan was attained. The body heat was in most instances maintained by the use of electric lights under a cradle; on one occasion, where a number of burn cases were admitted at one time following an explosion in an oil refinery, the temperature of the whole room was raised and maintained at a suitable level. Fluids were forced, being administered by mouth, by rectum and in the more serious cases by either subcutaneous or intravenous injection of normal saline solution or of a 5 or 10 per cent. solution of glucose in distilled water. Morphine was administered in doses sufficient to control pain.

Types of Studies Carried Out.—In addition to making the usual records of temperature, pulse and respiration rates, daily blood counts were made and the sedimentation rate and hematocrit recorded. Frequent estimations were also made of the plasma chlorides, non-protein nitrogen, blood sugar and plasma proteins. In certain instances isolated measurements were made of the carbon-dioxide combining power and the calcium and phosphate content of the plasma. The total intake of fluid was measured and the output of urine recorded. In addition to the "routine clinical" examination of the urine, estimations of the chloride content were carried out in a number of instances. Since the fluid that accumulates in large superficial blisters may be considered typical of the fluid lost from the vascular system in burns, this was in one instance aspirated and analyzed.

Blood Counts.—The results of the count of the white and the red blood-cells are shown in Tables I and II. In most instances the initial white count was made within a few hours after the burn occurred. The findings as noted below in general confirm the early studies of Locke.[2]

White Blood-cells.—As will be noted from Table I, elevation of the white count is a constant finding and in the more severe cases can reach an extraordinary height within a short time. (See case No. 5.) A comparison of the counts in the fatal and the non-fatal cases shows that a high white count in general indicates a poor prognosis.

Red Blood-cells.—Locke,[2] in his early publication, called attention to

* Figures from the Surgical Services of the Massachusetts General Hospital with the coöperation of the Medical Service.

TABLE I. *White Blood Count*

CASE NO.		DAY OF ILLNESS								
		1st	2nd	3rd	4th	5th	6th	7th	8th	9th
FATAL	1	24,000	20,000	13,800	10,000	8,600	13,480	23,600	26,000	23,000
	2	37,000	Died a	few hours	after	admission				
	3	35,000	56,000							
	4	23,000	25,000	21,000	11,000	5,000				
	5	70,000	Died a	few hours	after	admission				
	6	17,000	17,000	29,000	30,000	26,000	26,000	24,000	19,000	
	7			21,000						
	8	19,000	20,000	31,000						
	9	14,000	11,000	10,000	15,000	15,000	14,000			
	10									
	11	17,000	7,000	11,000	11,000	11,000				
	12			1,000						
	13	15,000	16,000	24,000	19,000	17,000	16,000			
	14	12,000		7,000	8,000	11,000				
	15		17,000	13,000	14,000				13,000	
	16	22,000					18,000			

TABLE II. *Red Blood Count*

CASE NO.		DAY OF ILLNESS								
		1st	2nd	3rd	4th	5th	6th	7th	8th	9th
FATAL	1		7,1	6,9	4,9	6,2		6,0	6,3	6,0
	2	Died	a few	hours	after	admission				
	3		7,1							
	4			5,2	5,3	5,5				
	5	Died	a few	hours	after	admission				
	6		5,6	5,8	5,6	5,4	5,9	4,9	5,2	
	7			5,2						
	8	5,8								
	9		5,2	5,2	4,3	5,8	5,7			
	10	4,0	4,0							
	11		5,2	4,7	4,5	4,6				
	12		5,4	5,7	5,9					
	13		5,0	5,2	5,3	6,2	5,0			
	14		4,9	4,9	4,0	4,7				
	15			5,5						
	16	5,3					4,9			

*7,100,000; zeros omitted throughout.

the great increase in red cells that frequently occurs in cases of severe burns; one case in his series showed a count of over nine million. This author correctly interpreted this finding as a relative increase due to concentration of the blood.

In most instances of the present series, red counts were unfortunately not made on the first day of the illness. In several cases, however, a decidedly high count was found on the second day. In a few cases estimations of the red cells in both capillary and venous blood were carried out and in most instances it was found that the capillary count was definitely higher than the venous count, indicating stasis of the blood-cells in the superficial capillary bed.

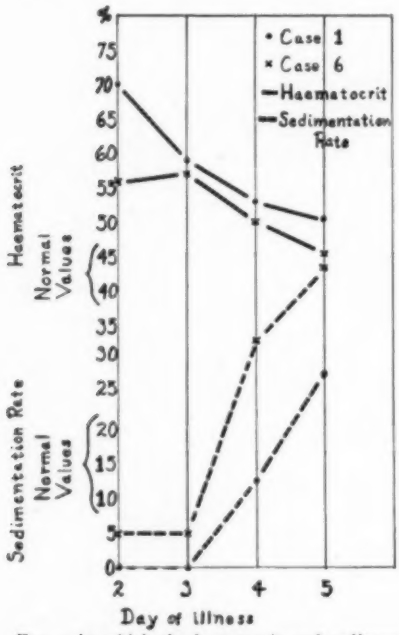

FIG. 1 in which the hematocrit and sedimentation rates on two cases over a period of five days are plotted; data from Table III. It will be noticed that on the second day of the illness there was a marked concentration of the blood, as shown by the hematocrit. In Case I the red cells constituted 70 per cent. of the total sample of blood. The rate of sedimentation was markedly slow in both patients. After vigorous administration of fluids the hematocrit readings were lower, being essentially normal by the fifth day. During this period there was an increase above normal in the sedimentation rate.

Hematocrit Readings and Sedimentation Rate.—The hematocrit readings and the sedimentation rates* are shown in Table III. The findings in two typical cases are also shown graphically in Fig. 1; one of these patients (Case I) died; the other (Case VI) recovered.

It will be noted that the characteristic findings were, in general, an increase in the percentage of red cells and a slowing of the sedimentation rate. The increased percentage of red cells is due to concentration of the blood and is roughly parallel to the severity and extent of the burn: in one fatal case (No. 1) the red cells constituted 70 per cent. of the total sample of blood, and it will be observed that some concentration persisted for as long as three days in spite of vigorous forcing of fluids. The delay in sedimentation rate is also due in part to concentration of the blood. This alone, however, is not sufficient to explain the picture, for in several cases—notably Cases IX and X (see Table III)—marked slowing of the sedimentation rate occurred in spite of the fact that the concentration of the blood was little or not at all changed. It will be observed that after the first few days the sedimentation rate usually rose to normal or above normal levels. In certain

* The blood was drawn into glass tubes graduated from 1 to 100 mm., as described by Plass and O'Rourke.[3] The sedimentation rates were read at the expiration of one hour. The tubes were then placed in a centrifuge and centrifuged at high speed for twenty minutes; at the end of that time the percentage of red cells was read.

of the cases this may have been due to a certain degree of infection in the burned areas.

Blood Chemistry.—Tables IV, V and VI show the estimations of plasma chlorides, non-protein nitrogen and total serum protein.

Plasma Chlorides.—A lowering of the blood chlorides following burns has been reported by Underhill[4] and Davidson.[5] * The most extensive

TABLE III

Hematocrit and Sedimentation Rates

CASE NO.		DAY OF ILLNESS																					
		1st		2nd		3rd		4th		5th		6th		7th		8th		9th		10th		11th	
		Sed.	Haem.	Sed.	Haem.	Sed.	Haem.	Sed.	Haem.	Sed.	Haem.	Sed.	Haem.	Sed.	Haem.	Sed.	Haem.	Sed.	Haem.	Sed.	Haem.	Sed.	Haem.
		MM	%	MM	%	MM	%	MM	%	MM	%	MM	%	MM	%	MM	%	MM	%	MM	%	MM	%
FATAL	1			0	70	0	59	12.5	53	28	50.5			3.5	46								
	2	Died a few hours after admission																					
	3			2	44	0	47																
	4	0	61	0	60	1	49	9	41														
	5	Died a few hours after admission																					
6				3	56	3	57	33	50	43.5	45.5												
7						31	46.5																
8			36		28						55				55								
9		2	53	12	50			40	44.5														
10		2	46	10	48	30	48	40.5	44						43		44						
11				8	44	11	46		42.5	12													
12		22	52	42	52		50	38	52	34	46							42	50			42	52
13		4	52	10	54	24	52																
14					40	7	45			9.5	41.5												
15						40	60						74			71							
16		4	54	8	46							43.5	44										

Sedimentation rate one hour; hematocrit percentage ratio of red blood cells to plasma

studies on this point were carried out by the latter author, who followed the chloride metabolism in thirty-one patients with cutaneous burns. He found in the early stages of the illness, in the more severely burned patients, an appreciable lowering of the plasma chlorides and whole blood chlorides, and also a diminished excretion of chlorides in the urine. In at least one of Davidson's patients whose record is shown in detail the chloride intake was low while the amount of ingested fluid was high. Later in the disease,

* Davidson made measurements of both the whole blood and the plasma chlorides. Underhill's, *et al.*, figures were for whole blood chlorides.

according to this author, when the slough began to separate, there occurred an elevation of the plasma chlorides and an increased output of chlorides in the urine.

The changes in the values of the plasma chlorides are probably related to the disturbance of the water balance in the three types of body fluids—the circulating, interstitial and intracellular fluids. The observations on the plasma chlorides in the present series are presented in Table IV. It will

TABLE IV

Plasma Chlorides

(Mgs. per 100 cc.)

CASE NO.		DAY OF ILLNESS														
		1st	2nd	3rd	4th	5th	6th	7th	8th	9th	10th	11th	12th	13th	14th	15th
FATAL	1	595	601	576		562		587				540				
	2	Died a few hours after admission														
	3	632														
	4	551	640			678										
	5	Died a few hours after admission														
	6	589	586	548		541										
	7			548		584										
	8	615	584					574		572					592	
	9	586	577	530		541										
	10	590			586	609										
	11	584	577	589		595										
	12	578	549	590			568		548	559		569		609		582
	13	589	566	573		562										
	14	578	607	582		620										
	15		572				552									
	16	544	563				584									

be noted that the values are in general normal, although in several instances they are in the lower normal range. In one of the fatal cases (No. 4) the values were above normal; this patient was treated with large volumes of normal saline solution, but in spite of the larger intake of fluids and chlorides (see Table VIII) and the high plasma chlorides, the output of urine was small and its chloride content low.

Non-protein Nitrogen.—Elevation of the non-protein nitrogen of the blood following burns has been reported by Davidson[1,5] and also by Beck and Powers.[6] In one of the cases reported by these latter authors the blood urea was eighty milligrams per 100 cubic centimetres on the third

day; in another instance a reading of seventy milligrams was found on the first day.

The results of the measurements of the non-protein nitrogen in the present series are shown in Table V. Case I showed a reading of fifty-nine milligrams per 100 cubic centimetres on the second day, sixty-five milligrams per 100 cubic centimetres on the seventh day and 130 milligrams per 100 cubic centimetres on the eleventh and twelfth days. Another of the fatal

TABLE V

Non-protein Nitrogen, Blood
(Mgs. per 100 cc.)

CASE NO.		DAY OF ILLNESS														
		1st	2nd	3rd	4th	5th	6th	7th	8th	9th	10th	11th	12th	13th	14th	15th
FATAL	1	38	59	26	42	35		65				130	130			
	2	45	Died a few hours after admission													
	3	45	31													
	4	34	35		66	140										
	5	Died a few hours after admission														
6				38	33	30		30								
7				47		25										
8																
9		37	31	32		30										
10		29		31	28											
11		30	23	22		24										
12		32					32		37			30				32
13		27	27	22		23										
14		23	26	23		31										
15			36				34									
16			36				25									

cases (No. 4) also showed a marked elevation on the fourth and fifth days; in this latter case it will be noted (Table VIII) that there was a marked suppression of urine throughout the illness. Cases II and III showed a reading of forty-five milligrams on the first day. With these exceptions normal readings were obtained throughout the series.

Serum Protein.—The measurements of total serum protein are shown in Table VI. It will be noted that several of the cases—notably Cases I, IV and VIII—showed some lowering of the total serum protein. These measurements were made at a time when some concentration of the blood existed. (Table III.) Davidson and Matthews[7] also found that the value of the plasma protein did not rise in proportion to the degree of concentration of the blood. They considered that this fact could be explained only

on the basis of altered permeability of the capillary walls, and concluded that it indicated a loss of the whole plasma rather than simply of the water content. I am in agreement with this conclusion. Davidson and Matthew further reported a characteristic rise in the fibrin and globulin of the plasma, while the albumin showed a fall.

Blood Sugar.—The blood sugar determinations on samples taken the first day of the illness showed, in the majority of cases, a marked increase,

TABLE VI

Serum Protein
(Expressed in Percentage)

CASE NO.		DAY OF ILLNESS							
		1st	2nd	3rd	4th	5th	6th	7th	8th
FATAL	1			4.5					
	2	Died a few hours after admission							
	3	7.3	Before Glucose 7.5 after 5.1						
	4			5.2		4.9			
	5	Died a few hours after admission							
6					6.1				
7				6.4		7.2		6.3	
8		4.	4.5						
9				6.3					
10		5.6	6.8	6.1	6.1	6.		6.1	
11									
12		6.6		6.5			6.2		
13									
14									
15			7.9				6.4		
16			6.6				6.9		

rising as high as 266 milligrams in one case. This is probably comparable with the rise in blood sugar found in traumatic shock.[8] The values returned to normal within the first twenty-four or forty-eight hours. In some of the less severely burned patients there was no rise.

Carbon-dioxide Combining Power.—Measurements of the carbon-dioxide combining power when taken within the first twenty-four or forty-eight hours showed essentially normal values. Patients Nos. 4 and 8 later developed a definite acidosis, Patient No. 4 on the fifth and last day of his illness having a carbon-dioxide combining power of 28.2 volumes per cent.

Case I showed a carbon-dioxide combining power of forty-seven volumes per cent. on the second day, which fell to 38.6 volumes per cent. by the seventh day and to 24.3 volumes per cent. by the eleventh day.

Blood Calcium and Phosphates.—Isolated measurements were made of the blood calcium and phosphate. Essentially normal values were obtained, except in the case of Patient No. 4, who on the fifth day showed a blood calcium of six milligrams per 100 cubic centimetres, with a serum phosphate of 7.1 milligrams.

Blister Fluid.—It is well known that in cutaneous burns there is great leakage of fluid from the burned area and frequently a large accumulation of fluid in superficial blebs. It was felt that the fluid that gathers in such blebs might be considered typical of the fluid lost in cutaneous burns. Patient No. 8 developed large blebs over the burned area on the leg, and some ten or fifteen cubic centimetres of this fluid were aspirated under aseptic conditions and analyzed. The results of the analysis are shown in Table VII. It will be noted that the chlorides showed essentially the values of normal blood; the sugar was somewhat low; the non-protein nitrogen normal; the calcium somewhat higher than the normal range for blood. The total protein was 3.7; this figure is lower than the normal values for total serum protein, but it is evident that protein is lost in appreciable amounts.

TABLE VII

Blister Fluid, Patient No. 8

Chlorides	591 mg/100 cc.
Sugar	87 mg/100 cc.
N. P. N.	27.5 mg/100 cc.
Calcium	15.3 mg/100 cc.
Total Protein	3.7%
White Blood-cells	2,400 cells

On the basis of this analysis of the blister fluid it is evident that the loss of fluid is not simply a loss of the water content of the blood, but of a substance that is closely parallel to whole plasma. *One would not, therefore, expect great changes in the individual constituents of the plasma, following burns, but rather a lowering of the total volume of plasma with a resulting concentration of the blood.*

Intake and Output of Fluids: Urinary Findings.—The intake and output of fluids during the first five days of the illness, and in certain cases the total output of chloride in the urine, are shown in Table VIII.* The fluid taken in the fatally burned cases was largely in the form of physiological

* These records were kept for twelve days, but no striking changes were found between the fifth and twelfth days, intake and output of fluids maintaining about the same rates. Case I was an exception: after the fifth day there was an increase in the excretion of fluid and chloride for several days, followed by a marked diminution in the excretion during the last few days before death, which occurred on the eleventh day.

salt solution given intravenously or subcutaneously; in certain instances 5 to 10 per cent. glucose solution was used.

The diminished output of urine and the low excretion of chlorides in spite of the large intake of fluid were striking findings in all the fatal cases. In the less severely burned cases, also, there was some suppression of urine and a low excretion of chlorides. This diminished kidney function is an important finding, and may be of fundamental significance.

Davidson[5] has suggested that the urine chlorides are low because the blood chlorides are below the renal threshold; this may hold true in certain instances, but obviously cannot explain the low excretion of chlorides in Case IV. Davidson, whose cases were kept on a fixed sodium chloride intake, noted an increased output of the chloride of the urine at about the time the slough separated. The cases in the present report were not studied long enough to detect this late rise in chloride excretion. Several of the cases, because of the high fluid intake and low urinary secretion, developed œdema of the feet and ankles and dependent parts.

Routine clinical examination of the urine carried out in most of the cases showed the "slightest possible trace" of albumin. In one case (IV) this was recorded as "a trace" on the fifth day of the illness. A number of the fatal cases showed rare granular casts with an occasional white blood-cell. Cases I and IV in the terminal stage showed acetone and diacetic acid.

The Cause of Death.—It is not the purpose of this paper to review the enormous literature on the toxæmia of burns; reference to this will be found in the works of Pack[9] and Pack and Davis.[10] There are at the present time two principal theories as to the cause of death in extensive burns. One of the oldest and most firmly established in the literature is that the symptoms and death are due to a toxin absorbed from the devitalized or partially devitalized burned tissue. More recently, Underhill and co-workers[4,11,12,13,14] have contended that the symptoms are due not to a circulating toxin but to the marked concentration of the blood. These authors point out that the highly concentrated blood has difficulty in passing through the capillaries; circulation is slow and aëration of the tissues deficient; the large blood-vessels are not properly filled and the heart has not sufficient blood to work upon. In consequence of the partial asphyxiation of the tissues there may be alterations in the metabolic process and disturbance of the heat-regulating mechanism and kidney function.

The fact that great concentration of the blood occurs in extensive superficial burns is beyond question (in the present series the volume of red cells, as indicated by the hematocrit, reached a figure as high as 70 per cent.; see Table III) and undoubtedly the secondary effects of this condition are profound. In spite, however, of the evidence brought forward by Underhill in support of the view that concentration of the blood is responsible for the death, it seems questionable whether this is the whole story. As shown in Tables III and VIII, a number of fatalities occurred in the present series, although the concentration of the blood was combated with large intakes

TABLE VIII

CASE NO	1st Day			2nd Day			3rd Day			4th Day			5th Day		
	CC. FLUID INTAKE	CC. URINE OUTPUT	GMS. URINE Cl'	CC. FLUID INTAKE	CC. URINE OUTPUT	GMS. URINE Cl'	CC. FLUID INTAKE	CC. URINE OUTPUT	GMS. URINE Cl'	CC. FLUID INTAKE	CC. URINE OUTPUT	GMS. URINE Cl'	CC. FLUID INTAKE	CC. URINE OUTPUT	GMS. URINE Cl'
FATAL 1.	1860	750		6420	1350		6990	1440	3.8	7740	2550	5.7	6180	4500	3.4
FATAL 2.	4800	0	0	Died a few hours after admission											
FATAL 3.	3230	120	0	4390	120	0									
FATAL 4.	1800	0	0	7650	450		6750	540	.2	4770	495	.3	3480	660	1.6
FATAL 5.	1000	0	0	Died a few hours after admission											
6.	2250			4860	180		7290	1080	1.8	6120	1410	1.1	5670	1230	1.4
7.							6800	1535		4280	1410	2.7	4280	630	2.5
8.	1800	900	7.9	5100	1635	5.8	6300	5200	6.1	7950	6300	3.8	6900	2980	3.2
9.	2310	510		3360	450		4800	1320		4440	960		5100	1440	
10.		820	2.4		3040	3.6		2620	1.6		1570	1.1		1120	
11.	3450	1470		3750	2550		9300	2550		6540	2670		6000	3000	
12.										1200	2400	0	3300	2350	1.8
13.	3810			5400	2550		8040	4470		6270	2040		6990	4410	
14.				2250	600		5100	1140		6510	2490		5250	840	
15.				7140			5250			5250	1800		7150	1350	
16.	5120	395	1.5	4480	1446		5760	1230	2	4800	1600		4160	730	0.9

of normal salt solution. It may be argued that in several of these cases death occurred after the acute stage had passed and may have been due to infection of the burn. This is possible in certain cases, especially in Patient No. 1, who survived eleven days; in other cases, however, it would not seem likely. All the patients were treated under as strictly aseptic conditions as possible.

Certain pathological lesions sometimes found in burn cases at autopsy have been brought forward as evidence of a circulating toxin; these are notably duodenal ulcers[15,16,17] and hæmorrhages into the adrenals,[16,18] although other lesions have also been reported—as, for example, cloudy swelling of the kidney and degenerative changes in the liver and central nervous system.[10] Underhill[12] explains these findings on the basis of the fact that as the body is burned the heat may penetrate the body cavities deeply enough to bring about local circulatory changes of sufficient severity to cause the ulcers and hæmorrhages. This explanation seems to the author unsatisfactory; it does not seem reasonable that the heat could penetrate sufficiently to account for lesions of such deep-seated organs as the duodenum and adrenals. In Harris's case, referred to above,[16] the burns were caused by boiling water, so that the surface temperature could not have been above 100° C.

In the case of a death occurring within a few hours after an extensive body burn, it seems probable that the cause is comparable to that in primary wound shock.[19] The cause of death in patients who survive the effects of the preliminary shock and die later seems to the author still an open question.

Although it may not be the only factor in the cause of death, or at times even the principal factor, the importance of the concentration of the blood cannot be minimized. There is some question, however, as to whether this condition comes about simply as a result of local loss of blood plasma in the burned area, or whether there is a general lowering of capillary permeability all over the body. Underhill[14] believes the loss a local one; Beard and Blalock[20] also agree that the local loss of plasma is sufficient to explain the symptoms. Davidson[7] (who believes in a circulating toxin) considers that there is a general lowering of capillary permeability throughout the body. The observations made on the patients of the present series do not include any measurements that would be applicable to this point. The amount of subcutaneous œdema and swelling of a seriously burned extremity is striking and the local loss of fluid is obviously considerable; two of the patients in this series also developed some generalized œdema of the dependent parts, but this was not surprising in view of the large amounts of fluid they were receiving and the low renal output.

Treatment.—The general points in treatment have been touched on under General Management of Patients. Since concentration of the blood and lowering of the total blood volume is undoubtedly a serious condition in itself, the volume of fluid administered must be adequate to correct the condition, the amount varying with the age of the patient and the severity

of the burn. In the case of children, where the blood volume is relatively small, the loss of a given amount of fluid is felt proportionately more. It is necessary that the administration of fluid be kept up for a number of days. It should be remembered that where large volumes of fluid are required it might be well, for at least part of the quantity given, to use isotonic glucose solution rather than physiological salt solution, so that an undue amount of sodium chloride will not be taken in. In many of the fatal cases (see Table VIII) the output of sodium chloride is low in spite of the fact that the blood chlorides are normal or even slightly above normal.

SUMMARY.—The findings may be summarized as follows:

There was an increase in the white and red blood counts, an increase in the percentage of red cells in proportion to plasma, a diminution in the sedimentation rate of the red cells. Blood-chloride values were in essentially normal range (the serious cases received large volumes of normal salt solution). Only two cases showed very striking increase in the non-protein nitrogen of the blood; these two were fatal cases and the increase was most marked in the terminal stage. Certain cases showed some lowering of the total plasma protein. When the blood sugar was determined soon after the burns occurred, it was in the most cases high. Carbon-dioxide values were essentially normal early in the disease; two patients later developed a definite acidosis.

The composition of the blister fluid closely resembled that of blood plasma.

The urinary output was low and the excretion of the chlorides diminished; this was most marked in the more severely burned cases.

CONCLUSIONS.—One of the most outstanding findings in severe burns is the marked concentration of the blood. Correction of this abnormal condition by adequate fluid intake, while important, is frequently not able to relieve all the symptoms or prevent a fatal outcome; it seems likely that there is some other important factor in the toxæmia of burns.

BIBLIOGRAPHY

[1] Davidson, E. C.: Tannic Acid in the Treatment of Burns. Surg., Gynec., and Obst., vol. xli, pp. 202–221, August, 1925.

[2] Locke, E. A.: A Report of the Blood Examination in Ten Cases of Severe Burns of the Skin. Boston Med. and Surg. Jour., vol. cxlvii, pp. 480–484, October 30, 1902.

[3] Plass, E. D., and Rourke, M. D.: A New Procedure for Determining Blood Sedimentation Rates. Jour. Clin. Inves., vol. v, pp. 531–539, June, 1928.

[4] Underhill, F. P., Carrington, G. L., Kapsinow, R., and Pack, G. T.: Blood Concentration Changes in Extensive Superficial Burns, and Their Significance for Systemic Treatment. Arch. Int. Med., vol. xxxii, pp. 31–49, July, 1923.

[5] Davidson, E. C.: Sodium Chloride Metabolism in Cutaneous Burns and Its Possible Significance for a Rational Therapy. Arch. Surg., vol. xiii, pp. 262–277, August, 1926.

[6] Beck, C. S., and Powers, J. H.: Burns Treated by Tannic Acid. ANNALS OF SURGERY, vol. lxxxiv, pp. 19–36, July, 1926.

[7] Davidson, E. C., and Matthew, C. W.: Plasma Proteins in Cutaneous Burns. Arch. Surg., vol. xv, pp. 265–274, August, 1927.

[8] Cannon, W. B.: Traumatic Shock. D. Appleton & Co., p. 86, New York, 1923.

[9] Pack, G. T.: Pathology of Burns. Arch. Path. and Lab. Med., vol. i, pp. 767–805, May, 1926.

[10] Pack, G. T., and Davis, A. H.: Burns. J. B. Lippincott Company, Philadelphia, 1930.

[11] Underhill, F. P.: Changes in Blood Concentration with Special Reference to the Treatment of Extensive Superficial Burns. ANNALS OF SURGERY, vol. lxxxvi, pp. 840–849, December, 1927.

[12] Underhill, F. P.: The Significance of Anhydremia in Extensive Superficial Burns. Jour. Am. Med. Assn., vol. xcv, pp. 852–857, September 20, 1930.

[13] Underhill, F. P., Kapsinow, R., and Fisk, M. E.: Studies on the Mechanism of Water Exchange in the Animal Organism; (1) The Nature and Effects of Superficial Burns. Am. Jour. Physiol., vol. xcv, pp. 302–314, November, 1930.

[14] Underhill, F. P., and Kapsinow, R.: Alleged Toxin of Burned Skin. Jour. Lab. and Clin. Med., vol. xvi, pp. 823–830, April, 1931.

[15] Curling, T. B.: Acute Ulceration of the Duodenum in Cases of Burn. Med.-Chir. Trans., vol. xxv, p. 260, London, 1842.

[16] Harris, R. I.: Fatal Burn; Death Due to Hæmorrhage into Suprarenal Capsule and to Hæmorrhage from Duodenal Ulcer. Brit. Jour. Surg., vol. xvi, pp. 677–680, April, 1929.

[17] Levin, J. J.: Duodenal Ulcers Following Burns; with Report of Two Cases. Brit. Jour. Surg., vol. xvii, pp. 110–113, July, 1929.

[18] Weiskotten, H. G.: Fatal Superficial Burns and the Suprarenals; Note on Occurrence of Suprarenal Lesions in Uncomplicated Fatal Cases of Extensive Superficial Burns. Jour. Am. Med. Assn., vol. lxix, p. 776, September 8, 1917.

[19] Cannon, W. B.: Traumatic Shock. D. Appleton & Co., p. 4, New York, 1923.

[20] Beard, J. W., and Blalock, A.: Experimental Shock; Composition of Fluid that Escapes from the Blood Stream after Mild Trauma to an Extremity, after Trauma to the Intestines and after Burns. Arch. Surg., vol. xxii, pp. 617–625, April, 1931.

ARM-CHEST ADHESIONS AND THEIR PLASTIC RECONSTRUCTION

BY THE TUBE FLAP METHOD

By Jacob Kulowski, M.D.

of Iowa City, Iowa

FROM THE DEPARTMENT OF ORTHOPEDIC SURGERY OF THE STATE UNIVERSITY OF IOWA

The object of this paper is to discuss arm-chest adhesions (brachiothoracic adhesions, axillary webs) in general, and to describe the reconstructive procedures used in a case herein reported. Axillary form and function were restored by the tube flap graft. The associated scar contractures were corrected by the Z-shift flap method.

Burns about the axilla, whether produced by the dry flame or scald, will often in the process of healing produce scarring and resultant binding of the arm to the side, thus preventing abduction at the shoulder. This complication is prone to develop in the axilla, and is definitely predicted by the normal resting arm-chest position, there being no tension stresses that would tend to minimize or prevent contraction, as in some parts of the body. However, this position is probably protective against more severe injury to the important vascular and nervous structures of the axilla. The final cicatrix will depend upon the extent, and depth of the injury, the presence or absence of infection, and the peculiarity of the tissue chemistry and physiology.

This serious disability may sometimes be avoided if preventative measures are persisted in during the period of healing, such as the continuance of full abduction at the shoulder by some form of splinting or traction, and the application of Thiersch grafts to the granulating area as soon as the bacteriology and the appearance of the wound permit.

However, prevention of deformity is not so simple a matter. The intrinsic contracture mechanism does not occur in the epithelium but in the subcutaneous connective tissues. Its exact mechanism is still undetermined. Where there is a distinct granulation tissue, the process of healing is an extremely complicated one, and there seems to be a transformation of the cells of the granulation into connective tissue. The early covering of raw surfaces with Thiersch grafts therefore acts chiefly as a protective layer which may certainly mitigate but not necessarily prevent recurrent contracture. The corollary to this is the plastic principle of excision of scar tissue wherever possible, and the restoration of the defects by the use of whole thickness type of grafts.

When the deformity is present the problem of restoring form and function is an urgent one. In no region of the body are the resultant mechanical deviations so injurious and far-reaching in their general effects from burn contracture. In no other anatomical situation is the restoration of form so

important in the realization of a good functional result. The axilla with the arm in abduction is a pyramidal space presenting a rather deep apex (armpit) and four walls. "The successful reconstruction, or readjusting of the axillary space, is the key to the relief of the condition." This normal hollow contour can be renewed only by the excision of the scar tissue and the recovery of the cutaneous surfaces by adequate normal skin.

Certain inevitable and far-reaching sequelæ of axillary burn contracture make adequate reconstruction imperative, whenever possible. The simplest of these is the inability, in some instances, to wear ordinary clothes. The bones of the shoulder girdle become atrophic and retarded from pressure of the scar and general disuse. Deformity of the ribs and limitation of thoracic excursion is present. Serious growth disturbances and scoliosis occur, particularly in children. Myogenetic and even myositic contractures may involve the axillary folds. Keloidal growths are not uncommon, and malignant degeneration has been observed.

The resultant web patterns vary from the thin lax membrane which allows considerable motion to the solid plug of scar which obliterates the axilla, and glues the arm to the chest. The thin web suggested the local shift flap methods of reconstruction about the middle of the last century.

Many local shift flap plastic reconstructive procedures have been devised with varying degrees of success in dealing with arm-chest adhesions. Several cases have been successfully treated by these procedures in this clinic. At first sight, these apparently simpler methods appear to be ideal, and certainly less laborious than the method to be outlined. Although no statistics shall be presented it may be stated that the experience of this clinic disproves this supposition. Some of these required as many as seven operations by several different procedures before the final result could be reckoned as satisfactory. It should also be remembered that most of the local shift flap technics were developed upon the observations of one or two cases. It may be axiomatically stated that there is no short road to the reconstruction of arm-chest adhesions. The greatest danger lies in trying to do too much at one sitting. The work must be done in stages.

The simplest treatment consists in division of the contracting bands, forcible, or better still gradual, abduction of the arm, and the immediate application of Thiersch grafts. This should be considered only when the web is a very thin one. "It is a good plastic principle to remove all scar tissue before attempting any sort of reconstruction." Simple division takes no cognizance of this primary principle, and recurrence is not obviated.

Other aforementioned methods employ the principle of shifting adjoining tissues after extensive undermining. Although these procedures are ingenious in their illustrative geometrically precise diagrams, they are, in actual practice, greatly limited in their execution by these definite qualifications: the thickness of the web, the firmness, depth and mobility of the scar tissue and its blood supply, and particularly the condition of the adjoining skin.

Extensive scar contractures therefore preclude such methods as those advocated by Defontaine, Piechaud, Berger, *et al.* Furthermore, extensive undermining of large flaps frequently leads to necrosis and subsequent infection which latter event may be even worse than the original condition. The tendency to maceration of the shifted flaps, even after apparent healing, has been observed in several cases treated by these technics in this clinic.

Garlock states that the free full thickness graft cannot be applicable because of the uneven contour of the axilla. The writer has had an oppor-

FIG. 1.

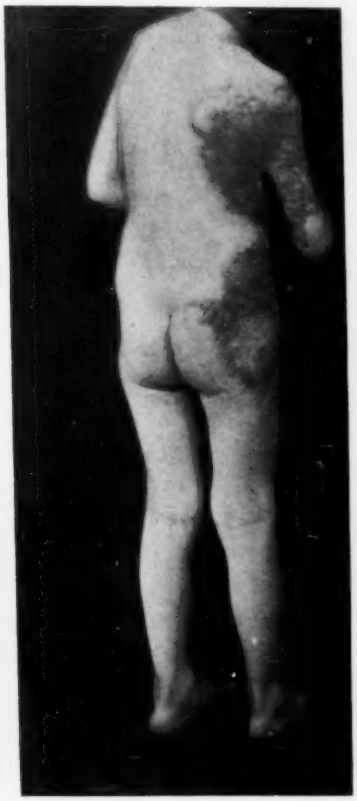

FIG. 2.

FIGS. 1 and 2.—Adhesion following burn contracture.

tunity to examine several excellent results obtained by Blair, by his split skin method, at the Shriner's Hospital in St. Louis, Missouri. This procedure merits serious consideration.

Fortunately, dermogenetic contractures yield in part to gradual correction as do many of the myogenetic variety. This preliminary conservative measure should always be instituted before any operative plans are made. This same principle applies also to the post-operative period of treatment. Steindler states that after reconstruction it is not necessary for the arm to assume the extreme position of correction at once. The tension of the new-

formed flap demands that such a position of full abduction be attained gradually and in steps. The other, most important of all, measures preliminary to operation include the building up of the general condition of the patient and the local improvement of the skin by massage.

The arm-chest adhesion reconstruction in the case to be reported was done in stages and consisted essentially of the transference of a skin flap from a distance with the maintenance of its blood supply, temporarily, through a tube flap which was in turn utilized in the reconstructive process. Although skin plastic surgery goes back to antiquity, no one seems certain who first advocated the tube flap, but Gillies, of London, is credited with its development during the war.

CASE.—The patient, Cecily Ann S., aged four years, was admitted to the hospital October 7, 1931, on account of arm-chest adhesions the result of burns sustained when clothing ignited accidentally while playing with matches in May, 1931. Was treated by the application of ointments. No splints. Healing with contracture in four months. Condition is shown in Figs. 1 and 2. Scoliosis and a moderate flexion contracture of the right hip also present. Due to skin irritation, the preliminary mechanical stretching, after admission to the hospital, had to be discontinued after one week. The steps employed for her operative reconstruction were as follows:

(1) November 19, 1931.—A single longitudinal tube flap was fashioned on the chest wall posteriorly as close to the axilla as the scar would permit (Fig. 3), which included the skin and subcutaneous tissues. The length of the tube flap is so planned by measurement that its distal end may later be transported to its final bed just under the lower border of the cicatricial web, and consist of sufficient skin to complete the restoration of the axilla. Healing was uneventful except for several temporary stitch abscesses which occurred chiefly on the chest wall.

(2) December 9, 1931.—A rectangular flap, with rounded corners, of skin and subcutaneous tissue continuous with distal pedicle was completely dissected away from the underlying fascia. This was then replaced, after careful hemostasis, and the skin edges approximated with interrupted dermal sutures. The purpose of this procedure is to permit the formation of new blood-vessels through the proximal pedicle before the complete severance of the distal end from the chest wall. (Fig. 4.) Healing was uneventful. An intercurrent respiratory infection now caused some delay in the treatment.

(3) January 8, 1932.—A portion of the scar was excised just below the web of the axilla to receive the distal end of the flap. (By leaving the web intact, at this stage, post-operative splinting is obviated.) The original temporarily raised (B) flap was now excised and transported to its position below the web. The proximal pedicle remained undisturbed. (Fig. 5.) The flap was then carefully approximated, after all dead space was obliterated by fine catgut sutures uniting the subcutaneous tissues of the flap to the chest wall.

Due to the area of the distal flap and because of retraction, a considerable defect resulted. This could not be entirely obliterated even after the employment of extensive relaxation incisions. The residual small central gap was allowed to granulate in.

Examination after five days revealed apparent necrosis of the distal half of the transported flap, although the tube itself remained normal. There was evidence of fluid accumulation under the flap and some serous discharge. This was gently drained dependently. Four days later a moderate retraction of the bed scar edges was present. But the flap itself was apparently in better condition and remained attached. Moist dressings were continued. One week later only the distal one-fourth of the flap was actually necrotic, and this was now resected. A moderate amount of drainage persisted

Fig. 3.

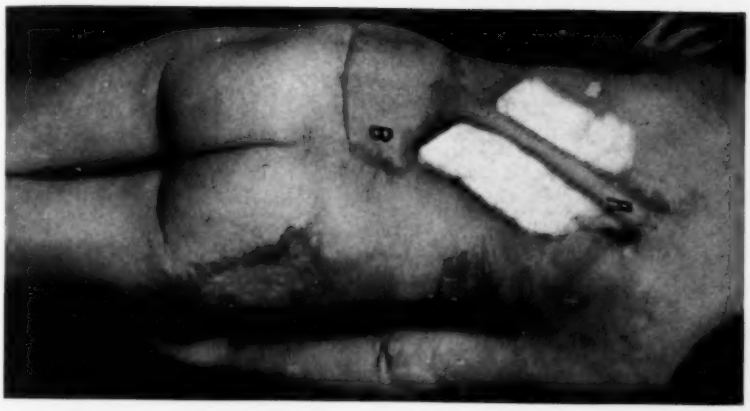

Fig. 4.

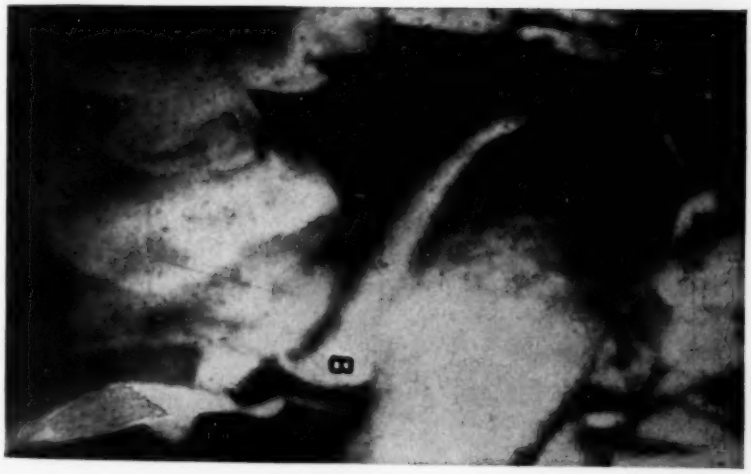

Fig. 5.

Fig. 3.—The tube flap two weeks after its preparation. It was ten inches long, and the parallel incisions of the shank were three inches apart. The pedicles were planned broader to insure a good blood supply. Moderate necrosis occurred only at the proximal axillary angle where the flap bordered the scar.

Fig. 4.—Two weeks after the temporary dissection of the distal rectangular flap.

Fig. 5.—This flap (B) has been lifted and transported to its bed just below the web.

for some length of time but finally cleared up after local and general ultra-violet irradiation.

(4) April 12, 1932.—The proximal pedicle was freed. Definite bleeding from the tube flap was noted. The tube was opened along the line of closure. There was only a moderate amount of shrinkage and fibrosis of its subcutaneous structures, and the flap was sufficient to cover the axillary defect. All the dense mass of scar tissue in the axilla and the web was excised and the arm was easily abducted to ninety degrees. The remainder of the flap was transported to the axilla. Careful hemostasis and obliteration of all dead space followed. Chromic stay sutures were taken in the subcutaneous

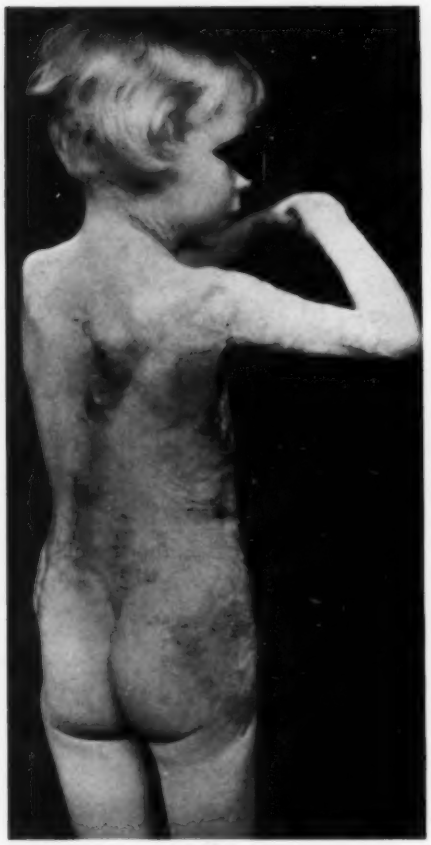

Fig. 6.

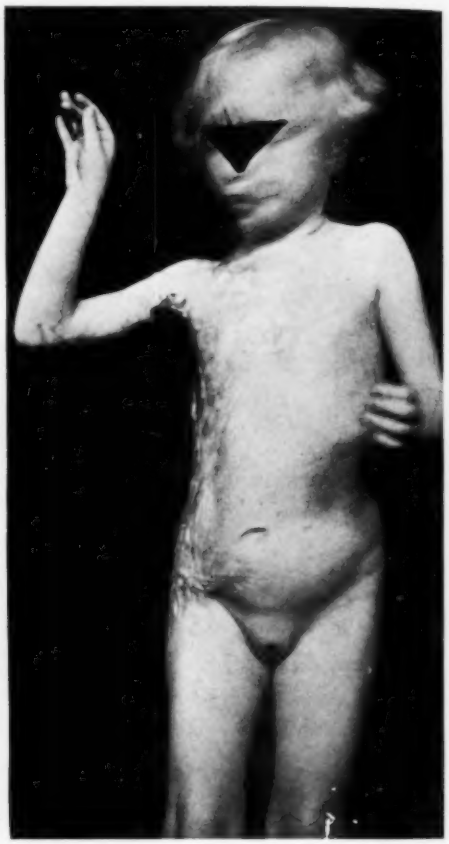

Fig. 7.

Figs. 6 and 7.—Showing amount of abduction of the arm obtained by the transplantation of the tube flap thirty-six days after the final transportation of the entire tube flap. The scoliosis has not been correctively influenced.

and deeper structures of the axillary folds to prevent subsequent retraction. The shoulder and arm were then firmly immobilized to the chest wall in about forty-five degrees abduction to prevent excessive tension upon the flap. Healing of the graft was uneventful. (Figs. 6 and 7.) After complete healing, full abduction of the arm was obtained by gradual correction with a turnbuckle abduction splint.

(5) September 6, 1932.—The scoliosis and the flexion contracture of the groin required further operative interference, and correction was accomplished by the Z-method. This technic is particularly indicated in contractures where it is impossible to resect the scar, and was first described by Denonvilliers, in 1856. (Davis.) By this method flaps of scar-infiltrated tissue are utilized. To do this some manœuvre must be carried

out which will relax the contracted band and break the line of scar tension. The transportation of flaps thus formed is made possible because there is always shortening of the tissues in the direction of the contraction and usually excess or fullness on both sides of the contracted band. It is most applicable in contractures which present a prominent bridle or web; but it can also be utilized in those contractures less commonly characterized by a groove. (Fig. 1 plainly shows a bridle in the right groin. The ridge along the right flank was utilized as a bridle in that situation.)

The technic of the incisions outlines a Z or a reverse Z, and the resultant flaps are interchanged, thus lengthening the area of the scar. The longest line of the Z is made along the prominence or in the middle of the grove, if the latter is present. The arms begin at each end of the central incision on opposite sides with their angles as seems

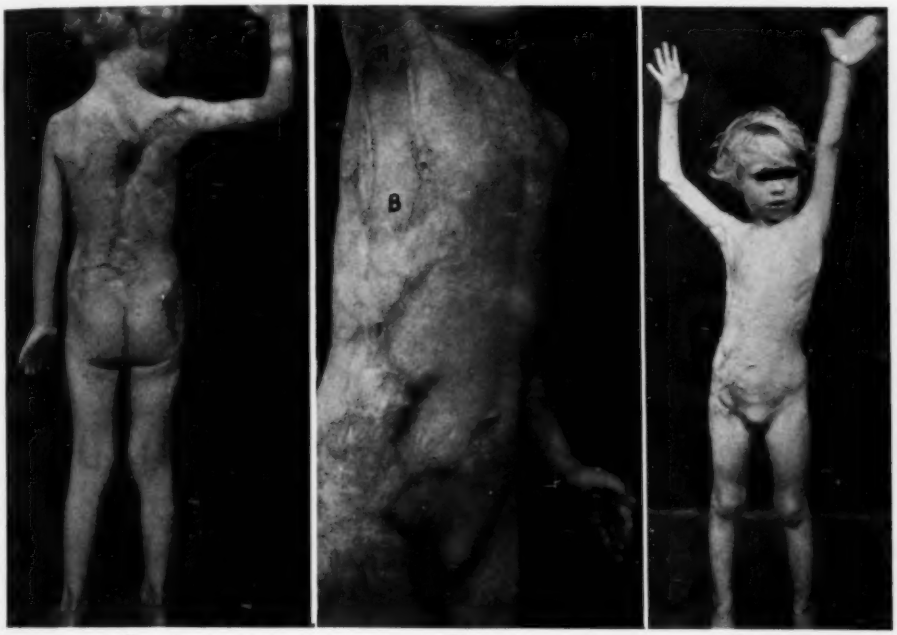

Fig. 8. Fig. 9. Fig. 10.

Figs. 8, 9 and 10.—Result six months after the complete reconstruction of the axilla, and one month after the Z-shift flap correction of the right groin and flank.

necessary. The two triangular resultant flaps are then undercut, mobilized, transported and their tips sutured into the opposite angles formed at the outer ends of the arms. The irregular wound is closed and dressed.

In this case these procedures gave excellent results. (Figs. 8, 9, and 10.) The flaps over the flank were quite extensive and permitted correction of the scoliosis immediately following the shifting of the flaps. Healing was uneventful.

Comment.—It is necessary to emphasize certain factors which have been omitted in the description of the procedure for the sake of clarity.

The operator should become familiar with the "lines of the skin" which indicate where the skin tension is greatest, and will serve as a guide to the proper placing of incisions, and their direction and extent with a view to providing minimum subsequent scarring. Due to the transverse direction of the normal skin tension field upon the back, there resulted considerable retraction of the skin edges following the formation of the tube. This gap

was approximated without undue difficulty after the establishment of liberal plastic relaxation incisions. It is evident that a transverse tube, even though it would necessitate its complete subsequent torsion, should minimize the tendency to separation. The size of the secondary distal flap should be accurately gaged, and will depend upon the mobility of the skin at the elective site. In this case considerable difficulty was experienced in attempting to close the defect following the removal and transportation of this rectangular flap, in spite of the fact that the final excision was only two-thirds of the original area mapped out.

The viability of an unusually long flap, when this is necessary, may be further insured by temporarily interrupting the parallel incisions, thus forming a somewhat linked tube. The interrupted portions may be united to form one tube after the blood supply has been established. The longevity of this primary tube is demonstrated in this case. Arm-chest adhesions require rehabilitation in several stages. One may depend upon the continuance of the flap's viability should unforeseen circumstances cause considerable delay between operative stages.

Sharp borders should be sedulously avoided in skin grafts because of their tendency to necrosis. Instead of the rectangular flap, as used in this case, it is far better to plan the so-called "frying pan" type of flap. Had this precaution been accurately observed, the disconcerting partial necrosis following the transportation of this distal flap would have been in great part minimized.

Following the excision of scar and its cutaneous surface, there is a great tendency to retraction of the defect margins which may exert harmful tension upon the graft or even spread beyond the area of the graft. The cutaneous surface over a scar area is often histologically undifferentiated from normal skin. (There is usually a loss of the papillæ elastic fibers.) It is wise in preparing a bed for the graft, in the region of the axilla, to incise (not vertically) and allow retraction of the skin border after the subcutaneous connective tissue has been excised. The more skin available the better the functional result, particularly in extensive scarring, where the formation of the tube has added to the general constriction about the chest. Excessive retraction is to be especially guarded against in the armpit proper. The skin edges must be securely stitched to the deep structures of the axillary folds with chromic sutures. Retraction will follow as a regular consequence but the normal elasticity of the graft will accommodate itself to this after healing has taken place and the graft has taken.

Injury to the important vascular and nervous structures of the axilla must be avoided in the excision of the scar plug from the armpit. The dissection will usually prove to be more extensive than is apparent at the outset. Distortion of the normal landmarks accompanies severe scar contractures in this region. Accidents may be prevented if one remembers that the vascular

sheath and its accompanying nerve trunks are on the humeral wall of the axilla.

Infection is the commonest complication of plastic surgery and one of the most dreaded. The most rigid aseptic technic must be observed, and entails a meticulous pre-operative preparation of the skin. In this clinic all plastic cases receive the same careful forty-eight-hour preparation that is routinely observed for all orthopædic conditions. Absolute hemostasis is essential before application of the graft. When infection occurs, they usually yield to mild antiseptic moist dressings, and particularly to local and general ultra-violet irradiation. The importance of building up the general condition of the patient after infection occurs was clearly demonstrated in this case by her response to general hygienic measures and blood transfusions.

All skin closures were made with interrupted dermal sutures. It is quite possible that stitch abscesses are less likely to follow the use of horse hair, but in this type of grafting the tension of the operative fields demands stronger material. Fine (00) catgut was used for the subcutaneous tissues to obliterate dead spaces, and wherever the tension indicated it.

Even-pressure vaseline gauze dressings were always applied upon the fresh post-operative fields, care being especially exercised to prevent any pressure upon the tube portion of the flap. The dressings need not be disturbed for about five days. Just as soon as the macerating effects of the vaseline are evident, dry dressings may be substituted, particularly after there is definite taking of the graft.

BIBLIOGRAPHY

Steindler, A.: A Text-book of Operative Orthopedics. D. Appleton & Co., 1925.

Idem: Reconstructive Surgery of the Upper Extremity. D. Appleton & Co., 1923.

Idem: Skin Flap Methods in the Upper Extremity. Jour. Bone and Joint Surg., vol. vii, No. 3, pp. 512–527, July, 1925.

Davis, John Staige: The Relaxation of Scar Contractures by Means of the Z, or Reversed Z-type Incision. ANNALS OF SURGERY, November, 1931.

Idem: Plastic Surgery, P. Blakiston's Son & Co., 1919.

Idem: The Principles of Plaster Surgery. Practice of Surgery, Dean Lewis, vol. v, p. 108, Ch. 8, 1930.

Idem: Arm-Chest Adhesions. Arch. Surg., vol. viii, pp. 1–23, January, 1924.

Idem: The Use of the Pedunculated Flap in Plastic Surgery. ANNALS OF SURGERY, vol. lxviii, pp. 221–230.

Blair, Vilray P.: The Use and Uses of Large Split Skin Grafts of Intermediate Thickness. Surg., Gynec., and Obst., pp. 82–97, July, 1929.

Idem: The Delayed Transfer of Long Pedicle Flaps in Plastic Surgery. Surg., Gynec., and Obst., vol. xxxiii, pp. 261–272.

Berger, P., and Bonset, S.: Traitments de deformations consecutives aux cicatrices vicieuses de l'epaule. Chir. Orthop., p. 180, Paris, 1904.

Denonvilliers: Blepharoplastie. Bull. Seco. de Chir. de Paris, vol. vii, p. 243, 1856–1857.

Piechaud, T.: Deux observations de symphyse des members a la suite de brulures etendues. Rev. d'orthop., vol. vii, p. 81, March, 1896.

Reverdin: Bull. de la Soc. de Imp. Chir., p. 493, 1869.

Thiersch: Arch. f. klin. Chir., vol. xvii, p. 318, 1874.

Wolfe: Brit. Med. Jour., September 18, 1875.

Krause: Arch. f. klin. Chir., vol. xliv, p. 177, 1893.

Ollier, P.: Bull. Acad. de Med., vol. ii, p. 244, 1872.

Tagliacozzi, G.: De Curtorum Chir. per insitionem, 1597.

Harsley, J. S.: Causes of Cicatricial Contraction. ANNALS OF SURGERY, vol. lxxxiv, pp. 185–202, August, 1926.

Jones, H. T.: Contracture of Axilla from Burns. Minn. Med., vol. xi, pp. 210–214, April, 1928.

Garlock, John H.: A Method of Reconstruction of Axilla for Contracture. Surg., Gynec., and Obst., vol. li, pp. 705–710, November, 1930.

Idem: Prevention of Cicatricial Contractions. Am. Jour. Surg., vol. viii, pp. 344-345, February, 1930.

Beckman, F.: Prevention and Treatment of Contractures Following Cutaneous Burns. Am. Jour. Surg., vol. vi, pp. 810–811, June, 1929.

Videman, G. T.: Plastic Surgery of Cicatricial Contractures of Underarm. Vestnikkhir (Nos. 56–57), vol. xix, pp. 323–328, 1930.

Treves, N., and Pack, G. T.: Development of Carcinoma in Burn Scars. Surg., Gynec., and Obst., vol. li, pp. 749–787, December, 1930.

Pack, G. T.: The Pathology of Burns. Arch. Path., vol. i, No. 5, pp. 767–805, May, 1926.

ARTIFICIAL INGUINAL HERNIA *

By Eske Harry Windsberg, M.D.
of Providence, R. I.

An artificial inguinal hernia is a hernia of the inguinal region that is deliberately produced. It is seen almost exclusively in wilful evaders of military service. Its formation involves a definite method of procedure which will be explained. The Russian literature is replete with writings on the subject. There are also several excellent articles in the German literature, and one or two in the Roumanian. In this country, A. G. Gerster,[1] A. V. Moschcowitz,[2] W. B. Coley,[3] and Parker Syms,[4] have made mention of the condition.

Artificial inguinal hernia has up to the present time been noted exclusively among Russians. Cases observed in this country had all been produced in Czarist Russia. There military service was long, compulsory, and entailed hardships unknown to the soldier of any other nation. Military service was particularly dreaded by Russian Jews; due to anti-Semitic feeling they were severely maltreated, and had to endure great mental and physical anguish. It is not surprising, therefore, that most artificial hernias have been found among Jews.

Inguinal hernia is only one of the many artificially produced ailments to which human ingenuity has turned in order to evade military service. Thus we find artificially produced phlegmons, granulomas, parafinomata, contractures, rectal prolapses, rectal fistulæ, and cystitis.[5] Artificial inguinal hernia is probably the most common of these conditions and lends itself most readily to identification as being of artificial etiology.

Artificial inguinal hernia, though somewhat of a curiosity in this country, is most interesting from an anatomical point of view. Furthermore, a thorough study of the subject gives one an excellent insight into the causation of direct inguinal hernia, and helps one to define the principles underlying a rational cure of direct inguinal hernia.

Definition.—For want of anything better, Moschcowitz[6] has introduced into the English literature the term "artificial inguinal hernia," to differentiate a type of inguinal hernia from natural and so-called traumatic inguinal hernia. Da Costa[7] employs the term "self-produced traumatic hernia." In the German literature are found the captions "artifizielle und Kunstliche Leistenbruche." This implies not only that the hernias are artificial, but also that they are made by a person adept at producing such hernias. Most persons state that they employed a "felscher" to have the hernia produced. "Felscher" is a Russian term synonymous with our "orderly."

* Thesis submitted to the University of Pennsylvania for the degree of Master of Medical Science [M.Sc.(Med.)] for graduate work in Surgery.

Historical.—In 1866, Sanizky[8] and Monkewitz[9] independently described atypical forms of inguinal hernia among Russian recruits. Their descriptions indicate that they were dealing with cases of artificial inguinal hernia although they were unaware of that fact. In 1888 and 1890, Orlow[10] recognized and described cases of artificial inguinal hernia: "A type of hernia occurring in young men of military age, hitherto never seen." It was his belief that they occurred only in Jews, and only on the left side. In the light of subsequent observations, both contentions were erroneous. Wroblewsky,[11] in 1891, reported eight cases which he had observed. In the same year, at the Tenth International Medical Congress held at Berlin, Bornhaupt[12] presented an undoubted case which had come under his observation at the Military Hospital at Kief. Even then the possibility that an inguinal hernia could be produced artificially did not meet with general acceptance.

In 1893, Schulz[13] was able to collect from the literature 133 cases of artificial hernia. All were direct; 121 were right-sided and only twelve left-sided. In 1894, Ignatow[14] reported twenty-two cases and Crasnoff[15] described eight cases that came to operation. Many other reports are presented in the Russian literature but up to 1899 no clinical differentiation was attempted. It was only in those instances in which the patient volunteered the information that an artificial etiology could be assumed definitely. Furthermore, surgeons did not believe that a person in good physical condition could sustain sufficient damage to the deep layers of the abdominal wall without narcosis to cause a hernia.

Etiology.—The production of an artificial inguinal hernia involves a definite method of procedure as practised by a "felscher." The patient is usually taken to an isolated field so that any outcry he may make will not attract attention. No anæsthesia is employed as a rule; in rare instances a little chloroform is used. The voluntary victim is placed on his back. While an assistant guards the upper extremities, the "operator" kneels astride the knees and thighs. The "operator" then invaginates the scrotum with the forefinger, and palpates the superficial inguinal ring. If only large enough to admit the tip of the finger, the ring is first torn. The forefinger is then plunged past the superficial ring mesially, downward and backward with sufficient force to overcome all resisting tissues. This involves a tearing of the posterior wall of the inguinal canal, namely, the transversalis fascia, a rather painful procedure for the patient. When the properitoneal fat and peritoneum are reached all resistance is overcome. Tearing of the peritoneum is almost impossible because of its laxity in this part of the inguinal region.

The foregoing manipulations having been completed, the patient is advised to take snuff liberally in order to produce sneezing. He is also ordered to exercise violently. In due time, ranging from several days to several months, a hernia becomes manifest. Sometimes a hernia does not develop even though the "felscher" has done his work perfectly. The reason for this will become apparent. The hernia produced is always of the direct variety. It presents at the mesial part of Hesselbach's triangle just lateral to the edge of the rectus and above the spine of the pubis. Although usually on the left side, these hernias are also seen on the right side, and may be bilateral.

Experimental.—The investigations of Galin,[16] in 1899, dispelled all the controversial points surrounding the subject of artificial inguinal hernia; he

conducted many experiments on the cadaver and also added several clinical observations. He showed that experiments carried out by workers before him were fruitless because they failed to tear the tissues deep to the superficial inguinal ring. In 1908, Krymow[17] repeated Galin's experiments, and added greatly to our knowledge of the subject.

Tearing of the subcutaneous inguinal ring, and splitting of the external oblique aponeurosis above the ring do not suffice to create conditions favorable for the formation of a hernia. For a hernia to develop under the foregoing circumstances the presence of a preformed sac must be assumed. In the absence of such a sac the transversalis fascia on the mesial aspect of the inguinal canal, corresponding to the fovea inguinalis medialis, must first be torn as this is the point where artificial hernias invariably present themselves. Then, and not until then, will a hernia be produced.

Galin produced hernias in the cadaver in the following manner: After invaginating the scrotum with the forefinger or a similarly shaped instrument, the intercolumnar fascia covering the superficial ring was torn. When the ring did not admit the tip of the finger or of the instrument employed, it was impossible to tear the ring directly. Any force exerted here tore the aponeurosis in the direction of its fibres above the ring, usually leaving the latter intact. But when the tip of the finger could enter the ring it was easily torn, the tear extending upward and outward in the direction of the fibres of the external oblique aponeurosis. The pillars of the ring did not tear away from their points of attachment.

Having passed the subcutaneous inguinal ring, Galin, in one group of cadavers, directed the force to the mesial side of the cord structures. If a fibrous layer covered Hesselbach's triangle it tore under the strain. If muscle covered the triangle the fibres separated without tearing. The transversalis fascia was now reached and torn; whereupon the finger or instrument met with no further resistance. In another group of cadavers Galin directed the force upward and laterally along the inguinal canal with the idea of reaching and tearing the abdominal inguinal ring. In these instances the cremaster muscle was torn either at the subcutaneous ring or within the canal. The finger was directed above and lateral to the inferior epigastric artery; Galin's aim was to attempt a production of an indirect inguinal hernia.

Following the aforementioned manipulations pressure was exerted periodically upon the abdomen from the front and sides. In some instances the intra-abdominal pressure was raised by injecting water per rectum against a tied-off œsophagus. Finally, in some cases, a mixture of hot water and plaster-of-Paris was injected intraperitoneally. In this manner casts of the peritoneal indentations and their relationships to the structures of the inguinal region were obtained. The type of hernia produced could thus be ascertained. Final deductions, however, were based for the most part on carefully conducted dissections.

When the force was directed mesially and backward, internal to the epigastric artery, a direct hernia was always produced. Galin found that it was well formed and that it always presented at the middle inguinal fossa (fovea inguinalis medialis) corresponding to Hesselbach's triangle. When the force was directed lateral to the inferior epigastric artery and the transversalis fascia in the neighborhood of the abdominal inguinal ring was torn, Galin found that only a small protrusion of the peritoneum occurred. This protrusion appeared not at the place where the fascia was torn, but at a point lower down, again in the neighborhood of the middle inguinal fossa. The peritoneal bulge here was small and wrinkled, and the hernia was not well formed due to the obstructing influence of the transversalis fascia which had not been divided in the lower half of the inguinal canal.

Here, too, Galin obtained a direct hernia in spite of the fact that he had attempted to produce one of the indirect variety. The hernial tract, however, was oblique and not perpendicular to the plane of the abdominal wall. Such a hernia was placed nearer to the abdominal inguinal ring, and its poorly developed sac covered the cord mesially and anteriorly. It thus gave Galin the impression of being an oblique hernia; but careful dissection and plaster-of-Paris impressions demonstrated that the bulge was medial to the inferior epigastric artery.

In the absence of a preformed sac it is only at the fovea inguinalis medialis that sufficient displacement and thinning out of the peritoneum occur to favor the development of a hernia. Upon this basis Galin explains the invariable finding of the direct variety both in artificial inguinal hernias and in inguinal hernias produced experimentally in cadavers.

The experiments and observations of Krymow[17] are of interest here. He tore the abdominal wall with a finger which, with the invaginated scrotum, was pushed up into the inguinal canal. The cadaver was then placed in the upright position. In some instances a hernia was immediately discernible. In others, besides the upright position, it was necessary to press on the abdomen before a hernia was noted. In a few, in spite of all the manipulations, careful dissections failed to disclose a hernia. Krymow explained the above findings on the basis of normal variations in the anatomical configuration of the inguinal region. Abdominal walls may be classified as being strong, of medium strength, or weak, according to the development of the muscular, fascial, and aponeurotic planes. The aponeurosis of the external oblique presents variations in thickness and uniformity, and in the absence or presence of defects in its structure. There are also variations in the size and shape of the subcutaneous inguinal ring. It may be triangular, oval, or round.

Krymow investigated fifty male cadavers (100 inguinal regions) and found variations in the shape and size of the inguinal interspace. This is the area lying between the lowermost fibres of the internal oblique and transversalis muscles above, Poupart's ligament below, and the edge of the rectus muscle medially. Forty-six of the interspaces presented a slit-like formation and the lowermost muscle fibres ran almost parallel to Poupart's ligament. In thirty-four instances the area was elliptical and in the remaining twenty it was triangular. In the triangular form the lowermost fibres of the internal oblique and transversalis muscles ran horizontally over to the edge of the rectus. Krymow found that in instances in which the interspace presents a large triangular formation, all other things being equal, the defense against hernia formation will be the weakest; on the other hand, when the interspace is slit-like, the defense will be the strongest.

Finally, Krymow found that the transversalis fascia is not of uniform strength throughout and presents also great individual variations. Along the edge of the rectus muscle the fascia is reinforced by the tendinous band of Heule, through which it receives attachment to the spine of the pubis. At the medial edge of the deep inguinal ring the fascia is reinforced by strong arcuate fibres known as the ligament of Hesselbach. The nearer the fascia approaches Poupart's ligament to become continuous with it, medial to the deep inguinal ring, the stronger its fibres become. This is true also of the lateral expanse of the fascia as it approaches the strong iliac fascia with which it becomes continuous. It is important to note that the weakest part of the transversalis fascia in the inguinal region is placed at the fovea inguinalis medialis, where practically all natural direct hernias and all artificial hernias occur.

Krymow dissected the inguinal regions of the cadavers upon which he had attempted to produce hernias experimentally. The tear in the aponeurosis of the external oblique always followed the line of its fibres. The pillars of the subcutaneous inguinal ring were apparently never torn. Nor did the transversalis fascia always tear; if loose it tore easily, if taut it stretched under the pressure of the finger without tearing. In the latter instance a strong blow in the form of a thrust was necessary to tear the fascia; and

even then it was not always torn, or else the peritoneum tore together with it. Krymow also noted that when the muscular layer was especially well developed a hernia did not ensue even though the external oblique aponeurosis and the transversalis fascia were torn. On the other hand, when the muscular layer was defective a hernia developed after an injury to one fascial plane, but only in the event that the other was congenitally weak. When the muscular layer was defective, and the external oblique aponeurosis poorly developed, with a wide inguinal ring, very little pressure, lasting from thirty to forty minutes, was required to thin out the transversalis fascia and cause a hernia to form. On dissection, in these instances, no gross evidence of a trauma could be discerned. Finally, in order to tear all of the layers of a strongly built inguinal region great force was required; and in such instances very frequently the peritoneum also was torn, resulting not in hernia but in a prolapse. This was especially true in cases presenting a very narrow subcutaneous inguinal ring with a soft and relaxed abdominal wall. When the abdominal wall was taut and distended much less force was required to bring about a prolapse.

Pathological Anatomy.—Our knowledge of the anatomical alterations and pathological changes occurring in artificially produced inguinal hernia is based essentially upon the findings noted by surgeons at operation. Some of the facts have been clarified by experiments on the still warm cadaver.

As noted heretofore, the degree of force necessary to produce an artificial hernia depends upon the strength of the anatomical components of the inguinal region. In instances in which all the layers of the inguinal region are poorly developed, with wide subcutaneous rings and triangular inguinal interspaces, very little pressure is required to thin out the transversalis fascia. So little force may be called for in these cases to create conditions favorable for a hernia to develop that at operation no evidence at all may be present to indicate that one is dealing with other than an ordinary direct hernia. On the other hand, in cases with strong inguinal regions the anatomical and pathological alterations are extensive and distinct.

Artificial hernias that come to the surgeon's attention early will be considered under diagnosis. Those that come to the operation long after they have been produced will be here considered, remembering that we are dealing with instances in which the trauma entailed must have been appreciable.

(*a*) *Anatomical Alterations.*—The subcutaneous inguinal ring is almost always injured and altered, and presents a triangular appearance. The tear in the ring extends upward and outward, parallel with the fibres of the external oblique aponeurosis. Occasionally the ring is found to be intact, and in such instances an abnormal opening in the aponeurosis is found just above the ring. This abnormal opening presents notched, ragged, and scalloped edges which are pathognomonic of a direct trauma. In the posterior wall of the inguinal canal there is found an abnormal opening which is placed in juxtaposition to the torn or naturally enlarged superficial ring, or to the tear in the aponeurosis of the external oblique above the ring. This abnormal opening consists of a hole in the transversalis fascia and surrounds the neck of the hernia. The tear is always found at the fovea inguinalis medialis. It is oval and admits from two to four fingers.

Frequently no trace is found of an inguinal canal. The cord structures are often separated from one another. The vas is firmly adherent to the sac and lies on its lateral aspect. The hernial mass appears as a bulge about the size and shape of half a chicken's egg cut longitudinally. Thus the neck of the hernia is wider than any part of the hernial bulge.

(*b*) *Pathological Characteristics.*—In artificial inguinal hernia pathological alterations are found which are due to extensive adhesions and fibrosis, and which are out of proportion to the small size of the hernia. The distortions, adhesions, and thick fibrous tissue encountered are comparable to those often found in a recurrent hernia. The impression one gets is that all the tissues and structures have been glued together. The superficial fascia is adherent to the subcutaneous inguinal ring. The crura of the ring are thickened and the superior crus is firmly adherent to the anterior surface and lateral edge of the rectus muscle. Normally this crus can be folded upward away from the underlying muscle when the inguinal canal has been opened. The cord is firmly fixed by fibrous tissue to the edges of the subcutaneous ring and can be freed from the canal and from the sac of the hernia only with the greatest difficulty. The transversalis fascia is strongly adherent to the peritoneum of the sac.

It is obvious, therefore, that in cases in which only the transversalis fascia has been torn the pathological signs may be trifling. Such instances are rare. In other cases, however, in which the trauma has been severe, the pathological changes are extreme and readily attract the attention of the operator. Between these two extremes the degrees of trauma inflicted and the resulting pictures of pathological anatomy are many and varied. Ordinarily sufficiently distinctive alterations are present to enable one to differentiate artificial inguinal hernia from the usual direct inguinal hernia.

Diagnosis.—The diagnosis of artificial inguinal hernia, in the absence of a reliable history, is based not on any single pathognomonic characteristic, but on the general picture of the condition. The surgeon who possesses knowledge of this type of hernia should have no difficulty in recognizing it. Although the diagnosis may be made upon physical examination, it can surely be done during the operation.

In the upright posture the patient presents a swelling just lateral to the edge of the rectus muscle in Hesselbach's triangle. The hernial mass usually shows no tendency to gravitate into the scrotum and on reclining it usually disappears spontaneously. Rarely, artificial hernias may become very large and even scrotal. Moschcowitz, who has operated upon many of these hernias, has never seen one that had descended into the scrotum. An artificial hernia is always a direct hernia. The only suggestion that it may be oblique has come from Solomka[18] who reported eight such cases. This view is remarkable in that these eight cases comprise his entire series and is contradicted by all the experimental and clinical evidence at hand. It is my belief that an oblique artificial hernia represents an instance in which a preformed sac was present. The unobliterated processus vaginalis offers

less resistance to the development of a hernia than does the artificially created defect at the middle inguinal fossa.

In recent cases examination reveals swelling, hæmatoma, tenderness, and ecchymosis. But by the time the hernia is fully formed and the patient presents himself to the physician, most of these signs are gone. The subcutaneous inguinal ring is examined by invaginating the scrotum with the finger in the usual manner. The crura of the ring are felt to be distinctly thickened—a condition which never obtains in the usual type of hernia. The superior crus of the ring cannot be lifted away from the underlying edge of the rectus muscle as is usually the rule. This thickening of the crura and fixation of the superior crus are believed by most writers on the subject to be the most dependable and most characteristic signs obtainable by physical examination. In every case which has come under my observation these signs have always been present and were readily discernible. Although probably not absolutely pathognomonic these findings are sufficiently characteristic to arouse the surgeon's suspicions and lead him to look for further evidences of artificial inguinal hernia.

These further evidences are discernible at the time of operation. As has already been noted, the pathological changes encountered are sufficiently distinctive to lead one to make the diagnosis even though the patient has been inadequately examined prior to operation. In early cases one finds signs of recent infiltration within and in the neighborhood of the inguinal canal and of the subcutaneous inguinal ring. In very early cases hæmatomata and ecchymoses may be seen. The characteristic pathology encountered in late cases has already been discussed. The operator is readily impressed by the obscured anatomical relationships, the firm adhesions throughout, and the fibrosis which has effected a generalized union of all the structures dealt with. He very soon realizes that he is dealing with something differing from the usual direct hernia. Dr. Leon Ginzburg,[19] adjunct surgeon at the Mount Sinai Hospital, had his suspicions aroused on two separate occasions while operating because he encountered such conditions. During convalescence close questioning elicited, in each instance, a history of artificially produced inguinal hernia.

Artificial inguinal hernia must be differentiated from true traumatic hernia of the inguinal region. So-called traumatic hernia need not be considered here. The traumatic hernia referred to is the direct accidental hernia resulting from an injury by a blunt instrument. It is not my intention to enter into a thorough discussion of the possible similarities and obvious differences between the two conditions; it suffices to state the following: (*a*) In rare instances only can a true traumatic hernia simulate an artificial inguinal hernia. The skin must remain unbroken, and the trauma must have occurred directly over the subcutaneous ring or just above it. (*b*) Usually, in traumatic hernia the injury occurs above or lateral to the ring, leaving it intact. The opposite obtains in artificial inguinal hernia.

Treatment.—The operative procedure to be employed in the radical cure of artificial inguinal hernia is in its essential feature clearly apparent to the surgeon who encounters one of these cases. This feature involves a recognition of the tear in the transversalis fascia, and the repair of the defect. The fascia in these cases is usually well defined, and affords an excellent tissue for the repair. It is not lax and thinned out over the hernial bulge as is the case in the usual direct hernia.

In clearing the structures of the inguinal region preliminary to the repair, careful, sharp dissection should be employed in order to avoid injury to the components of the cord. With a little patience the fascial planes can be cleared without creating operative defects, especially in the aponeurosis of the external oblique and in the peritoneum. The transversalis fascia, as it forms a collar about the neck of the hernial sac, is carefully dissected away and is then mobilized from the underlying peritoneum and properitoneal fat for about a half inch all around. In some cases the peritoneum need not be opened. The transversalis fascia is sutured over the hernial bulge. This fascia may be imbricated, or the edges may be brought together and then another row of sutures placed so as to infold the first row. When dealing with a lax fascia, a third row of stitches should be taken; the needle here practically always encounters firm transversalis fascia.

The final features of the repair need no special mention here since they are the same as those employed in the handling of any direct inguinal hernia. Moschcowitz[20] effects a purely fascial and aponeurotic repair and avoids the inclusion of muscle in his cardinal sutures. The aponeurosis of the external oblique is imbricated. The upper flap is sutured to the shelving edge of Poupart's ligament behind the cord, thus buttressing the repaired part of the transversalis fascia with nothing intervening between the fascia and the aponeurosis. The lower flap is sutured over the cord, creating for it an aponeurotic canal.

Case Reports.—My interest in the subject of artificial inguinal hernia began in November, 1929, when I had the opportunity to observe a case in the care of Dr. A. V. Moschcowitz. While preparing this thesis I have been on the lookout for similar cases and have been able to find two more. One of these cases was bilateral. Thus the writer has personally observed four instances of the condition. A casual search of the records of Mount Sinai Hospital revealed only two further cases. Doctor Moschcowitz, however, recollects that he has operated on quite a number of patients, approximately fifteen, in former years before emigration from Russia was restricted. Dr. Leon Ginzburg operated on one patient in 1925, and on another in 1926; the records of these two cases were located through his courtesy.

Case I.—S. G., twenty-eight years of age, born in Russia, admitted January 2, 1922, to Mount Sinai Hospital for left inguinal hernia, on the Surgical Service of Dr. Howard Lilienthal. He stated that the rupture was produced in 1915 in order to avoid military service; a left direct hernia with a defect in the abdominal wall, just lateral to the rectus muscle, about 3 centimetres in diameter. Edges of transversalis fascia palpable. The

superficial inguinal ring on the right side was enlarged but no hernia was present. Operation by Dr. Harold Neuhof; very extensive adhesions found; the defect in the transversalis fascia measured 7 by 7 centimetres. Poupart's ligament in its mesial aspect could barely be identified from the surrounding cicatricial tissue. The dense scar tissue was dissected away from the sac; during the manipulation the vas was accidentally cut across. The deep epigastric vessels had to be cut and ligated. The sac was opened, the excess ablated, and closed with a continuous chromic suture. The internal oblique and transversalis muscles were isolated from the scar tissue and sutured to Poupart's ligament with kangaroo tendon. The external oblique aponeurosis was imbricated behind the cord.

Case II.—J. G., forty-six years of age, born in Russia, was admitted October 23, 1922, to the Surgical Service of Dr. Edwin Beer, complaining of a hernia on the left side. He admitted that the rupture was induced by a "felscher," twenty-five years prior to admission. The swelling in his left inguinal region appeared one year after the hernia was induced. The patient wore a truss for many years. Examination revealed a direct hernia which disappeared spontaneously in the recumbent position.

This patient was operated on by Dr. Paul Aschner. A small direct sac was found and ligated. Closure was effected by a typical Bassini operation.

Case III.—H. R., thirty years of age, Russian, was admitted July 13, 1925, to the Surgical Service of Dr. A. A. Berg. He complained of a hernia of two years' duration. Examination revealed a hernial bulge in the left inguinal region just mesial to the pubic spine. The bulge disappeared spontaneously in the recumbent posture; evidently a direct hernia was present.

This patient was operated upon by Dr. Leon Ginzburg. A relatively large direct hernial sac was found adherent to the pubic spine. The vas was firmly adherent to the sac. The excess of the sac was ablated and the neck closed with a running catgut suture. The transversalis fascia was cleared and sutured. The internal oblique and the aponeurosis were sutured to Poupart's ligament. The cord was transplanted beneath the skin.

Before operation no history of artificial production of the hernia was obtained. In view of the unusual findings at operation the patient was subsequently questioned, and the following information obtained: About eleven years prior to admission, under anæsthesia, some manipulations were carried out with the idea of producing a hernia. In about two months, after taking snuff and performing strenuous work and exercise, a hernial bulge appeared. It has not increased materially since that time.

Case IV.—G. N., thirty-eight years of age, Russian, was admitted April 11, 1928, to the private care of Dr. Leon Ginzburg, complaining of a hernia on the left side. There was a definite bulge on standing which disappeared in the recumbent posture. At operation the external inguinal ring was found covered by a moderately dense layer of scar tissue and was adherent to the subcutaneous fascia. After the external oblique aponeurosis was incised, it was found impossible to deliver the cord because of marked adherence to a large direct hernial sac. It was finally freed from the sac by sharp dissection. Though the sac was large the ring was relatively small. The sac was opened, the redundant portion excised, and the neck closed with a purse-string suture. The transversalis fascia was cleared and sewed to the shelving edge of Poupart's ligament. The aponeurosis of the external oblique was imbricated behind the cord, leaving the latter in a subcutaneous position.

Following the operation this patient was questioned and he admitted that many years ago while still in Russia he had a rupture made in order to evade military service.

Case V.—S. B., forty-four years of age, Russian, was admitted November 7, 1929, to the private care of Dr. A. V. Moschcowitz with the diagnosis of recurrent artificial left inguinal hernia. The hernia was produced by a "felscher" in 1907. In 1913, before immigrating to this country, he had the hernia repaired; but it recurred very soon after the operation. Examination revealed a rather large left direct inguinal hernia. The

bulge presented at the lower angle of the previous operative cicatrix. There was present a wide defect in the transversalis fascia, admitting four fingers, the edges of which could be distinctly felt. This defect was just above the spine of the pubis and just lateral to the edge of the rectus muscle. A secondary operation was performed by Doctor Moschcowitz.

Case VI.—A. E., forty-two years of age, born in Russia, was admitted February 18, 1930, to the Surgical Service of Dr. A. A. Berg for treatment of peptic ulcer. Routine physical examination revealed also bilateral direct inguinal herniæ. The external ring admitted two fingers easily, and presented a triangular shape with the apex upward and outward. The mesial crus could not be lifted away from the underlying edge of the rectus muscle. Both crura were definitely thickened and rough, but were intact. There was a distinct hole in the transversalis fascia, the edges of which were quite thick. The diameter of this hole was about 4 centimetres in the transverse direction and about 2 centimetres in the supero-inferior direction. In the erect position there appeared a hemispherical bulge above the pubic spine just laterally to the edge of the rectus muscle. In the recumbent position the bulge disappeared spontaneously.

On questioning, the patient stated that twenty-two years ago he had a "felscher" produce a rupture for him. He was taken to an open field away from habitation and placed on his back with his hands clasped behind his head. The "felscher" knelt astride his thighs. He then invaginated the left side of the scrotum with his right forefinger, "Just like you are doing now," stated the patient as I was exploring his external ring. The "felscher" then tore something, and caused a great deal of pain. He was told to jump from tables and chairs and to do heavy lifting. In six weeks he returned to the "felscher" since a hernia had not yet appeared. The "felscher" told him that things had grown together again on the left side, and that he would have to repeat the procedure on the right side and the patient submitted to operation on the right side. Two months later no hernia appeared and he was accepted for military duty. Four months after going into the service, protrusions appeared on both sides and he was relieved from further duty because of his incapacity. These hernias have never given him any real trouble except that he is conscious of their presence. Partial gastroectomy was performed for his chronic peptic ulcer and he left the hospital well, without hernioplasty.

Case VII.—R. L., sixty-eight years of age, born in Russia, was admitted April 3, 1930, for a cardiac condition, in the private care of Dr. Murray Mintz. Routine examination revealed, also bilateral direct inguinal herniæ. In about 1884, at the age of twenty-two, after sixteen months of service in the Czar's army, he employed a "felscher" to make him a hernia. This was done on the left side and was accompanied by excruciating pain. A rupture appeared on the very next day without any further effort. About one month later he presented himself to the camp surgeon complaining of his hernia. The surgeon accused him of malingering and threatened to imprison him. About eight months thereafter a new surgeon was stationed at the camp, and he relieved the patient from further military duty. This patient states that it was a common practice to have hernias made and that many of his comrades were relieved from further military duty by this means.

About fifteen years ago, in 1915, a hernia appeared on the right side, following the lifting of a heavy parcel. In the erect posture a hemispherical bulge develops on the left side just above the spine of the pubis. The external ring was triangular in shape and admitted one finger comfortably. The edges were thickened and the mesial crus fixed to the underlying edge of the rectus muscle; this crus did not present a distinct sharp edge of its own. In the transversalis fascia there was a hole, about 4 centimetres in diameter, the edges of which were distinct. On the right side the bulge in the inguinal region was more diffuse, more shallow than on the left side. The external ring was oval and barely admitted one finger. The mesial crus presented a sharp, thin edge which could be lifted from the underlying edge of the rectus muscle. The transversalis fascia was lax, and it did not contain a demonstrable defect or tear. In the recumbent posture the bulge on both sides disappeared spontaneously. In this posture very slight coughing caused a pro-

trusion of the hernia on the left side, whereas hard coughing was required to make the hernia apparent on the right side. These hernias have never caused the patient sufficient discomfort to require operative treatment.

Of the seven cases noted above, six were on the left side and two were bilateral. They were all direct and none were scrotal. In 1925, Joil,[21] in his "Inaugural Dissertation," collected a series of 342 cases of artificial inguinal hernia. These were from various sources and appeared since the World War. It constitutes the largest series ever reported. The work is not available in the libraries of this country; however, a résumé is given by Wohlgemuth and Joil[22] in a subsequent article which appeared in 1928. They report on twenty-four patients upon whom they operated personally.

The twenty-four cases reported on by Wohlgemuth and Joil reveal some interesting features. They were all produced in what was formerly South Russia; namely, Kief, Charkow, Bessarabia, and Podalia. The contents of the sac consisted, usually, of small intestine or omentum. The bladder presented in two cases. Incarceration was noted in one case; this complication is rare and in the series of 342 cases collected by Joil it occurred in only two instances. The incarceration in all instances occurred not at the neck of the sac but at some distance from it and was caused by fibrous bands formed secondarily.

Discussion.—The theory of R. H. Russell[23] that all indirect hernias are congenital in origin and are due to the existence of a so-called preformed sac—*patent processus vaginalis*—is universally accepted. Regarding the etiology of direct inguinal hernia anatomical weakness of the muscular and fascial layers is taught to be the underlying factor. The transversalis fascia in these is of prime importance; a weakness or a defect in this structure plays a paramount rôle in the development of a direct hernia. Various factors such as weakness of the other layers, strenuous effort, obesity, increased intra-abdominal pressure, muscular atrophy, and a wide inguinal triangle are secondary although obviously important in the etiology. The significance of the transversalis fascia, though stressed by some authors, is for the most part not appreciated. A study of the etiology and anatomical defects of artificial inguinal hernia strikingly brings out the important rôle it plays. The necessity of suturing the tear in this structure when dealing with an artificial inguinal hernia is always so apparent that the operator never fails to execute this step. Although less obvious, because it is thinned out and spread over the hernial bulge, it is of equal importance to suture or reef this fascia in the operative treatment of the usual direct hernia. Recurrent direct inguinal hernia can be explained best by the failure to recognize and deal with the transversalis fascia. Following a hernioplasty for indirect inguinal hernia a recurrence in the form of a direct hernia is due either to a failure to recognize a concomitant direct hernia or to an inadvertent injury to the transversalis fascia during the operation. Likewise, direct hernia occurring after an Alexander operation is probably also due to injury to the transversalis fascia.

Another point clearly brought out is the rationale of a fascial repair as opposed to a combined fascial and muscular repair in dealing with direct inguinal hernia. Granting the importance of the transversalis fascia and the necessity of dealing with it, it is also essential to buttress this fascia. This cannot be done efficiently, if at all, by suturing the transversus and internal oblique muscles to Poupart's ligament as is done in the classical Bassini operation. Fascia can best be reinforced by other fascia. Thus, utilizing the aponeurosis of the external oblique without the use of muscle appears to be the rational procedure. Seelig and Chouke,[24] in a series of carefully conducted experiments, have shown that utilizing the muscle is not only useless but may actually be harmful. Moschcowitz[25] has obtained excellent results over a long period of years by a purely fascial and aponeurotic repair. He takes care to even excise the cremaster muscle where it would prevent a direct apposition of aponeurosis to fascia. He avoids inclusion of the muscle fibres of the internal oblique and transversus when placing his cardinal sutures in order to bring the mesial flap of the aponeurosis of the external oblique down to the shelving edge of Poupart's ligament. This flap is thus brought into direct contact with the repaired aspect of the transversalis fascia previously dealt with.[26]

BIBLIOGRAPHY

[1] Gerster, A. G.: Inguinal Hernia Artificially Produced. ANNALS OF SURGERY, vol. lv, p. 602, 1912.

[2] Moschcowitz, A. V.: Transaction of the N. Y. Surgical Society. ANNALS OF SURGERY, vol. xxiv, p. 265, April 26, 1911.

[3] Coley, W. B.: Inguinal Hernia, Artificial and Traumatic. ANNALS OF SURGERY, vol. lv, p. 602, 1912.

[4] Syms, Parker: Transaction of the N. Y. Surgical Society. ANNALS OF SURGERY, vol. lv, p. 602, 1912.

[5] Hesse, E.: Die chirurgische und gerechtlich-medizinische Bedeutung der künstlich heworgerufenen Erkrankungen. Arch. f. klin. Chir., vol. cxxxvi, pp. 275–291, 1925.

[6] Moschcowitz, A. V.: Hernia: Johnson's Operative Therapeusis. Vol. iv, p. 42, New York, D. Appleton & Co., 1915.

[7] Da Costa, J. C.: Modern Surgery. Ed. 9, p. 1120, Philadelphia, W. B. Saunders Co., 1926.

[8] Sanizky: Beobachtungen über Soldaten und die zur Wehrpflight einberufenen Personeum und Recruten, welche zur prüfung im Hospital gehalten wurden. Med. Auszugesammlung des Warschauer Kriegshospitals. Bull. ii, 1888. (In Russian; not read in the original. Quoted and reference cited by Galin, M. A., *vide infra.*)

[9] Monkewitz: Zur Frage der kunstlichen Leistenbruche. Aus dem Protokoll der Med. Versammlung im Warschauer Kriegshospital. Wratsch, vol. xxii, p. 640, 1894. (In Russian; not read in the original. Quoted and reference cited by Galin, M. A., *vide infra.*)

[10] Orlow, K. W.: Grundlagen der Diagnostik künstlicher und simulirter Krankheit bei Rekruten und Soldaten. St. Petersburg, Dissert. 1894. (In Russian; not read in the original. Quoted and reference cited by Krymow, A. P., *vide infra.*)

[11] Wroblewsky: Zur Frage der kunstlichen Hernien. Med. Sammlung des Warsh. Ujasdow Hospitals. (In Russian; not read in the original. Quoted and reference cited by Krymow, A. P., *vide infra.*)

[12] Bornhaupt: Ueber die künstliche Erzeugung von Hernien behufs Befreiung von der Wehrpflicht. Verhand. s.X. intern. med. Congresses, vol. xiii, pp. 182–184, 1891.

[13] Schulz: Die Diagnose der künstlichen Leistenbrüche. Wratsch, No. 50, 1893. (In Russian; not read in the original. Quoted and reference cited by Krymow, A. P., *vide infra.*)

[14] Ignatow: Material zur Frage uber künstliche Leistenbrüche. Nulit. Journal f. Med., B. 5, 1894. (In Russian; not read in the original. Quoted and reference cited by Galin, M. A., *vide infra.*)

[15] Crasnoff, W.: Uber künstliche Leistenbrüche. Nulit. Journal f. Med., Sept., 1895. (In Russian; not read in the original. Quoted and reference cited by Galin, M. A., *vide infra.*)

[16] Galin, M. A.: Über Brüche der Leistengegend künstlich-traumatischen Ursprungs. Arch. f. klin. Chir., vol. lx, pp. 104–175, 1899–1900.

[17] Krymow, A. P.: Die künstlichen und traumatischen Leistenbruche. Arch. f. klin. Chir., vol. xci, pp. 754–795.

[18] Solomka, N.: Die Leistenbruche bei den Juden in unserer Armee. Jahrb. d. russ. Chirurgie, 1898. (In Russian; not read in the original. Quoted and reference cited by Krymow, A. P., *loc. cit.*)

[19] Ginzburg, L.: Personal communication.

[20] Moschcowitz, A. V.: Personal observation.

[21] Joil, A.: Inaugural Dissertation. Jassy, 1926. (In Rumanian; not read in the original. Quoted and reference cited by Wohlgemuth and Joil, *vide infra.*)

[22] Wohlgemuth, and Joil: Artifizielle Leistenbruche. Arch. f. klin. Chir., vol. cli, pp. 406–410, 1928.

[23] Russell, R. H.: Lancet, vol. ii, pp. 1128–1131, 1900.

[24] Seelig, and Chouke: A Fundamental Factor in the Recurrence of Inguinal Hernia. Arch. Surg., vol. vii, p. 553, 1923.

[25] Moschcowitz, A. V.: Personal communication.

[26] Reichle, R.: Uber Gewaltbruche. IX, Kunstliche Hernien. Ergebnisse d. Chirurgie u. Orthopaedie, vol. xx, pp. 354–357, 1927.

HERNIA INTO THE PREVESICAL SPACE

By Irving J. Walker, M.D.

of Boston, Mass.

FROM THE HARVARD SURGICAL TEACHING SERVICE, BOSTON CITY HOSPITAL

Two cases of hernia into the prevesical space are reported in this paper as an addition to the small number now recorded in the literature.

Since other types of hernia have their origin in the same region, namely, the supravesical fossa, it would seem fitting that the subject of hernia of this space should be given some consideration.

The supravesical fossa is a triangular area bounded laterally and above by the lateral umbilical folds which cover the obliterated hypogastric arteries, and below by the peritoneal reflection which passes from the anterior abdominal wall to the fundus of the bladder. On both outer sides of this area are the middle inguinal fossæ.

Herniæ originating in the supravesical fossa have been known for a long time (Cooper, 1804). They have been mentioned in the literature under various titles, such as that of Wilms,[1] prevesical; Waldeyer,[2] supravesical; Klebs,[3] anterior retroperitoneal; Krönlein,[4] properitoneal; Leser and Linhart,[5] inner inguinal herniæ.

It is evident from these differences in terminology that the nomenclature has been based on various anatomical considerations. When a hernia has originated within the boundaries of the supravesical fossa, it would seem reasonable to accept the term advocated by Waldeyer and classify it as a supravesical hernia. Further elaboration of this classification can be made, dependent upon the structures or regions invaded by the hernia sac. As an example, the type of hernia discussed in this paper might well be called a supravesical hernia of the prevesical type.

The upper limit of the supravesical space in the region of the umbilicus is the tip of the angle formed by the junction of the lateral umbilical folds. In a downward direction the space widens between these ligaments as one approaches its lower aspect. The reflection of the peritoneum from the anterior abdominal wall backward to the fundus of the bladder marks the lower level of the fossa. Anteriorly, the space is limited by the musculature of the abdominal wall. Posteriorly, it is covered by peritoneum. Extending from the summit of the bladder to the junction of the lateral umbilical folds is the middle umbilical plica covering the urachus. This divides the supravesical fossa into a right and left half, sometimes termed the internal inguinal fossæ. The latter vary in depth according to the prominence of the folds above mentioned. Luttelmann[6] states that these folds may protrude in the fashion of a comb, each having a more or less definite mesentery. Below the peritoneum forming the lower boundary of the supravesical fossa, and lying between the bladder and the pubic bone, is a more or less triangular area known as the prevesical space or Space of Retzius. Laterally this extends to the outer limits of the bladder. In depth it reaches to the prostate and its covering. The region is filled with varying amounts of areolar tissue and fat and is subject to change in size and shape according to whether the

bladder is filled or empty. It is with herniæ into the prevesical space that we are concerned in this paper.

Etiology.—Undoubtedly several factors enter into the etiology of those herniæ arising in the supravesical fossa. Increased prominence of the lateral and middle umbilical folds is unquestionably a factor in the production of

PLATE I

peritoneal pockets. Rokitansky,[7] according to Reich,[8] was the first to call attention to the occurrence of these supravesical peritoneal pockets and to the possibility of hernial incarceration in the same.

Also of importance in the production of these herniæ is the possibility of weakened areas in the adjacent anatomical structures. Incidentally, Luttelmann has pointed out that individuals presenting supravesical herniæ of the external form show a predisposition toward other types of hernia.

If for any reason the subperitoneal fat shows atrophy, there is an additional tendency for the peritoneum of the supravesical fossa to become invaginated.

Luttelmann adds another possibility by presenting the theory that a previously existing inflammation beneath the peritoneum of this area with resulting scar-tissue contraction might result in invagination of the peritoneum.

Increased intra-abdominal pressure has been mentioned as another factor in the production of those herniæ which appear upon the surface.

These herniæ undoubtedly start as small peritoneal pockets aptly described by Luttelmann as "swallow-nest" formation. They may remain as such, or may develop by penetrating the abdominal wall, later demonstrating themselves as external forms of hernia. Because of the anatomical structure certain ones cannot ever appear upon the surface.

Where the musculature of the abdominal wall has been invaded, but where the sac does not appear upon the surface, this form of hernia has been termed interstitial.

After carefully reviewing case reports, we find that herniæ arising in the supravesical fossa tend to develop in three directions, dependent upon the part of the fossa in which the peritoneal opening is found. From this observation, which we do not offer as a constant rule, we can divide the supravesical fossa into three more or less distinct regions.

The first portion is represented by the area on the peritoneum overlying which is the rectus muscle. A hernia arising within this area points forward and should there be weakness of the rectus muscle may present itself upon the surface. In formation this may be likened to the well-known epigastric hernia; from its location, it can be termed hypogastric.

The second portion is a triangular area bounded on the inner side by an imaginary line on the peritoneum, representing the outer border of the rectus muscle; on the outer side by the lower part of the lateral umbilical plica, and below by the reflection of peritoneum extending from the anterior abdominal wall to the bladder. The width of this portion varies with the width of the rectus muscle together with the distance between the lateral umbilical folds. A hernia arising in this area has a tendency to point laterally outwards. Should there be weakness of the abdominal wall, it may appear upon the surface at the outer border of the rectus muscle, over or through the inguinal falx, above the lacuna ligament or just to the inner side of the femoral opening. In most cases, such herniæ, as Roser[9] and others have pointed out, carry ahead of the sac a lipomatous formation which unquestionably is a factor in their tendency to develop toward the surface. Many of these have been operated upon with the diagnosis of femoral hernia.

The third portion is represented by the peritoneal reflection which covers the Space of Retzius. Hernial formation originating in this area has a tendency to push downwards into the prevesical space. Because of the rigid anatomical structure, the pubic arch, on the anterior aspect of this space, such a hernia never becomes external.

The literature reveals numerous herniæ arising in the first two portions. As a matter of fact, those arising in the second portion constitute the greatest number of so-called herniæ of the supravesical fossa.

Reich's collection of cases and description of supravesical hernia is the first one in the literature covering the subject. The topic has also been discussed by Vogeler,[10] Marconi,[11] Luttelmann, Waldeyer, Watschugoff,[12] Bayer,[13] Schiele,[14] Kudrnac,[15] Brentano,[16] Belu,[17] Jæhne,[18] Fromme,[19] and others.

Hernia into the prevesical space, judging from the number of cases reported, is a rare condition. Personal interviews and communications with certain anatomists reveal none found in the cadaver. Cases I and III of Reich, and an additional one cited by Maydl,[20] are apparently the only ones reported to date, which leave little doubt as to their being herniæ into the prevesical space. There are other cases which because of inadequacy of reports and descriptions cannot definitely be considered by us to be prevesical herniæ, although certain of them may be such. Case II of Reich, as well as the single case of Brentano, and Case II in the series of Watschugoff, fall into this group.

To the three mentioned above we are adding two more, making a total of five cases of hernia into the prevesical space which have been reported to date according to our findings and case interpretations.

CASES REPORTED

CASE I.—J. D., male, aged fifty-one years, entered the hospital November 10, 1929, with the chief complaint of abdominal pain and vomiting. He stated that four days before a left inguinal hernia which had been present for years became pinched in the truss he was wearing. He noted pain in the region of the left external inguinal ring. The pain was cramp-like and lasted for twenty-four hours. After an interval of eighteen hours without pain, the latter recurred. There was no vomiting until six hours after the second onset of pain. The vomitus, at first light green in color, was later dark and of foul odor. An enema produced gas but did not relieve the pain. He had some frequency of urination for four days preceding entrance to the hospital.

Abdominal examination showed general distension with tenderness but no spasm. Auscultation revealed marked increase in peristalsis. Both hernial rings showed impulses on cough, but no evidence of a strangulated hernia. By rectal examination there was a moderately enlarged prostate. Pulse, 110. Respiration, 20. Temperature, 99.5°. Blood-pressure, 118/80. White count, 12,000.

The diagnosis of acute intestinal obstruction of unknown etiology was made.

Operation under spinal anæsthesia revealed an opening in the peritoneum three-fourths of an inch in diameter to the right of the umbilical ligament just anterior to the fundus of the bladder as illustrated in Plate I. Within this sac was a loop of strangulated ileum. The peritoneal edge of the sac was incised. A loop of viable bowel was removed from the sac. The latter extended two inches downwards into the prevesical space. The peritoneal lining of the sac could not be evaginated. The edge of the ring of the sac was freshened and the opening closed with a continuous catgut suture. The convalescence was uneventful. His health has remained good since leaving the hospital. There has been no frequency of urination such as existed just prior to operation.

Case II.—F. R., male, aged sixty-three years, was first seen in the hospital February 3, 1930. He stated that two days previously, shortly after eating fish, he was seized with abdominal cramps and vomiting. He had vomited off and on since then. The vomitus was at first light yellow in character but later was brown. His bowels had not moved since the onset of pain, even with cathartics. There were no other symptoms, other than some frequency of urination, which had been present for several years.

Physical examination was essentially negative except for the abdomen. This showed considerable distension with tenderness, but no spasm, or visible peristalsis. There was increased auscultory peristalsis. On the right was an enlarged external inguinal ring, through which a definite impulse could be felt on cough. There was no evidence of a strangulated hernia. Rectal examination was negative. Temperature, 99°. Pulse, 120. Respiration, 25. Blood-pressure, 134/80.

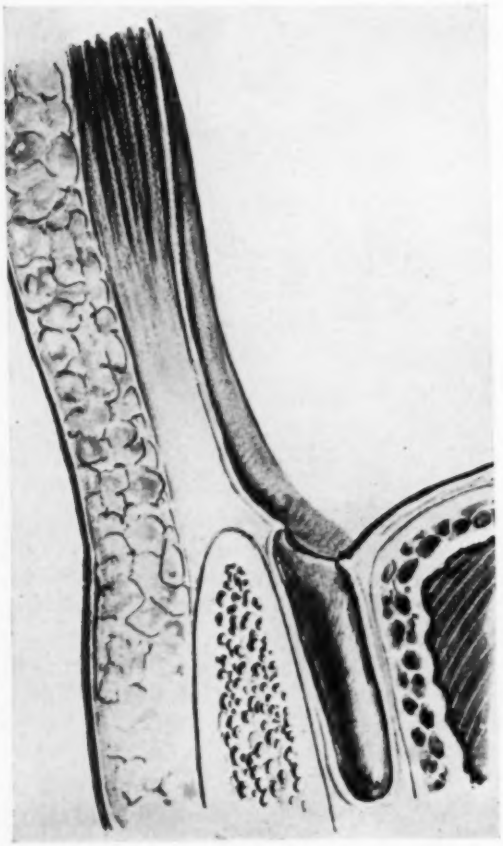

Plate II

A pre-operative diagnosis of intestinal obstruction of unknown origin was made, and operation advised. Exploration under spinal anæsthesia revealed no abnormality except a loop of ileum strangulated within a peritoneal pocket near the apex of the bladder, just to the right of the umbilical ligament. This was released after a small incision was made in the peritoneal edge of the ring. The bowel was found to be dark in color but viable. The opening of the sac was about one inch in diameter. The sac itself was about two inches long, extending downwards anteriorly to the bladder into the prevesical space as shown in Plate II.

The edges of the ring were freshened and the opening closed with a continuous suture of catgut. Because of the marked toxæmia accompanying the obstruction, a jejunostomy was done. The convalescence was uneventful. On February 28, 1930, he was cystoscoped with negative bladder findings. A cystogram was also negative.

Symptomatology.—Since herniæ into the prevesical space never demonstrate themselves upon the surface it is obvious that they will be discovered only incidentally in abdominal exploration or when they are attended with symptoms of intestinal obstruction which have led to operation. It is a fact that the pre-operative diagnosis of hernia into the prevesical space has never been made. The condition is apparently one affecting males of adult years. One can assume, we believe, that these herniæ give rise to no symp-

toms unless a viscus is present within the sac. With incarceration or strangulation of a viscus in a prevesical hernia, because of the proximity of the same to the bladder, one might expect some evidence of micturitional disturbance. Reich mentions that frequency of urination should be a common finding. However, since these cases occur in males of advanced years in whom prostatic disease is possible, urinary frequency is likely to be attributed to hypertrophy of this gland. A careful history taken post-operatively in our cases showed that frequency was present in Case I. In this instance it was of short duration, was relieved by operation, and has not recurred. In our second case the frequency could be explained by hypertrophy of the prostate. We feel that frequency of urination in cases of strangulation of a viscus in a hernia into the prevesical space can be considered a positive symptom of this condition, other causes of frequency having been eliminated. We also think that cystoscopical examination in the presence of a strangulated hernia into the Space of Retzius would reveal a bulging on the anterior wall of the bladder, produced by the tumor mass. Practically, such a positive finding might be of value in establishing the exact nature of the condition causing the obstruction. On the other hand, cystoscopical examination could be criticized as possibly adding to the risk.

The symptomatology that has led to operation in all cases reported has been that associated with acute intestinal obstruction. In any case, it is possible that there may have been previous attacks of ileus which have disappeared spontaneously. Such finding in the history should be of some significance in establishing the diagnosis.

The small bowel has been the strangulated viscus mentioned in all cases reported. Since the symptom complex of intestinal obstruction is so well known, it would seem unnecessary to further elaborate on that subject in this paper.

Reich has emphasized the importance of the presence of tenderness over the bladder and the presence of distended loops of intestine in the region of the symphysis as significant findings in the physical examination. Such observations were not noted by us.

Treatment.—Regardless of the value of the positive diagnosis of a strangulated hernia into the prevesical space, the treatment becomes that of combating toxæmia, followed by laparotomy. At operation the viscus will be found to be constricted by the opening of the hernial sac. In our cases it was not possible to release the intestine without first having made a small incision in the dense edge of the peritoneum forming the ring of the sac. This having been accomplished, the intestine was readily replaced within the abdomen. In neither instance could we evaginate the sac with the idea of excising it without considerable dissection, which we considered unwise in the presence of intestinal obstruction. The procedure which we followed and which we advise in all such cases of strangulated but viable intestine was release of the strangulated bowel, a freshening of the edges of the peritoneum making up the ring, and a closure of the latter by a continuous

suture. Obviously, with a non-viable viscus the operative procedure will become more elaborate.

The post-operative care should be directed towards treatment of the toxæmia of the patient. Upon the degree of the latter hinges to a great extent the outcome of any individual case.

SUMMARY

Hernia into the prevesical space is a rare type of internal hernia originating in the supravesical fossa.

An accurate pre-operative diagnosis of hernia into the prevesical space is possible but hardly to be expected.

The operative treatment offers no unusual problem.

The prognosis depends upon the degree of toxæmia accompanying the condition of strangulation when this is present, the ability or not to have recognized a hernia within the prevesical space, and the operative procedures involved in the individual case.

BIBLIOGRAPHY

[1] Wilms: Der Ileus. Deutsche Chirurgie. Lieferung, 46 g., 1906.

[2] Joessel-Waldeyer: Handbuch der topographisch-Chirurgischen Anatomie mit Einschluss der Operations—übungen an der Leiche. Nach dem Tode des Verfassers fortgesetzt von W. Waldeyer, 1884–1889.

[3] Klebs, Edwin: Handbuch der pathologische Anatomie. Bed. i, 1869.

[4] Krönlein, R. U.: Hernia inguino-properitonealis incarcerata. Arch. f. klin. Chir., vol. xix, pp. 408–420, 1875–1876.

[5] Linhart, W.: Vorlesungen über Unterleibs-Hernien. Würzburg, 1866.

[6] Luttelmann, J.: Ueber supravesickale Hernien. Breslau, 1919.

[7] Rokitansky, Carl: Lehrbuch der pathologischen Anatomie. 3 Aufl., vol. iii, 1861.

[8] Reich, A.: Ueber eine neue pericoecale Hernie, die Hernie des Recessus coecalis. Beitr. z. klin. Chir., vol. lxiv, pp. 1–34, 1909.

[9] Roser, quoted by Luttelmann and Vogeler.

[10] Vogeler, Karl: Die supravesicalen Hernien. Beitr. z. klin. Chir., vol. cxviii, pp. 318–341, 1919.

[11] Marconi, Albert: Hernia supravesicalis-externa. Wien. Med. Woch., vol. lxx, pp. 512–514, 1920.

[12] Watschugoff, A. P.: Ueber die intraabdominalen Hernien der Foveae supravesicales auf Grund dreier eigener Beobachtungen. Deut. Zeit. f. Chir., vol. ccxxx, pp. 342–344, 1931.

[13] Bayer, Carl: Hernia juxtavesicalis dextra incarcerata. Zentralbl. f. Chir., vol. xlix, pp. 671–673, 1922.

[14] Schiele, George: Hernia supravesicalis interna incarcerata. Zentralbl. f. Chir., vol. liii, pp. 1252–1254, 1926.

[15] Kudrnac: Hernia juxtavesicalis incarcerata dextra. Zentralbl. f. Chir., vol. liii, pp. 88–89, 1926.

[16] Brentano: (Freie Vereinigung der chirurgen Berlins) Hernia retroperitonealis anterior sinistra. Zentralbl. f. Chir., vol. xxiv, p. 821, 1897.

[17] Belu, N.: Hernia juxtavesicalis incarcerata dextra. Zentralbl. f. Chir., vol. liii, pp. 1124–1125, 1926.

[18] Jæhne, A.: Beitrag zur operativen Benhandlung der inneren Hernien. Beitr. z. klin. Chir., vol. lvi, pp. 439, 447, 1907–1908.

[19] Fromme, Albert: Uber einen Fall von Hernia retroperitonealis anterior sinistra incarcerata. Deut. Zeit. f. Chir., vol. xcii, pp. 365–371, 1908.

[20] Maydl, K.: Die Lehre von den Unterleibsbruchen, 1898.

INTERSIGMOID HERNIA

By Denver M. Vickers, M.D., and Stanley T. Fortuine, M.D.
of Cambridge, N. Y.

FROM THE SURGICAL SERVICE OF THE MARY MCCLELLAN HOSPITAL

Intersigmoid hernia, of all the types of internal hernias, still remains one of the more unusual surgical conditions. Although anatomists agree that the intersigmoid fossa can be demonstrated in a considerable proportion of cases coming to their attention, surgeons, in the operating rooms or wards, meet with intersigmoid hernia very infrequently.

Internal hernia, in general, presupposes the protrusion of abdominal contents through some ring entirely within the abdomen. Of the various possibilities, those about the duodenum are probably most common; the so-called paraduodenal hernia, with the protrusion of bowel through some fossa left on the developmental attachment of the duodenum to the posterior abdominal wall. Nine sub-varieties of this hernia have been described,[1] with the sac at various points behind the duodenum.

Another group are found about the cæcum or ascending colon; the ileocolic or ileo-cæcal hernias, of which four varieties have been described.[2] In these, the sac is between the layers of the ascending mesocolon, with the difficulty arising from the embryological rotation and attachment of the colon and cæcum to the posterior parietal peritoneum.

Others occur through the transverse mesocolon, through rents in the broad ligament, and into the always-present foramen of Winslow. And a smaller group have been reported in the region of the sigmoid colon. It is this condition, of intersigmoid hernia, that we are now discussing.

All of this group of hernias are protrusions through an opening which is performed, and not the result of some operative or inflammatory condition, though these conditions doubtlessly are more often the cause of acute obstruction of the intestine.

The intersigmoid fossa is described in Gray's Anatomy[3] as a distinct and fairly constant structure. It is usually present in the fœtus, and frequently found during infancy, but gradually disappears in a majority of cases as age advances. It is best seen by drawing the sigmoid colon upward and to the right, thus exposing its attachment to the posterior abdominal wall. Here lying on the external iliac artery, in the space between the psoas and iliacus muscles, there is a pouch, funnel-shaped, with the opening to the left and downward. This varies in size from a mere dimple to a definite sac. It has been described as being like the middle finger of a surgeon's rubber glove. It is behind the sigmoid mesocolon, and in front of the parietal peritoneum.

The older authorities found this anatomical landmark in varying proportions. Treves[4] is quoted as finding the fossa in 52 per cent. of all cases;

Waldeyer[5] in 84 per cent.; Moynihan[6] in 70 per cent.; and of recent workers, Bruce and Ross[7] in 1924 examined forty-six cases and found the fossa present in 80 per cent. But in distinct contrast to the frequency with which this fossa is found by anatomical research is the infrequency with which it is seen by the surgeon. The fossa must be frequently present, but apparently the bowel is very infrequently caught in it, as clinical cases are very rare. There is no differential pressure to aid in the production of an internal hernia, as there is in hernia through the ordinary sites, although peristalsis can act very much in the same fashion and accomplish the same result. Apparently, the opening is usually covered by the surrounding layers in a fairly efficient fashion.

Bruce and Ross,[7] in 1924, found nine cases in the literature up to that time, and added a tenth. These cases included the early fatal cases of Eccles[8] and Eve,[9] which were observed around 1885, much prior to the other cases in the series. Then a fatal case of Lambret,[10] found at operation, and a case in a newborn infant, also fatal, reported by Coley.[11] Up to 1908, these four, the first two of which have been questioned, were the only cases on record.

The first successful case was that of Krall,[12] in 1910, a man who was operated on and recovered. Machol[13] reported a case in a man of sixty-six, and next we find the autopsy findings of a well-described case by Nuzum and Nuzum;[14] then the recovered case of Taylor,[15] a case cited by J. B. Murphy,[16] in his Clinics, and the very large hernia into the intersigmoid fossa, reported by Bruce and Ross,[7] in 1924, from Toronto. This case was operated on, but the bowel was gangrenous over such an extent that resection could not be done, and the exact condition was described, very accurately and completely, from the autopsy a few hours later. Of these ten, only three were reported as having lived; in other words, there was a very high mortality connected with the diagnosis of intersigmoid hernia.

Since this report and summary of ten cases, a few more have appeared in the literature. H. Erkes[17] in 1923, from Leipzig, reported the case of a man of twenty-one, with a history of twenty-four hours' obstruction. This patient was operated on, had a loop of bowel removed from the intersigmoid fossa and made a good recovery.

In 1926, A. J. C. Hamilton[18] had a case in Edinburgh. A woman of forty-three, with a history of obstruction for two days, was operated on, and a loop of bowel 12 inches long removed from the intersigmoid fossa. The patient made a good post-operative recovery, but died on the nineteenth day, apparently from the rupture of an intra-thoracic aneurism.

The same year, McCarthy[19] had a case in Erie, Pa. A boy of twenty was operated on seventeen hours after the beginning of his obstruction. Operation showed extensive gangrenous small bowel, and he died in six hours.

The next year, Kostic[20] reported a similar case from Leipzig. A woman of thirty-three, with the usual symptoms of intestinal obstruction, was operated upon, a loop of bowel removed from the intersigmoid sac, and the patient made a good recovery.

This brings the series, including the case that is being reported here, to a total of fifteen cases. The mortality in the last group, excluding the case

of Hamilton, where death was due to thoracic disease, was one out of five. This is perhaps due to the more recent general recognition of the fact that in any type of intestinal obstruction early operation is imperative. Of course no formal conclusions can be drawn from a small series. So this brings the total mortality, excluding the case of Nuzum and Nuzum,[14] where the condition was found at autopsy, with death due to another factor, to seven out of fifteen cases, or 47 per cent. These, with the exception of the infant reported by Coley, were all patients of adult life, generally from twenty to fifty-five years. Most of them were in men; a few were in women.

Treatment is essentially surgical. Diagnosis is practically never made before operation. These hernias can usually be reduced by gradual traction, and if the bowel is not viable, it should be resected. In the reported cases, no attempt has been made to close the sac, and this seems not only technically difficult but unnecessary.

Report of authors' case.—M. F. W., Hospital No. 4988, a white boy of eighteen years, was admitted to the Mary McClellan Hospital October 13, 1929, complaining of vomiting. His father and mother were living and well; he had two sisters living and well, and none had had trouble similar to his own. His general health had been good until the present illness. About a month before admission, he noticed dull pain in the right side of the abdomen, which occasionally became colic-like, or more severe. This continued in moderate form, but he was able to continue his work regularly at school. Two days before admission, while playing ball, he was bruised on the left side and had rather severe immediate pain. During the next twenty-four hours, the pain became more intense and more severe near the umbilicus. He vomited several times, and retained practically nothing by mouth. His bowels had not moved for three days.

He was a well-developed and nourished boy of eighteen, considerably distended, with occasional "intestinal patterns" over the abdomen. He appeared prostrated and acutely ill. General physical examination was negative. His heart sounds were good and his lungs clear. His temperature was 100.5° and his pulse 100. There was no sign of inguinal, femoral or umbilical hernia. Rectal examination gave no further information. Intestinal obstruction was evident.

The abdomen was opened under spinal novocaine. A greatly dilated small intestine presented itself, which on being traced down led to a loop caught in a small opening about the size of the index finger, in the left side of the sigmoid mesocolon, and approximately over the left iliac artery. Through this foramen approximately half of the circumference of the loop of bowel was caught. In other words, this was a partial enterocele, or a Richter's hernia. This bowel was gently extracted. It appeared viable, and resection was not done. The abdomen was closed in layers, with a small drain going down to the fascia. The patient's bowels moved while he was on the operating table.

For the first twenty-four hours, his post-operative course was rather stormy. He was given fluids intravenously and subcutaneously. Gradually his condition improved and he was given fluids by mouth. He was on soft diet at the end of a week. His pulse and temperature gradually came down, and his wound healed. He was allowed out of bed in two weeks, made a good convalescence, and has had no further trouble.

BIBLIOGRAPHY

[1] Coley, B. L.: Strangulated Left Duodenal Hernia. Arch. Surg., vol. xviii, p. 868, March, 1929.

[2] Coley, W. B., and Hoguet, J. P.: Retrocæcal Internal Hernia. Annals of Surgery, vol. xc, p. 765, October, 1929.

[3] Gray's Anatomy, p. 1267. Lea and Febiger, Philadelphia, 1913.
[4] Treves: Hunterian lectures.
[5] Waldeyer: Quoted by Eve.
[6] Moynihan, B. G. A.: Retroperitoneal Hernia. Wm. Wood and Co., New York.
[7] Bruce, H. A., and Ross, J. W.: Intersigmoid Hernia. Surg. Gynec. and Obstet., vol. xxxix, p. 15, July, 1924.
[8] Eccles, MacAdam: Quoted by Bruce and Ross.
[9] Eve, F. S.: Quoted by Bruce and Ross.
[10] Lambret: Quoted by Bruce and Ross.
[11] Coley, W. B.: Strangulated Retroperitoneal Hernia of the Intersigmoid Fossa. Tr. Am. Surg. Assn., vol. xxvii, p. 445, 1909.
[12] Krall: Quoted by Bruce and Ross.
[13] Machol: Quoted by Bruce and Ross.
[14] Nuzum, F., and Nuzum, J.: Quoted by Bruce and Ross.
[15] Taylor, G.: Quoted by Bruce and Ross.
[16] Murphy, J. B.: Quoted by Bruce and Ross.
[17] Erkes, H.: Ztrb. f. Chir., vol. l, p. 306, February 24, 1923.
[18] Hamilton, A. J. C.: Edinburgh Med. Jour., vol. xxxiii, p. 448, July, 1926.
[19] McCarthy, F. P.: Atlantic Med. Jour., vol. xxix, p. 872, September, 1926.
[20] Kostic, M.: Ztrb. f. Chir., vol. liv, p. 962, April 16, 1927.

STRANGULATED FEMORAL HERNIA*

ANATOMY AND SURGICAL TREATMENT

By Virgil S. Counseller, M.D.

DIVISION OF SURGERY, THE MAYO CLINIC

AND

Forest W. Cox, M.D.

FELLOW IN SURGERY, THE MAYO FOUNDATION

OF ROCHESTER, MINN.

The incidence of femoral hernia has been variously reported by different authors. Coley[1] stated that the proportion of femoral to inguinal hernia at the Hospital for Ruptured and Crippled is as 1 to 17, and the same at the London Truss Society. It is relatively much more common among females than males, although even among females inguinal hernia is much the more common type. Femoral hernia is usually unilateral; the right side is more frequently involved than the left. It rarely attains the large dimensions that are not uncommon in inguinal, umbilical or post-operative hernia. Strangulation is believed to be more common than in inguinal hernia, because of the small and rigid orifice through which the protrusion occurs, and the unyielding, sharp-edged fascia that forms the anterior wall of the canal.

Successful repair of femoral hernia requires complete acquaintance with the anatomy of the femoral region, and since it is often poorly understood, we have had Figs. 1 and 2 prepared, which demonstrate accurately the true relationship of the important structures. It can be seen in Fig. 1 that the femoral vessels lie on a muscular floor composed of the iliacus, psoas and pectineus muscles and separated from them by a tough fascia which surrounds the muscles and becomes a part of the femoral sheath. The femoral vein is adjacent to the femoral canal, and as the hernial sac proceeds through the short canal and out through the fossa ovalis, it is in contact with the terminal portion of the long saphenous vein which enters the femoral vein through the fossa ovalis. (Fig. 2.)

The femoral sheath is a conical, membranous investment of the femoral vessels. It is derived from the fascial lining of the abdominal cavity. The fascia transversalis is carried distally in front of the vessels, and the iliac fascia behind them, as they pass from the abdomen into the femoral triangle. The sheath is about 3.75 centimetres in length, and is divided into three compartments: namely, a lateral compartment for the artery, an intermediate compartment for the vein, and a mesial compartment, containing lymph-vessels and fat, named the femoral canal. (Fig. 1.) For clearness, the fascial bands separating the sheath into three compartments are not shown in the drawing. External to the femoral artery lies the anterior crural nerve. The femoral canal is the passage through which a femoral hernia enters the thigh. Its mouth, or proximal end, is the femoral ring, bounded anteriorly by the inguinal (Poupart's) ligament, posteriorly

* Submitted for publication December 15, 1931.

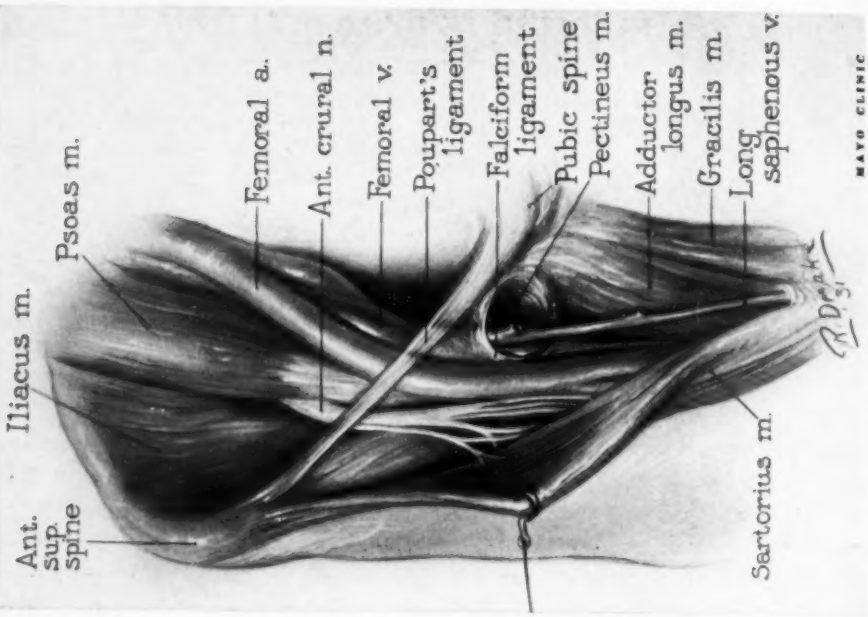

FIG. 2.—Anterior view of the femoral and inguinal regions. The sartorius muscle is retracted laterally, showing the relationship of the femoral vessels as they pass under Poupart's ligament. The muscles of the abdominal wall have been removed.

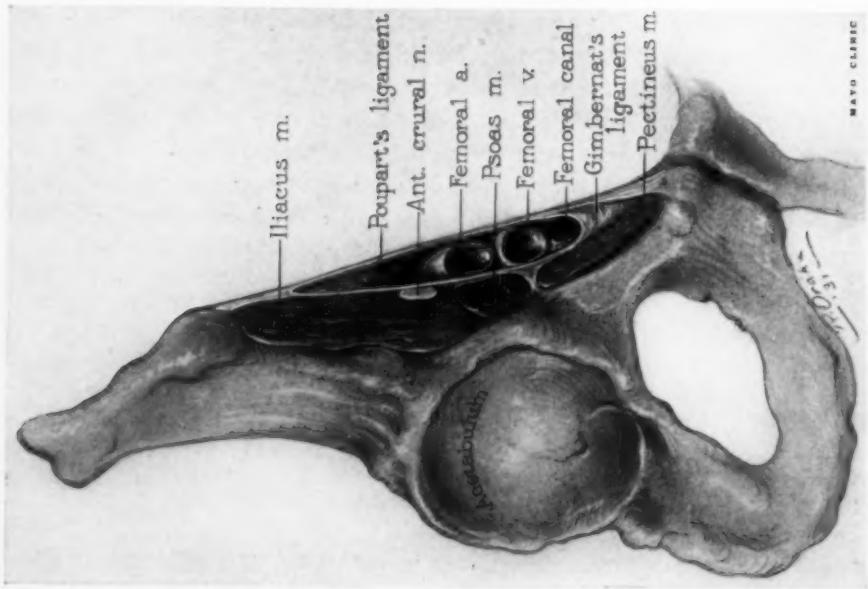

FIG. 1.—Cross-section of the femoral and inguinal regions in the plane of Poupart's ligament and passing through the acetabulum.

by the origin of the pectineus muscle from the pubis, mesially by the lacunar (Gimbernat's) ligament, and laterally by the femoral vein. The femoral canal ends in the fossa ovalis. Its distal part is under cover of the fascia cribrosa, while the superior cornu of the falciform margin crosses over it and conceals its proximal portion. (Fig. 2.) The course of a femoral hernia is determined by that cornu. The hernia descends through the femoral ring, and after passing into the femoral canal is directed through the fossa ovalis. The anterior part of the hernia is pressed on and retarded by the femoral arches; the posterior part pushes onward, hooks around the cornu, over the falciform edge, and is directed upward over the inguinal ligament. The points of strangulation are at Gimbernat's ligament and the falciform edge of the saphenous opening. The coverings of a femoral hernia, in addition to peritoneum and extra peritoneal tissue, are femoral sheath, fascia cribrosa, superficial fascia, and skin.

Perhaps the most cogent reason for reporting these cases is that they give an opportunity to reëmphasize the high mortality attending strangulated femoral hernia. Gibson[3] gives 47 per cent. as the mortality noted thirty years ago, and with all of our increased knowledge of physiological disturbances in intestinal strangulation in general, which have become known since then, the mortality has decreased but very little. However, it is only fair to state that there are certain factors which contribute to the mortality over which we have very little control. Patients with femoral hernia are likely to be old, and senility, beyond all question, is one of the principal causes, since, when patients are old, pneumonia frequently develops, and usually is rapidly fatal. The incidence of pulmonary embolism is increased among old people, which may be due to a drop in blood-pressure and retardation of the flow of blood. The cardiovascular systems of old patients cannot tolerate the prolonged general anæsthesia or the marked drop in blood-pressure from spinal anæsthesia which has been known to occur if patients had definite myocardial degeneration. Failure to recognize the condition and to refer the patient for early operation adds to the mortality. Fowler[2] stated that of all reported cases of Richter's hernia, wherever situated, 50 per cent. were unrecognized early, and that all the patients died. Femoral hernia frequently takes the form of Richter's hernia, which never includes the complete circumference of the bowel, and in the majority of cases the obstruction is only partial. Frequent and futile attempts at reduction by manipulation often cause delay, which could well be avoided. The magnitude of the accident and the seriousness of the symptoms may be discredited by patient and physician alike, mainly because the obstruction may not be complete. In Case I, obstruction was incomplete, although one-half of the circumference of the bowel was slowly being injured. In this instance the hernia occurred seventy-two hours before admission, and although symptoms of partial obstruction were present, the patient did not seek relief until fifty-six hours later.

The following two cases are of interest on account of the advanced age of the patients, because both types of strangulation usually seen in femoral hernia are represented, and because the patients recovered following operation.

Case I.—A woman, aged eighty-six years, while straining at stool three days prior to registration at the clinic, had a sudden enlargement of an old femoral hernia of the

right side, which could not be reduced. At once, she began to have severe, cramp-like pains in the hernia, which were continuous. Nausea and repeated attacks of vomiting occurred intermittently, but the vomitus became fecal in character twenty-four hours prior to her admission. Neither gas nor feces had been passed since the onset of the attack.

There was a history of recent œdema of the legs, graded 3, but it had nearly disappeared before this accident. The patient had a moderate amount of dyspnœa and dizziness on exertion. The cardiac tones were clear, but rhythm was irregular, and there were extra systoles. The blood-pressure was 160 millimetres of mercury systolic and 100 diastolic. The abdominal wall was thin and flat. There was an irreducible, strangulated, right femoral hernia about four by seven centimetres. A tympanic note was elicited on percussing the mass. Leucocytes numbered 21,000 in each cubic millimetre of blood. Immediate surgical repair was advised.

Under local anæsthesia, the sac was easily exposed after sectioning the falciform edge of the fascia above the saphenous opening. It contained a piece of omentum and a knuckle of ileum (Richter's hernia). The omentum was pulled out and excised, which

FIG. 3.—Section of ileum removed in Case II. The devitalized portion is evident.

at once relieved the pressure on the ileum, and the normal color of the strangulated bowel returned. The bowel was replaced in the abdomen and the hernia repaired by suturing Gimbernat's ligament and the pectineus fascia to the lower edge of Poupart's ligament with interrupted sutures of No. 2 chromic catgut. Convalescence was not complicated, and the patient was dismissed from the hospital on the twelfth post-operative day.

CASE II.—A woman, aged seventy-seven years, for one year had had a painless swelling, about 2.5 centimetres in diameter, in the right femoral region. Thirty hours prior to registration at the clinic, this swelling had suddenly increased to approximately ten centimetres in diameter, and she had begun to have excruciating abdominal pain, associated with severe vomiting. All attempts to reduce the hernia had failed.

On examination there was a large, oblong, irregularly firm, nodular, and slightly tender mass in the right inguinal and femoral regions. The abdomen was distended and rigid, graded 2. The heart was normal in rate and rhythm, and the blood-pressure was 148 systolic and 100 diastolic. Leucocytes numbered 14,000 in each cubic millimetre of blood. A diagnosis of strangulated femoral hernia was made, and immediate operation advised.

Under general anæsthesia, the mass was explored through a vertical incision. The sac was freed by sectioning the falciform edge of the fascia which was producing the

strangulation. The sac contained approximately forty centimetres of strangulated, gangrenous small intestine and a considerable amount of strangulated omentum. The omentum was firmly attached to the sac by old adhesions. The strangulated omentum was excised and removed. The gangrenous intestine was pulled from the hernial aperture and resected well beyond the devitalized portion. (Fig. 3.) The ends of the bowel were closed, and a side-to-side anastomosis was performed. The hernia was then repaired by suturing Gimbernat's ligament and the pectineus fascia to the lower edge of Poupart's ligament with interrupted sutures of No. 2 chromic catgut. Convalescence was not complicated.

According to Scarpa's[5] observation, obstruction becomes complete only if two-thirds of the intestinal wall is constricted. Rhodes'[4] recent study clearly proves that the type of hernia in which only part of the circumference is included (Richter's) is seen more commonly in females and occurs more frequently on the right side; also, that it is involved in femoral hernias more than in inguinal hernias. This type of hernia also becomes manifest in femoral hernias of long duration. This point is important since femoral hernias may exist for years without many symptoms. Early in life a femoral hernial sac is surrounded by a rather thick layer of adipose tissue which is designated the pre-peritoneal fat and is continuous with that adjacent to the bladder. After the fifth and sixth decades of life, and particularly in women following menopause, there is gradual but progressive atrophy of this protective fatty layer which is coincident with relaxation of the fascia of the abdominal wall. The peritoneal sac then may slowly increase in size, permitting intestine and omentum not only to enter more easily but to stretch farther into the femoral canal. The diameter of the femoral ring will be increased on account of these changing influences. If it is as large as in Case II, the hernia may reach an unusual size, which is rare, but it will then contain a large segment of intestine, usually ileum, and omentum; both will be strangulated due to the unyielding, sharp-edged fascia that forms the anterior wall of the femoral canal above, and the rigid Gimbernat's ligament, situated below and posteriorly. When a segment of ileum is suddenly thrust beyond these points of strangulation, the constriction of the bowel and mesentery is complete, and all the symptoms of acute intestinal obstruction, such as pain, vomiting, abdominal tenderness and collapse occur. The symptoms in this type of femoral hernia are more violent than in the Richter type. Autolysis of the mucosa of the strangulated intestine, and abnormal absorption through the mesenteric vessels, quickly occur. The pain is agonizing, and is associated with abdominal colic and marked hyperperistalsis. The tenderness, which is first over the mass, as in Case II, soon passes up over the abdomen with the advent of peritoneal irritation, abdominal tenderness, distention, rigidity, and rapid and feeble pulse.

The symptoms in the Richter type of hernia, especially early, depend entirely on the amount of the intestinal wall that is involved. There may be only a very small segment occluded which would induce only localized pain associated with some epigastric distress resulting from the pull on the

mesentery. The sensation of pulling is characteristic of the milder degree of obstruction. Nausea and vomiting, with increasing tenderness at the femoral ring, are factors which indicate that more of the lumen of the bowel is being occluded. Omentum, which is frequently included in the hernial contents, may offer some protection to the circulation of the bowel, thereby saving the wall from rapid necrosis.

Treatment is entirely surgical. It should be instituted early before the signs of strangulation become obvious if intestinal resection is to be avoided and if the mortality is to be reduced.

A vertical incision directly over the mass affords the best exposure. (Fig. 4.) The sac is reached immediately beneath the superficial fat and fascia, where its further isolation should be effected by blunt dissection. By placing the index fingers in the canal it can be stretched sufficiently to relax

FIG. 4.

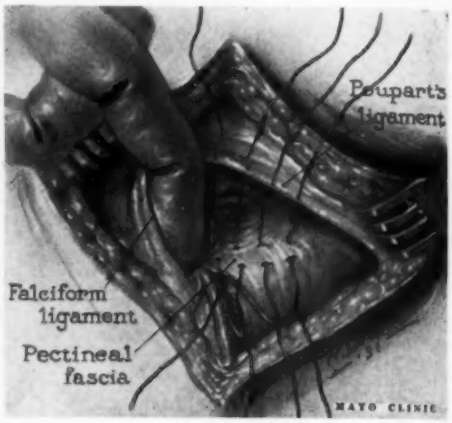

FIG. 5.

FIG. 4.—The hernial sac is exposed through a vertical incision. The falciform ligament has been partially sectioned above to increase the diameter of the femoral opening.
FIG. 5.—The interrupted sutures are in position and the femoral and long saphenous veins held laterally by the index finger.

the Richter type of hernia. In the large hernia containing a loop of bowel, it is advisable to section externally the falciform fascia with the Mayo type of scissors. The sac is opened and the bowel pulled out beyond the points of strangulation to determine whether the bowel is viable. If the normal color of the bowel, and pulsation in the vessels of the mesentery, return within a few minutes, it is safe to replace the bowel and quickly to repair the hernia. Otherwise, if this does not occur, it is necessary to resect the devitalized bowel well beyond the injured area either with an end-to-end or side-to-side anastomosis. If patients are very ill, it is often better to perform an exteriorization type of operation and then later an anastomosis. Better continuity of the bowel is obtained by the side-to-side type of anastomosis, since distention and hyperæmia of the proximal loop frequently render an end-to-end type unsafe. The larger opening secured through the former assures more complete drainage of the proximal loop. Extensive

resection does not often become necessary in the Richter type on account of the fact that obstruction is incomplete and there is necrosis of only a portion of the circumference of the bowel. Here local excision of the necrosed portion and transverse closure of the opening will suffice. The bowel in this type may drop back into the abdomen when the sac is being separated, so that if it is not searched for and repaired, the necrosed portion will slough out and the contents of the small intestine pour into the peritoneal cavity.

The repair of the hernia is simple and easy to perform. After the sac is excised, the fascia of the pectineus muscle and the lower edge of Gimbernat's ligament are sutured to Poupart's ligament with No. 2 chromic catgut. As a rule, four sutures are sufficient to close the femoral opening. The danger of injuring the femoral vein by sticking or compressing it is obviated by retracting it with the index finger (Fig. 5) while placing the sutures. There should be sufficient room between the vein and the last suture to admit the index finger.

BIBLIOGRAPHY

[1] Coley, W. B.: Quoted by Stone, H. B.: Hernia. In: Lewis, Dean: Practice of Surgery, vol. vii, chap. 9, 79 pp., Hagerstown, Maryland, W. F. Prior Co., 1929.

[2] Fowler: Quoted by Rhodes.

[3] Gibson, C. L.: A Study of One Thousand Operations for Acute Intestinal Obstruction and Gangrenous Hernia. ANNALS OF SURGERY, vol. xxxii, pp. 486–514, October, 1900.

[4] Rhodes, R. L.: Partial Enterocele; Richter's, Littre's Hernia. Trans. South. Surg. Assn., vol. xli, pp. 175–187, 1928.

[5] Scarpa: Quoted by Rhodes.

STRANGULATED FEMORAL CYSTOCELE

By Anthony P. Vastola, M.D.
of Waterbury, Conn.

American literature has not very often recorded the occurrence of the urinary bladder in a strangulated femoral hernia. The Mayo Clinic has never issued a report on it. Coley stated: "I am sure the condition is a very rare one." He did not mention this complication in a series of 8,589 hernias operated upon between 1890 and 1918. Neither did Hoguet observe the condition in 2,468 hernia operations. Moschowitz, Erdman, Gallie and Mathews have never encountered it. Bevan and Lyle have seen the condition but have never published their findings. It was therefore necessary to search the foreign literature for published cases; and it is the object of this article to present a résumé of their points of interest, to discuss the diagnosis and treatment of this rare surgical disease and to report two of my own cases.

Investigation has disclosed that the first two clinical cases of femoral hernias of the bladder were reported by De la Porte, in 1750. Then, according to Verdier, no other cases were reported until 1890, when Aue mentioned the case of a man operated upon by Tiling which was probably the first femoral cystocele observed at operation. It was not until 1901 that Tailhefer reported the first case of a strangulated femoral cystocele. The diagnosis was made during the course of the operation and to confirm his suspicion he deliberately incised the tumefaction.

The *anatomical structure* of a strangulated femoral cystocele is essentially similar to that of the uncomplicated kind. According to the relationship of the bladder to the peritoneum they are divided into: (*a*) Intraperitoneal, in which there is a complete hernia sac containing the bladder process. (*b*) Paraperitoneal, in which the herniated bladder process is covered on one surface only by peritoneum. (*c*) Extraperitoneal, in which the herniated portion of the bladder is neither engaged nor contiguous to a hernia sac. Such hernias may be primary or secondary; the primary are either extraperitoneal or paraperitoneal, while the secondary are intraperitoneal or paraperitoneal. The ten previously published cases consisted of three of each type, and one case of a diverticulum which was unclassified. To these may be added my two cases: Case I, a diverticulum which, excepting Forques', is the only case published of a bladder diverticulum in a strangulated femoral hernia; and Case II, an extraperitoneal hernia of the bladder. Alessandri believes that it is very difficult to determine whether the herniated portion of the bladder, in doubtful cases, is really a diverticulum or whether it has assumed the form of a diverticulum since the herniation; it is obvious that this differentiation is even more difficult when the hernia becomes strangulated.

The *etiology* of strangulated femoral vesical hernias is a varied one. In regard to age all writers seem to agree that the condition appears nearly always during adult life and particularly in older people. Previous vesical affections seem to be a contributory factor in the production of the condition; also in women previous pregnancies and the presence of uterine or other pelvic tumors. Muscular effort, which is often mentioned in connection with the strangulation of ordinary hernias, is infrequently recorded in cases of strangulated vesical hernias. In three of the ten cases previously described in the literature, a cough precipitated the complication in two; a slight muscular exertion caused it in two others and in three no muscular effort was mentioned. My two patients were at absolute rest when the strangulation occurred. But repeated and continued exertion during urination is almost constant; prostatic enlargements or urethral strictures are often present. Jaboulary and Villard emphasize the fact that the same cause which brings about the distention of the bladder also provokes muscular effort, which is due to difficult urination.

The *symptoms* of a strangulated femoral cystocele are neither characteristic nor constant. Its clinical picture is very often a bizarre one; it necessarily varies according to what structures or organs are strangulated with the bladder. A careful history will disclose that in the majority of cases the hernia was irreducible for a long time previous to its strangulation and that the mass diminished in size and felt doughy after urination.

Urinary symptoms are not always present, but when present they are masked by gastro-intestinal symptoms which are usually of a reflex type. Only three of the cited cases had difficult or painful micturition either just before or after the strangulation; the remaining cases had no urinary symptoms. In the two cases which I have appended, Case II had genito-urinary symptoms which simulated closely a renal colic. In my opinion the severity of symptoms referable to the urinary tract is dependent directly upon the proximity of the ureter to the strangulated portion of the bladder. Obviously, if the ureteral orifice is involved in the strangulation, all the classical symptoms of a renal obstruction will be present, together with the reflex gastro-intestinal symptoms which are usually associated with an obstructive lesion of the renal tract. In contrast to the severity of the symptoms presented by my second patient, Case I had only those urinary symptoms which one expects to see in a patient with a prostatic enlargement.

Disturbances of the gastro-intestinal tract in the form of abdominal distention, pain, nausea, vomiting and obstruction when present may be due directly to a concomitant strangulation of the intestine, or they may be entirely reflex in character. Four of the six cases described, which had nausea and vomiting, also had symptoms of an intestinal obstruction, although the operation did not disclose a strangulated intestine, and in one of these cases there was no hernia sac found. In my second case the history elicited the fact that his attack had started with painful and difficult urination, but

his gastro-intestinal symptoms were so dominant that a diagnosis of intestinal obstruction was made in spite of the presence of hæmorrhagic urine.

The diagnosis of a strangulated femoral cystocele, in the absence of urinary symptoms, is a very difficult one. Of the ten cases reported and the author's two, none was diagnosed before the operation; eight were diagnosed during the course of the operation and four after the bladder was cut. If with the history of an irreducible femoral hernia the patient has the urinary symptoms enumerated; and if a cystoscopical examination should show a vesical defect on the side of the hernia, which is confirmed by cystography, the diagnosis of a strangulated femoral cystocele becomes a positive one.

Treatment.—Shock which is invariably present must be combated. Before resorting to surgery the bladder must be catheterized and the bowels evacuated by an enema. In addition it is advisable to apply heat to the mass and to give a hypodermic injection of morphine. An attempt to reduce the mass is then made, and if it fails the patient is informed that an operation is imperative.

The anæsthesia of choice is spinal or local. To expose the mass an incision below and parallel to Poupart's ligament is made. The hernia sac if present should be carefully examined to determine its relation to the strangulated bladder. When the bladder is intraperitoneal and adherent to the interior of the sac or to the omentum, it is carefully dissected free and reduced into the peritoneal cavity.

In a paraperitoneal bladder hernia the treatment will vary according to the size of the bladder hernia and its relation to the sac. A small hernia is separated from the peritoneal sac by gauze dissection and invaginated through the femoral ring and so reduced. No attempt should be made to strip off a large peritoneal sac which covers a considerable portion of the bladder; instead, an excision is performed around the inner side of the peritoneal sac so as to leave its medial portion intact with the bladder, and the latter reduced.

The bladder in an extraperitoneal hernia may be mistaken for the peritoneal sac and incised. If this is done the bladder should be immediately sutured with a through-and-through continuous suture of catgut and reinforced by a second Lembert catgut suture.

In either of the three types of bladder hernias, after the bladder is reduced, the peritoneal sac is transfixed high up in the femoral ring and excised. This is followed by one of the usual methods of closing the femoral ring. But if the strangulated portion of the bladder consists of an intraperitoneal diverticulum, there might be danger of sloughing with leakage of urine and peritonitis if the bladder were closed tight and a radical repair of the hernia performed; under these circumstances the procedure should be that employed in my first case.

The patient is made more comfortable and bladder tension is relieved by inserting in the bladder a retention catheter and permitting it to remain in place for at least ten days. If, unfortunately, during the operation the

bladder is cut, it is advisable to drain the wound with a small cigarette drain for a few days.

CASE REPORTS

CASE I.—G. P., aged seventy years, was admitted to St. Mary's Hospital at 9:50 P.M., September 1, 1928. Seen on entrance in consultation with Dr. J. H. McGrath. His chief complaint was a generalized abdominal pain, which began twenty-four hours previously in the right lower quadrant, and was accompanied by nausea and vomiting. He had no previous serious illness or abdominal disturbances, although for the past four years he had noticed an increasing frequency and difficulty in urination. He was in great pain, as he lay in bed with knees flexed. The abdomen was rigid and somewhat scaphoid in appearance, and palpation elicited a tenderness which was generalized but most

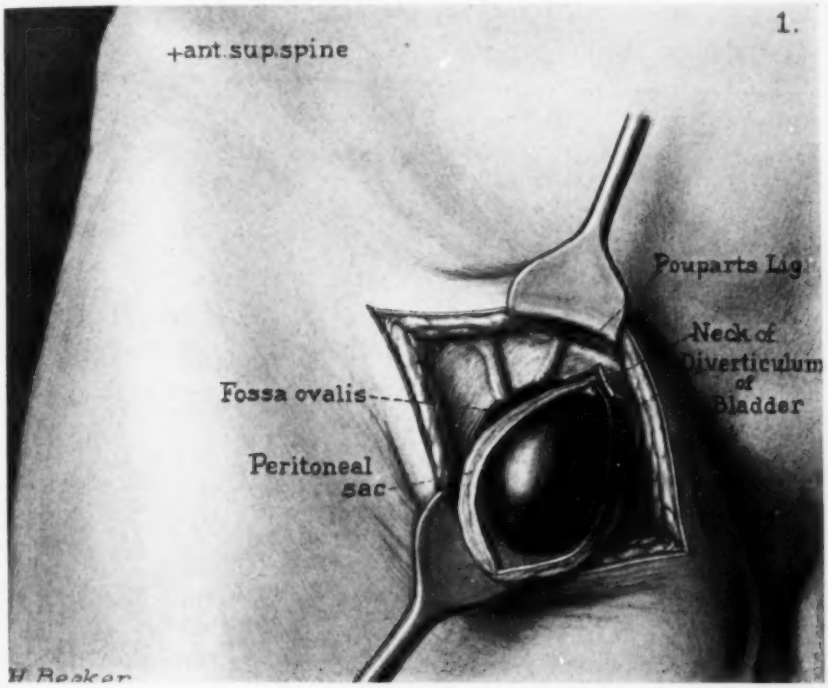

FIG. 1.—Hernia sac opened and showing its contents: a diverticulum of the urinary bladder.

intense in the right lower quadrant. His liver and spleen were not enlarged. The temperature was 103° F., pulse 109, and respiration 24 to the minute.

Since the sequence of his symptoms, the physical examination and blood-picture pointed to a typical case of acute suppurative appendicitis, a more thorough examination of his genito-urinary tract and hernia regions was not made.

Operation at 11:45 P.M., I removed, through a right rectus incision, an acute suppurating appendix. He reacted well from the operation and had no unusual symptoms until September 4, when, at 2:00 P.M., he complained of a sudden excruciating pain in the right femoral region. He stated that he had had a swelling in the right femoral region for twenty years, and that it had never caused him any discomfort. Examination disclosed in the right femoral region a very painful, irreducible mass about two inches in diameter. It was tense, it gave no impulse on coughing, could not be compressed, was dull to percussion and, apart from a slightly distended and painful abdomen, it was not associated with any symptoms referable to the genito-urinary and gastro-intestinal

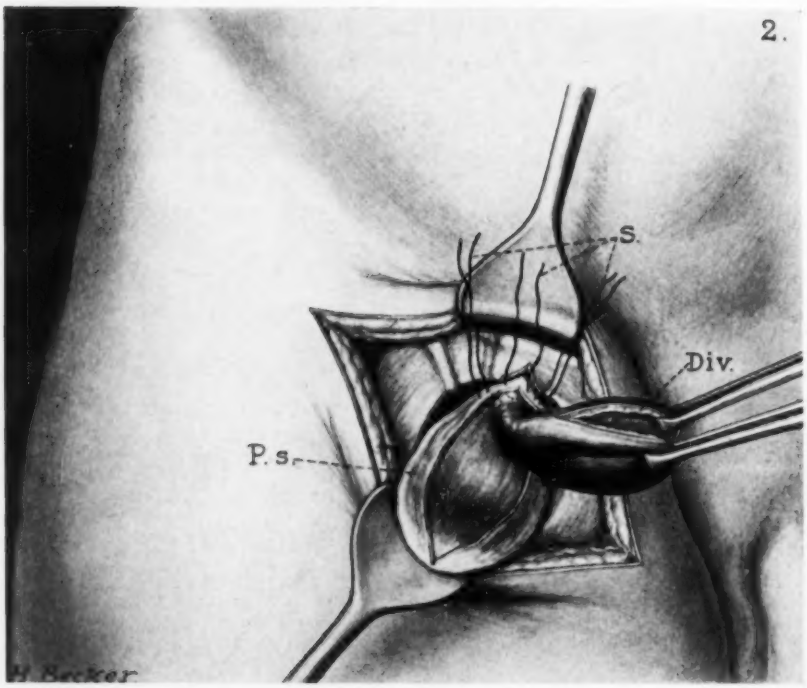

FIG. 2.—After the structure in the hernia sac had been identified the neck of the bladder diverticulum was pulled down and sutured high up to the interior of the neck of the peritoneal sac by interrupted catgut sutures.

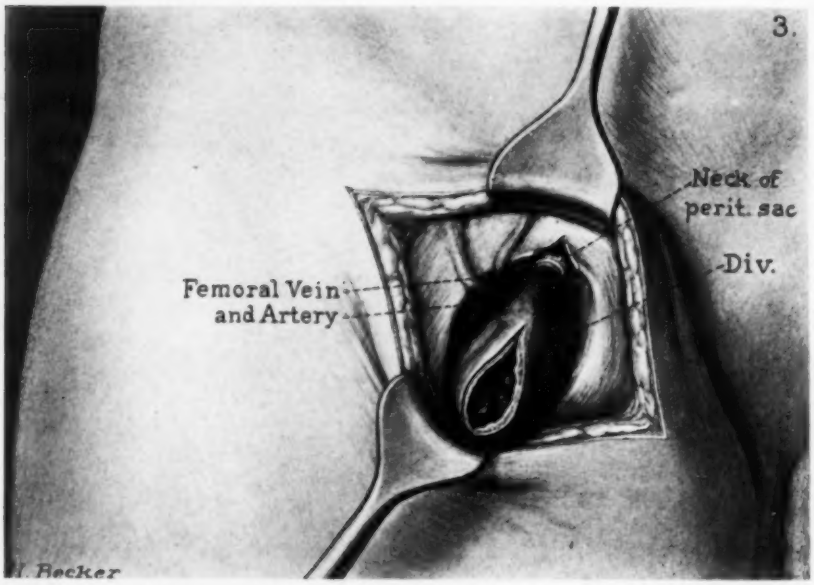

FIG. 3.—The peritoneal sac was excised, and the skin loosely brought together with silk worm-gut sutures around the diverticulum. Drains were inserted in the lower angle of the wound.

tracts. An enema was given and the patient expelled a light brown liquid stool which gave him relief but it had no effect on the femoral mass. The impression given was that he had a strangulated right femoral hernia which contained an incarcerated loop of intestine.

Operation September 4 at 4:00 P.M., under local anæsthesia with a 2 per cent. neocaine solution, an incision parallel with Poupart's ligament and over the mass was made. A tense, congested sac was exposed, through the transparent walls of which could be seen a serosanguineous fluid. The constricting femoral ring was incised upwards sufficiently to relieve the strangulation, and the sac was then opened and evacuated of its hæmorrhagic fluid.

The content of the sac was a pear-shaped, thick, muscular, purplish structure which did not conform to anything I had ever seen before in a hernia sac. Digital examination and traction disclosed that its neck came from behind the pubis and as it lacked a mesentery it occurred to me that it might be a bladder diverticulum. It was accordingly

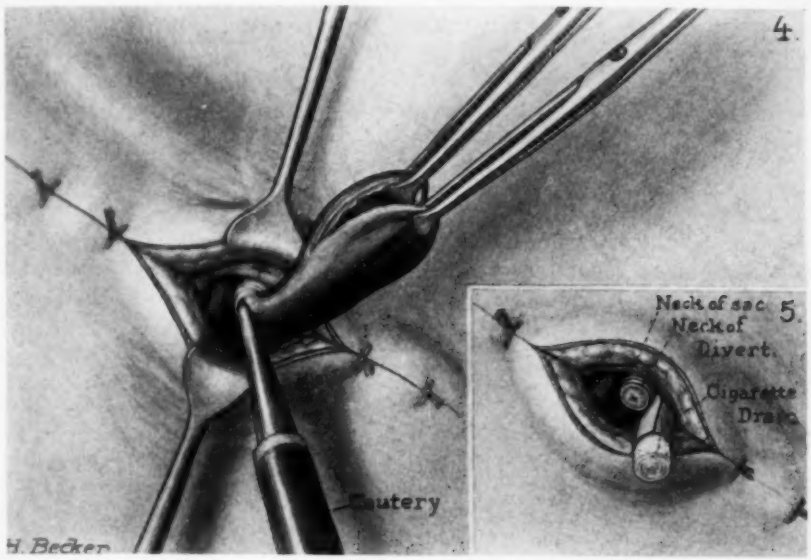

FIG. 4.—Four days later the distal portion of the diverticulum was extirpated with a Paquelin cautery.
FIG. 5.—Shows the neck of the diverticulum with its cuff of peritoneum, and drain in the lower angle of the wound.

opened and my suspicion was confirmed by the escape of a small amount of yellow fluid; the index finger was then gently guided towards the mid-line behind the pubis and into the bladder.

The neck of this diverticulum was pulled down and attached by interrupted sutures around the interior of the hernia sac as high up in the femoral ring as possible, thus closing it off from the peritoneal cavity. The remaining portion of the hernia sac was then excised, and the skin loosely brought together with silkworm gut sutures, leaving the bladder diverticulum protruding from the wound, in the lower angle of which was inserted a cigarette drain. Four days later the portion of the diverticulum distal to the femoral ring was extirpated with a Paquelin cautery, and the opening in the bladder permitted to close in. It drained a diminishing amount of urine for ten days. On September 30, twenty-six days after the second operation, the patient was discharged from the hospital with both wounds healed and with a cure of his femoral hernia.

CASE II.—F. P., a man, aged fifty-nine years, was seen by me on May 9, 1932, at 8:30 P.M. It was stated that the man, while reading, had felt a peculiar burning sensa-

tion in his urethra which was accompanied by a desire to urinate. This feeling disappeared and recurred several times within a period of twenty minutes. It was followed by a severe chill and a sharp pain in the right lumbar region which radiated down his right ureter and then became localized over the right femoral region. His bowels had moved well that morning, and up to the present illness he had never experienced any similar attacks.

Thirty years ago he first noticed a swelling which was diagnosed as a right femoral hernia, and which was never completely reducible. During 1925, he suffered from severe attacks of dizziness, nausea and vomiting and was informed that he had Meniere's disease. In 1926, a tonsillectomy and the following year an appendectomy and a cholecystectomy were performed upon him. He denied any venereal infection, nor did he up to the present illness, have any symptoms referable to his genito-urinary tract. He had always suffered from low back pain and constipation.

When first seen by me he was in bed with knees flexed, and was vomiting. His expression, as he held his distended abdomen with both hands, denoted intense pain. Temperature was 97° F., by mouth, pulse 120 to the minute. In his right femoral region was a swelling about three and one-half inches in size, painful to palpation and dull to percussion. The outer portion of this swelling was slightly distended and irreducible; the medial half could be made to disappear by gentle and steady compression and as it diminished in size a soft irreducible mass could be felt. When the pressure was released the tumefaction slowly reappeared and with it an agonizing pain.

As the patient's general condition denoted a moderate degree of shock he was surrounded with hot-water bags and given a hypodermic injection of morphine sulphate gr. $\overline{ss}$. After the pain had subsided he was given a soap-sud enema which was not effectual. A second attempt to reduce the femoral hernia was made but again was unsuccessful. The impression made was that the man had a strangulated right femoral hernia.

Operation May 10 at 1:30 A.M., under spinal anæsthesia with neocaine, an incision slightly below and parallel with Poupart's ligament and through the superficial fascia exposed the lower two-thirds of that ligament. Dissection extending along the line of incision below Poupart's ligament exposed the femoral mass protruding from the constricted femoral ring, which was incised. The area above Poupart's was cleared of its adipose tissue, uncovering the aponeurosis of the external oblique, the external abdominal ring and spermatic cord. A dissection along the lateral side of the mass exposed the hernia sac, which had on its medial side an unusual amount of what at first appeared to be tenaciously adherent fat. The hernia sac, about one and one-half inches in length, did not appear to be acutely congested; when opened it was found to be empty. It was then grasped together with the fat adherent to its medial side by an artery clamp; the conjoined tendon and the cord were retracted medially and the artery clamp which grasped the hernia mass was thrust underneath Poupart's ligament and the exposed floor of Hesselbach's triangle. An incision was then made in the transversalis fascia pushed up by the artery clamp, and the hernia sac was drawn through the opening. An excision with scissors of the fat still adherent to the medial side of the sac was begun when an opening about two inches in length was made into a muscular hollow organ which was identified as the bladder. It was immediately sutured with a continuous through-and-through interlocking stitch of No. 2 chromic catgut and reinforced by a second continuous Lembert stitch. The hernia sac was transfixed with a needle and plain catgut and followed by the closure of the femoral ring with two interrupted chromic catgut sutures, approximating Poupart's ligament to Gimbernat's ligament and the pectineal fascia. A cigarette drain was inserted at the lower angle of the wound and the incision closed by interrupted silkworm gut sutures, following which a retention catheter was inserted in the bladder and allowed to remain in place for ten days. The post-operative course, apart from blood appearing in the urine for seventy-two hours,

was uneventful; there was no leakage of urine from the wound and the patient was discharged from the hospital sixteen days after the operation.

Summary.—Strangulated femoral cystocele is rare and in 100 per cent. of the reported cases the pre-operative diagnosis was incorrect. When the strangulation of an old irreducible femoral hernia is associated with spasmodic pain over the mass which radiates to the pubic region, along the urethra and to the lumbar region, and when these symptoms are accompanied by difficult, frequent, painful and hæmorrhagic urination, the presence of a strangulated bladder should be kept in mind. The diagnosis can be confirmed by cystography. Ten cases of strangulated femoral cystocele previously recorded have been reviewed, and two additional cases have been described.

REPORTED CASES OF STRANGULATED FEMORAL CYSTOCELE

CASE I.—(Abadie.) Female, aged twenty-six years; left side. Gastro-intestinal Symptoms.—Nausea and vomiting. Genito-urinary Symptoms.—None. No diagnosis made pre-operatively; made during operation. Type.—Para.* Other structures strangulated with bladder—none. Bladder cut. Recovered.

CASE II.—(Baricci.) Female, aged forty-three years; right side. Gastro-intestinal Symptoms.—Nausea and vomiting. Genito-urinary Symptoms.—Frequent, painful, and difficult urination. No diagnosis made pre-operatively; made during operation. Type.—Extra.† Other structures strangulated with bladder—right Fallopian tube. Recovered.

CASE III.—(Laskownicki.) Female, aged sixty-five years; right side. Gastro-intestinal Symptoms.—Nausea, vomiting, tympanitis, no bowel movements. Genito-urinary Symptoms.—None. No diagnosis made pre-operatively; made during operation. Type.—Para.* Other structures strangulated with bladder—none. Bladder cut. Recovered.

CASE IV.—(Tailhefer.) Female, aged sixty-one years; right side. Gastro-intestinal Symptoms.—Nausea, vomiting of fecaloid material, inability to evacuate bowels or pass gas. Genito-urinary Symptoms.—Frequent, painful and difficult urination. No diagnosis made pre-operatively; made during operation. Type.—Para.* Other structures strangulated with bladder—none. Bladder cut. Recovered.

CASE V.—(Dardinelli.) Female, aged fifty-two years; right side. Gastro-intestinal Symptoms.—Absent. Genito-urinary Symptoms.—Frequent and painful urination. No diagnosis made pre-operatively; made during operation. Type.—Extra.† Other structures strangulated with bladder—right Fallopian tube. Recovered.

CASE VI.—(Oliva.) Male, aged eight years; right side. Gastro-intestinal Symptoms.—Nausea and vomiting. Genito-urinary Symptoms.—None. No diagnosis made pre-operatively; made during operation. Type.—Extra.† Other structures strangulated with bladder—none. Recovered.

CASE VII.—(Wakeley.) Female, aged thirty-eight years; right side. Gastro-intestinal Symptoms.—None mentioned. Genito-urinary Symptoms.—None mentioned. No diagnosis made pre-operatively; made during operation. Type.—Intra.‡ Other structures strangulated with bladder—intestine. Bladder cut. Died.

CASE VIII.—(Wakeley.) Female, aged seventy-two years; right side. Gastro-intestinal Symptoms.—None mentioned. Genito-urinary Symptoms.—None mentioned. No diagnosis made pre-operatively; made during operation. Type.—Intra.‡ Other structures strangulated with bladder—omentum. Recovered.

CASE IX.—(Zintzmaster.) Male, aged fifty-four years; not stated which side. Gastro-intestinal Symptoms.—Absent. Genito-urinary Symptoms.—None mentioned. No diagnosis made pre-operatively; made during operation. Type.—Intra.‡ Other structures strangulated with bladder—none. Bladder cut. Recovered.

CASE X.—(Forques.) Male, aged seventy-two years; not stated which side. Gastro-intestinal Symptoms.—Fecaloid vomiting; inability to evacuate bowels or expel gas. Genito-urinary Symptoms.—None. No diagnosis made pre-operatively; made during operation. Type.—Not stated. Other structures strangulated with bladder—none. Recovered.

Totals.—Females, 7; males, 3; right side, 7; left side, 1; not stated, 2. Intestinal symptoms present, 6; absent, 2; not mentioned, 2. Urinary symptoms present, 3; absent, 4; not mentioned, 3. Correct Diagnosis.—None. Diagnosis made during operation, 10. Type.—Para,* 3; extra,† 3; intra,‡ 3; not stated, 1. Other structures involved, 4; bladder only, 6. Bladder cut, 5; not cut, 5. Recovered, 9; died, 1.

* Para—paraperitoneal.

† Extra—extraperitoneal.

‡ Intra—intraperitoneal.

BIBLIOGRAPHY

Abadie: Strangulated Femoral Cystocele. Bull. et mem. Soc., anat. de Par., 6th ser., vol. vii, pp. 617–619, 1905.

Alessandri, R.: Pathogenesis of Hernia of Bladder. Policlin., vol. viii, pp. 1–61, 1901.

Baricci, P.: Case of Strangulated Tubo-vesical Femoral Hernia.

Bevan, A. D.: Personal Communication.

Bumpus, H. C.: Personal Communication.

Cheever, D.: Personal Communication.

Dardinelli, M.: Strangulated Right Femoral Hernia Containing Fallopian Tube and Bladder; Pathogenesis and Mechanism of Strangulation. Riforma med., vol. xxvi, pp. 208–212, 1910.

Erdman, J. F.: Personal Communication.

Gallie, W. E.: Personal Communication.

Heyd, C. G.: Personal Communication.

Homans, J.: Personal Communication.

Horsley, J. S.: Personal Communication.

Laskownicki, S.: Incarceration of Bladder in Crural Ring. J. d'urol., vol. xviii, pp. 251–253, 1924.

Lahey, F. H.: Personal Communication.

LaRoque, R.: Personal Communication.

Lyle, H. M.: Personal Communication.

Moschowitz, A. V.: Personal Communication.

Tailhefer, E.: Strangulation of Femoral Cystocele; Fecaloid Vomiting. Proc.-verb., 14th Cong., Franc. de chir., Par., vol. xvi, pp. 583–586, 1901.

Wakeley, C. P. G.: Etiology and Treatment of Bladder Hernia; Forty Cases. Brit. Jour. Urol., vol. ii, pp. 1–14, 1930.

Zintzmaster, L. B.: Cases of Strangulated Femoral Hernia, Including Part of Bladder. Ohio Med. Jour., vol. ix, p. 407, 1913.

OSTEOMYELITIS OF THE SKULL *

By Ira Cohen, M.D.
of New York, N. Y.
FROM THE SURGICAL SERVICES OF THE MOUNT SINAI AND THE MONTEFIORE HOSPITALS

Excepting a paper by Fleming,[6] the recent literature on osteomyelitis of the skull is largely devoted to a discussion of instances complicating infections of the contiguous nasal sinuses. Fleming's paper deals with the post traumatic variety, only one of his eight cases having followed a sinus infection. Reports on the nasal sinus type of infection were collected by Lemere, 1923[8]; Bulson, 1925[5]; McKenzie, 1927[9]; and Munro, 1930.[10] McKenzie published a paper in 1913[9] which is the most detailed study written in English up to that time. He refers to a paper by Schilling[11] in which not only cases of sinus but also those of traumatic origin are discussed. Schilling points out that metastatic osteomyelitis of the skull secondary to a primary focus elsewhere in the body is rare (he refers to six reported cases), while the still greater rarity of a primary acute involvement of the skull such as is seen in the long bones is emphasized. He quotes one such primary case reported by Fischer,[7] and mentions two reported by Bergmann.[1]

This paper is based on thirteen cases of osteomyelitis involving the vault of the skull. Of these, seven cases followed infection about the nasal sinuses; two were metastatic; two may be classified as traumatic; in two the etiology was undetermined, and they may possibly be termed primary.

In six of the seven cases in which the osteomyelitis was secondary to infection in the nasal sinuses, a radical external operation had been done by a rhinologist before the patient came under my observation.

Case I.—Following an operation on the nose and a tooth extraction an extensive osteomyelitis of the frontal bone developed. This progressed up to the patient's death.

(Mt. Sinai Hospital No. 299551.) M. G., male, aged forty-four years, had a plastic operation on his nose three weeks prior to the onset of his present trouble. At the same time he had an abscessed tooth extracted from the right upper jaw, and claimed the cavity was irrigated through the nose. An abscess formed and was incised just below the right eye. Three weeks later another abscess was incised about the bridge of the nose, and after another three-week period a third abscess formed and was opened over the right frontal region. Drainage persisted from the first and third incisions. For several weeks he had had headache severe enough to keep him in bed most of the time. Four months after the nasal plastic and tooth extraction he entered the hospital. He denied having any fever or chills. He presented a discharging sinus over the right maxillary eminence and one in the righ eyebrow. There was a cold, soft swelling over the left frontal eminence, pressure on which caused pus to flow from the sinus in the right eyebrow. In his nose there were signs of a suppurative left ethmoiditis. His general and neurological examinations were negative, as were his fundi.

February 15 at operation Doctor Kramer found the nasal process of the frontal bones sequestrated and the outer and posterior walls of both frontal sinuses absent

* Read before the New York Surgical Society, October 31, 1932.

(either removed or sequestrated). The frontal bones were diseased for a distance of one and one-quarter inches from the mid-line and for four inches toward the coronal suture. The inner table of the skull was more diseased than the outer and the dura was covered with granulations.

The headache persisted, there were some personality changes, and three weeks after this operation he was transferred from the rhinolaryngological service to the surgical service, when it was noted that the deep reflexes on the left were a trifle more active than those on the right. At this time a beginning neuritis was noted in the right optic nerve. The signs were too meagre to warrant a diagnosis of brain abscess and the

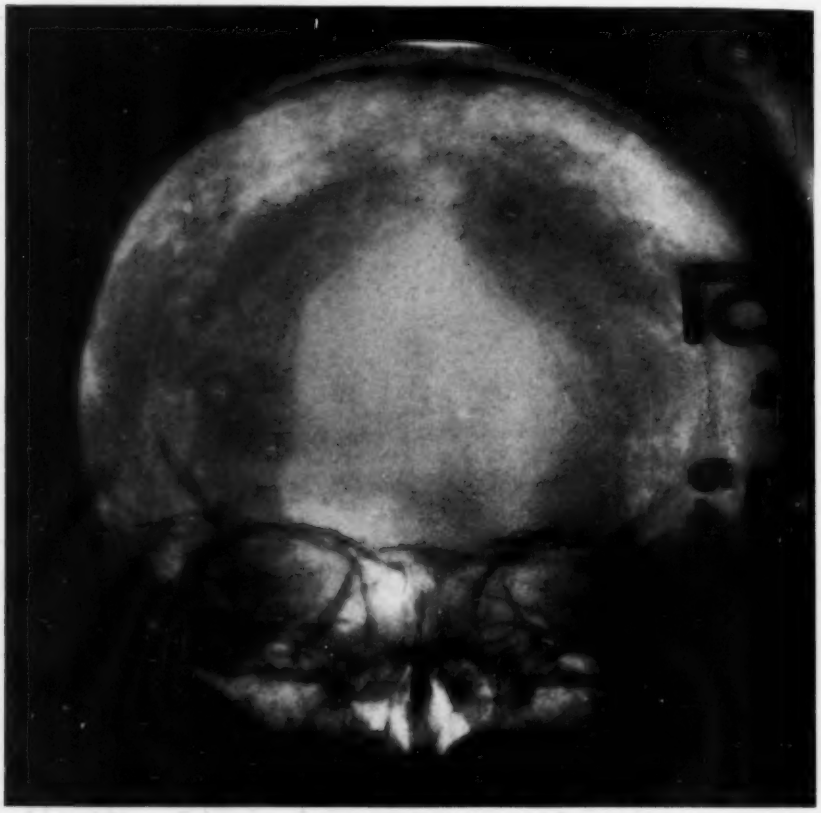

FIG. 1.—(Case I.) Röntgen appearance of skull after removal of large sequestrum of frontal bone.

patient was observed further. March 18 an abscess of the scalp to the right of the mid-line was opened and April 10 one to the left. The latter showed a small perforation through both tables. April 14 the incision on the right was extended to evacuate another pocket. The following day, through a trephine opening in a clean area on the right side, the brain was explored for an abscess. None was found nor was the brain under any increased pressure. A week later a lumbar puncture gave clear fluid under normal pressure. It contained four cells and no bacteria on spread or culture. April 30 the patient was very drowsy and the pulse rate had fallen to 60. By extending previous incisions on the right and left a sequestrum four by two and one-half inches was removed from the frontal bones. Granulation tissue but no pus was found beneath it. The dura was covered with granulations. After iodine had been applied to the dura

both frontal lobes were explored with a needle but no abscess found. The patient continued in stupor and died the following day. No necropsy was permitted. The pus from the various abscesses contained a *Staphylococcus aureus*. The röntgen appearance of the skull is seen in Fig. 1.

It cannot be definitely stated whether the plastic operation on the nose or the infected tooth was the starting point for the infection. The tooth was probably at fault as it was infected. Moreover, the first abscess appeared over the malar eminence which would not be the case were it a nasal infection. Without a post-mortem examination the exact cause of death cannot be stated. A brain abscess was probably ruled out by

FIG. 2.—(Case II.) Osteomyelitis mostly confined to right frontal.

the two explorations. A localized basilar meningeal infection may have been the terminal factor.

CASE II.—*Orbital abscess following ethmoid infection.* Positive blood culture. Osteomyelitis of skull. Recovery.

(Mount Sinai Hospital No. 269632.) A boy of five was admitted to the rhinolaryngological service July 20, 1926, because of swelling of the right orbit. This was of one day's duration and had come on following a rhinitis. The boy was very sick with a temperature which remained rather constantly around 103° for nearly two weeks. On one occasion it rose to 108°. Three external operations for a perforated ethmoidal infection and an orbital abscess were done during this period. A blood culture was

reported to contain *Staphylococcus aureus*. The pus from the orbital abscess contained the same organism with a *Staphylococcus albus*. A lumbar puncture disclosed clear fluid under increased pressure. A month after his admission tenderness developed over the right frontal area and an X-ray was suggestive of osteomyelitis of the frontal bone. (Fig. 2.) Two days later (August 27) an abscess was drained over the right frontal eminence. An erosion of about one centimetre of the outer table and somewhat less of the inner table was found. The necrotic bone was removed. Eighteen days later a second abscess near the coronal suture and more mesially was drained. The bone was found eroded to the dura, which appeared normal. Six weeks later a third incision was made between the other two and a small erosion of the outer table only was found. Two weeks later the boy was discharged with draining sinuses to the out-patient department to receive heliotherapy. A year later an abscess formed in the right upper eyelid. This opened spontaneously. It did not lead to exposed bone. X-ray failed to show a sequestrum or extension of the disease. The scalp wounds had healed. He was seen four months later with wounds healed and symptom-free.

This is the only patient in whom a positive blood culture was found. The signs of osteomyelitis of the skull were not manifest until more than a month after the onset of the illness. McKenzie distinguishes between an osteomyelitis that develops with the sinus infection and an osteomyelitis as a post-operative complication.

Case III.—An infant who entered the hospital with an osteomyelitis of the frontal bone developed a frontal lobe abscess and died after the drainage of this abscess.

(Mount Sinai Hospital No. 298910.) January 21, 1929, a nine-months-old infant was admitted to the hospital with a history that seventeen weeks previously she had had "a cold" for one day. The following day a swelling appeared over the right eye and her temperature rose to 105°. Following an incision in the right upper eyelid pus drained for three weeks. During this time the child developed pneumonia. A week after the incision in the eyelid stopped draining a swelling appeared over the right frontal region. For four weeks prior to admission there had been daily vomiting and for four days weakness of the left arm and leg. Examination showed a swelling in the right frontal region, a discharging sinus in the right eyelid, a left hemiparesis and normal fundi. The spinal fluid contained ninety cells, all lymphocytes.

January 24 an incision was made over the fluctuant mass on the forehead. After evacuating a few drops of pus several eroded areas were noted and in one of these a sequestrum was found. No pus was found between the bone and the dura. The entire exposed area was cleaned with tincture of iodine and the dura opened. The brain bulged into the opening but aspiration failed to find an abscess. Twelve days later a second abscess above and to the right of the first one was incised, and the previous operative site was revised. Sequestra were found in both situations. The temperature varied from 102° to 104°. February 23 a suppurative cervical adenitis was incised. The hemiparesis meanwhile improved. March 18 there was a rise in temperature to 104.2° and the child became stuporous. The right pupil was dilated and fixed; the left pupil was normal in size and fixed; the left arm and leg were moved freely. There was a bulge at the operative site which when aspirated disclosed pus. At operation a thick walled brain abscess was found at a depth of four centimetres and was drained by a tube. Following this the temperature rose to 107.8° and the child died. The pus from the brain abscess as well as that obtained from the superficial abscess contained *Staphylococcus aureus*. X-ray examination of the skull showed multiple areas of diminished density suggestive of an osteomyelitis. The post-mortem examination showed pus in the right ethmoid sinus, a drained right frontal lobe abscess with extensive area of softening about the abscess.

It is probable that the frontal lobe abscess was present but missed at the first search.

Case IV.—*Perforated frontal sinusitis.* Osteomyelitis of skull. Frontal lobe abscess. Recovery.

(Mount Sinai Hospital No. 299325.) A man, thirty-seven years old, was admitted

to the rhinolaryngological service February 3, 1929, with the history that for eight days he had headache and swelling about the right eye. These symptoms appeared two days after the onset of a cold. He had a temperature of 102.4° with a pulse of 72. There were œdema and redness about the right eye which was proptosed. Some œdema was present over the forehead above the orbital ridge. The eye moved with difficulty. Pus was seen in the nose. On the day of admission Doctor Kramer did a radical external ethmoid operation. Eleven days afterward abscesses were drained over the right and left frontal region. Meanwhile there developed slight papillœdema and some left facial weakness. An epidural or brain abscess was suspected. February 23 Doctor Kramer

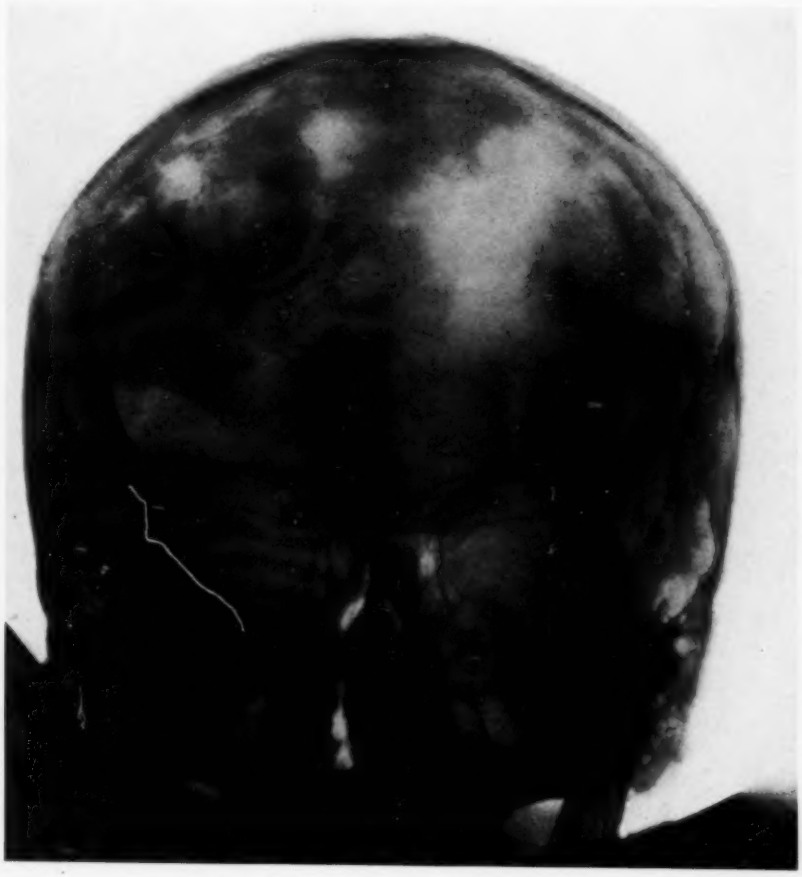

FIG. 3.—(Case IV.) Extent of involvement of frontal bones.

did a radical frontal operation and found necrosis of the floor and the posterior wall. There was an epidural collection of pus and a sinus track leading down to a frontal lobe abscess which was drained. Two weeks later the patient was transferred to the surgical service and the following day abscesses were opened over both right and left frontal regions, revealing eroded bone. On the left side there was a sequestrum and an epidural abscess. A large hernia cerebri developed in the right frontal incision and a cerebrospinal fluid leak occurred. A month after the frontal sinus operation, the patient developed a rigid neck and showed 3500 cells in his cerebrospinal fluid. These manifestations gradually cleared up. The hernia receded in part with some necrosis of the surface. A month later an osteomyelitic focus was drained near the mid-line anteriorly

and a second one over the occiput. These contained sequestra. In the next ten days there was considerable improvement and on June 2, four months after admission, the patient was discharged with three granulating sinuses of the forehead. Except for two shoots of temperature to 103° and 104° during this illness, the temperature did not arise above 101°. The pus from all abscesses and the sinus contained *Staphylococcus aureus*. X-ray of the skull is shown in Fig. 3. The patient still had (two years later) two small draining sinuses in the frontal region leading to exposed bone.

The infection in this case was a virulent one. The bone involvement was practically concomitant with the sinus infection. There was evidence of an osteomyelitis of the frontal bone at a considerable distance from the frontal sinus even before the operation on the sinus. The epidural abscess behind the posterior wall of the frontal sinus communicated directly with the frontal lobe abscess.

Case V.—*Acute frontal sinus infection.* Osteomyelitis of the frontal bone. Brain abscess. Drainage. Recovery.

(Mount Sinai Hospital No. 301267.) A boy sixteen years old was admitted to the rhinolaryngological service April 18, 1929, with a history of persistent headache for four weeks and swelling of the forehead for three and one-half weeks. These symptoms followed a cold. During the four-week period he had had two chills and his temperature had risen to 104°. He vomited the day of admission. On examination tenderness was found over the left frontal sinus and over the left frontal bone just about the hair line. The deep reflexes on the right were more active than those on the left. The fundi were normal. April 18 Doctor Kramer performed an external operation on the left frontal sinus; finding disease of the sinus and roughening of the posterior wall. When a small piece of the latter was removed normal dura was exposed. During the next ten days the boy was drowsy, complained at times of headache, and had a bradycardia. On the tenth day one diopter swelling of the optic discs was noted and the patient was transferred to the surgical service. The following day an abscess in the scalp just above the hair line and to the left of the median line was incised. This communicated with a perforation in the bone, and on removing more bone pus was seen coming from a pinpoint opening in the dura. This opening was enlarged and a drainage tube was placed into an abscess in the left frontal lobe. At the time of operation it could not be stated whether the tube had been placed into an intra- or extracerebral abscess. The introduction of iodized oil through the tube and X-ray studies proved the abscess to be intracerebral. (Fig. 4.) Following the drainage of the abscess there was an increase in the papillœdema for a few weeks. The patient was discharged from the hospital three months after operation. The pus from the frontal sinus and from the brain abscess grew a streptococcus. The patient was seen two years later at which time he was symptom-free and showed no neurological signs.

A single limited bone focus characterized the osteomyelitis in this case. The brain abscess lay directly beneath this diseased area and communicated with it. The exact location of the drainage tube was made certain by the use of X-ray with iodized oil. We have on several previous occasions made use of this method to determine whether a brain abscess was draining properly.

In 1920, Bryan[4] described the use of thorium nitrate as a contrast medium to determine whether an abscess he had drained was intra- or extracerebral.

Case VI.—*Acute frontal sinusitis, extensive osteomyelitis of skull.* Death. Postmortem—brain softening and meningitis.

(Mount Sinai Hospital No. 317794.) This fifteen-year-old boy gave no antecedent history of an upper respiratory infection. He stated that his symptoms began with left frontal headache three weeks prior to admission. For two weeks he had noted swelling about the left eye. His temperature had ranged about 103°. He appeared acutely ill. The left eye was completely closed by œdema of the lid and a large fluctuant swelling

extended from the eyebrow posterior to the coronal suture. The lesion was obviously a very advanced one. Operation was performed on the day of admission. One incision extended from the coronal suture to the eyebrow about four centimetres lateral to the mid-line, and a second incision was made over the posterior part of the parietal bone. There was a perforation in the bone posteriorly and some granulation tissue on the dura. Anteriorly diseased bone was removed and normal dura exposed. No epidural collection of pus was found. An orbital abscess was drained. A transfusion was given the next day, and the following day a radical external frontal sinus operation was per-

FIG. 4.—(Case V.) Showing drained brain abscess outlined with iodized oil.

formed by Doctor Myerson. The posterior wall of the sinus was found necrotic and there was some exudate on the dura. On the following day a one diopter swelling of the disc and a bilateral Babinski reflex were noted. The neck was spastic. A spinal tap withdrew bloody fluid which was not believed to be traumatic from the puncture. The cell count on the following day when the fluid was yellow showed 1,200 cells, no organisms in spread or culture.

A week after the first operation an exploration of the left frontal lobe for a brain abscess, through a separate trephine opening, was negative.

Two days later the temperature rose to 107° and a small collection of pus was

evacuated from beneath the dura in the left parietal region. The patient died the same day.

Post-mortem examination disclosed a hæmorrhagic type of bronchopneumonia. In the left frontal lobe was a cavity communicating with the ventricle. Miscroscopical studies showed the presence of a meningitis and extensive encephalomalacia of the left frontal lobe.

CASE VII.—*Chronic osteomyelitis of skull secondary to frontal sinus infection.* Persistent symptoms.

(Mount Sinai Hospital No. 310760.) At the age of eleven years this boy had an acute infection of the right frontal sinus for which an external operation was done. Two and one-half years later (January, 1930) he entered Mount Sinai Hospital. A

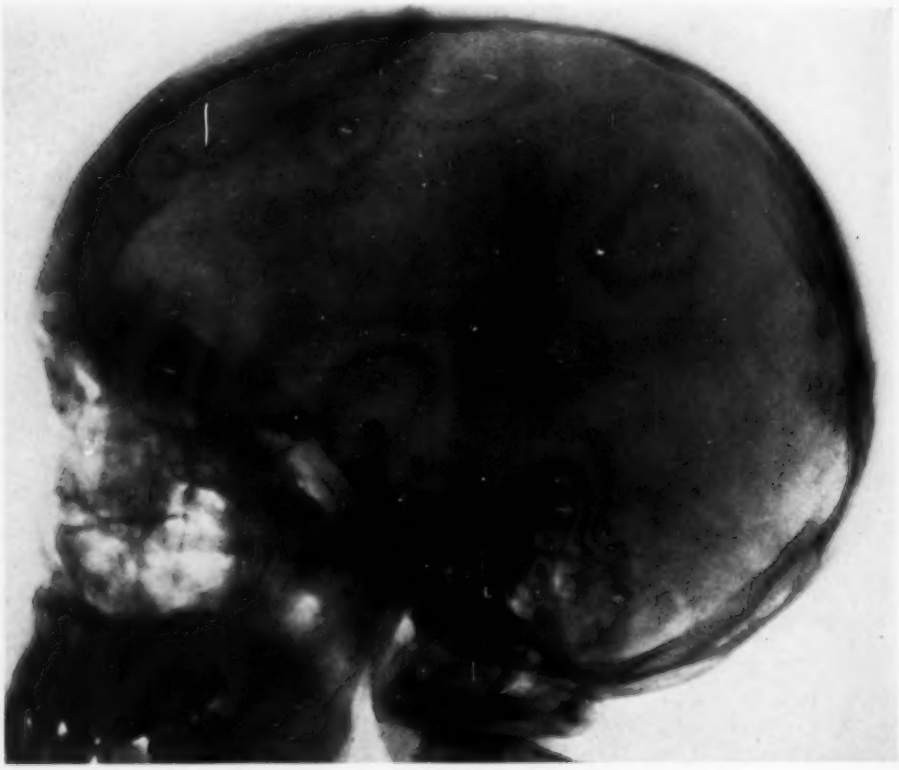

FIG. 5.—(Case VII.) Productive osteitis involving entire frontal bone.

painless swelling had appeared over the left frontal region which opened and discharged. The boy was of the Froelich type. He showed a scar in the right eyebrow of a frontal sinus operation. There was a diffuse fluctuant swelling over the right frontal region extending from the hair line to the bridge of the nose, and a small non-fluctuant fusiform swelling over the left eyebrow. In the left frontal region a small crusted area covered a sinus which did not lead to bone. Operation exposed the bone to the right of mid-line and over the left frontal region through separate incisions. No disease of bone was seen and culture of the pus was sterile. The operative findings were surprising. The X-ray of the skull (Fig. 5) showed a diffuse thickening of the vertical plate of the frontal bone. The report of the X-ray read in part "this thickening seems to be limited entirely to this particular bone. Its appearance is not suggestive of any familiar pathological condition. It does not have the appearance of lues, of tuberculosis,

of osteomyelitis, or of malignancy." A week after the operation the patient was discharged.

Nine months later he was readmitted (Mount Sinai Hospital No. 320665). A small sinus had appeared in the scar in the right eyebrow. There was fluctuation at the previous operative site to the right of the mid-line. He gave a history of swelling of the left eyelid which had disappeared with warm applications. The old incision was reopened, an excavation of the outer table of the skull was found. Soft bone was removed with a curette, dura was exposed and found normal. A staphylococcus was recovered from the pus. The patient was seen at follow-up clinic. Four months later there remained a draining sinus. An X-ray showed a further increase in thickness of the vertical plate and an increased thickness of the horizontal plate as well. A questionable area of rarefaction is seen in the lesser wing of the sphenoid.

The type of bone reaction seen in this case is most unusual. It is productive rather than destructive. It is limited to the frontal bone and involves the horizontal as well as the vertical plate. The process is still active and may lead to some intracranial complication. Radical surgery is out of the question as it would entail the removal of the entire frontal and sphenoid bones.

There is a marked similarity between the cases in this group. With the exception of Case I there is a history of sinus infection followed by the appearance of a swelling of the forehead about an inch above the eyebrow. Six of the patients had an orbital abscess. In only one was there a positive blood culture. Cases I and IV had massive bone destruction, large pieces of the frontal bone coming away as sequestra. Three patients died, two are still suffering from their osteomyelitis, one having draining sinuses, and one still presents from time to time the characteristic painless swelling in the scalp. This latter patient shows by X-ray a very marked reaction of the entire frontal bones which differs from the moth-eaten appearance of the skull in the other cases. Successive röntgenograms show a steady progression of this reaction. The process has spread to involve the lesser wing of the sphenoid and in one view there appears to be an area of rarefaction in that bone. Two patients are well and healed. Complicating brain abscess was found three times in this group, two patients surviving this complication.

Case VIII.—*Chronic osteomyelitis of skull from post-abortive sepsis.* Brain abscess drained fifteen years after onset of infection. Death two and one-half years later. Residual brain abscess, encephalomalacia of opposite hemisphere.

(Mount Sinai Hospital No. 267345, and Montefiore Hospital No. 16656.) Fifteen years before coming under observation in June, 1925, this forty-five-year-old woman had a sepsis following an abortion. Three years later a retro-orbital abscess and an abscess over the occiput had been incised and had healed. Four years before the present observation an abscess over the vertex of the skull opened spontaneously. This closed and opened numerous times in the four-year period. For two weeks she had had pain in the region of the abscess and persistent vomiting. At operation by Doctor Elsberg the sinus at the vertex was traced forward and to the right. A small epidural abscess and dura covered with granulations was found. Bone was removed until healthy dura was exposed. The operative wound healed. A year later the patient had a return of headache and became mentally dull. She had weakness of the left arm. Doctor Elsberg drained a right frontal lobe abscess. A hernia cerebri developed and the patient was left with a hemiplegia. Six months later she was admitted to Montefiore Hospital because of the hemiplegia. She died at that institution of subarachnoid hæmorrhage two years later. A post-morten examination showed subarachnoid hæmorrhage with

encephalomalacia on the left side. In the tip of the right temporal lobe a very small chronic abscess remained.

For a period of fifteen years the osteomyelitis of the skull, which was metastatic, ran a very benign course. All the foci healed except for one which made its appearance eleven years after the original infection.

CASE IX.—*Chronic sepsis following trauma.* Osteomyelitis of skull. Brain abscess. Death.

(Montefiore Hospital No. 13501.) A boy of twenty years was admitted to Montefiore Hospital November 10, 1924. He had the appearance and general development of a child of thirteen years. A röntgenogram of his chest showed a persistent thymus. Four years prior to his admission his left leg had been amputated above the knee following an injury to his knee. This was followed by an abscess on the outer side of the left hip which opened spontaneously and left a draining sinus. A similar sinus followed an abscess in the region of the left wrist. X-ray examination of the hip was interpreted as possibly tuberculosis, that of the wrist chronic osteomyelitis of the ulna with a sequestrum. Three months later a "cyst" was incised over the right frontal area. A month later an abscess was incised on the upper third of the left arm. In November, 1925, a year after his entrance into the hospital, he had a generalized convulsion. This was repeated three times in the next seven weeks. About this time a fluctuant mass was noted over the vertex of the skull, but X-ray failed to disclose any bone destruction. The patient now complained of headache. He vomited and the convulsions were repeated. Examination of the fundi showed a papillœdema, and a weakness of the right face and hand were noted. January 23, 1926, the abscess over the vertex was incised. A perforation of the skull was found in which lay a small sequestrum. The dura was thickened and covered with granulations. Bone was removed over an area of three centimetres until normal dura was exposed. During the next ten days the weakness of the right arm and face increased. February 2 a left parietal lobe abscess was drained. The patient gradually grew weaker and died April 6. Post-mortem examination was not allowed. The pus from the scalp abscess and brain abscess both grew a *Staphylococcus albus.*

The skull infection in this instance was a metastasis in the course of a low-grade sepsis from a *Staphylococcus albus.* The early painless swelling of the scalp should have been recognized as an abscess and indicative of underlying bone disease. It was not until a year later that the second abscess appeared, and with it the signs of intracranial involvement.

These above-mentioned two cases developed their osteomyelitis as metastatic foci. In one the lesion in the skull followed a post-abortive sepsis. Twelve years after the first sign of cranial involvement the osteomyelitis was still evident, and a brain abscess was drained. She lived for two years after this, dying of a terminal subarachnoid hæmorrhage on the opposite side. The other case had a chronic sepsis for five years before there was any skull involvement. The process here went on for a year before a brain abscess was manifest.

CASE X.—*Primary osteomyelitis of the occipital bone.* Discharging sinus for eight months. Sequestrectomy. Healing.

(Mount Sinai Hospital No. 307379.) A man of fifty-four was taken ill four weeks prior to his admission. The onset was with chills and fever followed by a burning pain in the occipital region which radiated to the back of both ears, and then localized and persisted on the left side. He presented a swelling and painful œdema just back of the left mastoid over the occipital bone. His temperature was 100.4°. The otological service called in consultation could find no evidence pointing to an otitic origin. The

fever rose by steps and on February 22, 1929, the fourth day after admission, a subperiosteal abscess of the left occipital region was incised. No diseased bone was seen. The temperature dropped promptly. A week later an X-ray of the skull was reported negative and at the end of another week the patient was sent to the out-patient department for dressings. The sinus persisted and X-ray five months later showed evidence of bone destruction in the occipital region.

Ten weeks later he was readmitted to the hospital. A fluctuant area mesial to the draining sinus was found. When this was incised a sequestrum the size and shape of a three-leafed clover was removed. The exposed dura was clean. Eight days later the patient was returned to the out-patient department for dressings. The wound healed promptly and when seen two years later had remained healed.

Except for the absence of extreme prostration, the onset of this illness was that of osteomyelitis elsewhere. The disease of the bone was close to the mid-line in the occipital region. The course was that of a well-localized focus. There was no tendency to spread and the condition cleared up promptly on the removal of a sequestrum which formed. This case may fairly be classified as a primary in the skull, in the sense that it did not originate in a contiguous sinus nor was it metastatic from a suppurative focus elsewhere.

Case XI.—*Osteomyelitis beginning in frontal bone and spreading back to the occipital bone.* Conservative operative treatment. Recovery.

(Mount Sinai Hospital No. 249069.) In November, 1924, an eighteen-year-old girl was admitted because of multiple abscesses of the scalp. There was no known etiological factor determined when fifteen months previously she was treated for osteomyelitis of the frontal bone in another hospital. Ten months later in the same institution further bone removal in the frontal region was carried out and an epidural abscess drained. Draining sinuses persisted. New abscesses appeared and the patient developed headache for which she was admitted. She had a low-grade papillœdema but no further neurological signs. Several sinuses over the frontal region led to bone and several unopened abscesses were present back of the coronal suture line. Her hæmoglobin was 58 per cent. During a seven months' stay in the hospital further abscesses appeared posteriorly over the occipital bone. As these appeared they were incised and necrotic bone was removed. Culture grew *Staphylococcus aureus.* At one time her hæmoglobin reached as low as 32 per cent. She received two transfusions. Vaccine therapy was tried. In June, X-ray was reported as showing extensive destruction of frontal and occipital bones. Heliotherapy was begun in the hospital and continued after her discharge in the out-patient department, for she still had many draining sinuses over the frontal and occipital region. She finally dropped out of sight but reported four years later with all wounds healed.

With no antecedent history of trauma, and in the absence of nasal sinus infection, it is possible that this patient may have had a primary bone infection. The records of this case are not explicit, but to my best recollection she had at one time as many as six or eight draining sinuses. The use of heliotherapy was, I believe, an important factor in the fortunate outcome.

In these two instances of undetermined origin, Case X seems possibly a primary infection such as is seen in the long bones. There is a history of local pain, chills and fever, followed by the appearance of a local osteomyelitic process in the occipital bone. This remained localized, and, following the formation and removal of a sequestrum, healed promptly. The history of the other patient is not clear. It fails to give any antecedent illness or trauma, but also fails to state any facts which could be interpreted as an acute onset. Broca[3] describes six cases of primary osteomyelitis of the skull, primary in

the sense that they were not extensions from contiguous infections, although several occurred in the course of infectious diseases. None of these cases originated in the frontal bone.

CASE XII.—X-ray treatment of epithelioma of scalp ten years previously. Trauma two years before admission. Osteomyelitis of skull, epi- and subdural abscesses. Sinus thrombosis. Death.

(Mount Sinai Hospital No. 283156.) A forty-eight-year-old man was admitted September 3, 1927, and died the following day. Ten years previously his scalp had been treated by X-ray for an epithelioma. Eight years later he received a severe blow at this site which resulted in ulcer formation. Biopsies of the ulcer failed to show any malignancy. A local osteomyelitis developed and four weeks prior to admission bone was removed disclosing a large epidural abscess. His temperature remained elevated and at times he was irrational. Blood cultures were repeatedly negative. His spinal fluid showed 125 cells and no organisms. A week prior to his admission there were no abnormal neurological findings. His temperature on admission was 103°. He was stuporous. There was a circular area of bare bone eight centimetres in diameter just posterior to the coronal suture, and in its centre a four-centimetre defect with dura exposed. There was an anæmia, and the deep reflexes were diminished. X-ray of the skull showed, in addition to the defect, the moth-eaten appearance of an osteomyelitis of the surrounding bone. At operation an extensive osteomyelitis was found and epidural granulations extending forward toward the left side. A subdural extracortical abscess containing about forty cubic centimetres of pus was drained. The patient died six hours after the operation in pulmonary œdema. The pus from the abscess was *Staphylococcus aureus.* A post-mortem examination showed a left epidural abscess, and left subdural extracortical abscess, thrombophlebitis of the cerebral veins and sinuses, a small brain abscess in the right temporo-parietal region, a right otitis media and a bilateral bronchopneumonia.

This case may be classified in the traumatic group. It is impossible to state what influence, if any, the epithelioma and the X-ray treatments had in addition to the trauma. The subdural abscess was large but well localized, as shown at post-mortem examination.

CASE XIII.—*Laceration of scalp.* Osteomyelitis of skull. Epidural abscess. Sepsis. Death.

(Mount Sinai Hospital No. 329558.) A twenty-eight-year-old man was admitted August 28, 1931. He stated that four weeks prior to admission he had fallen and sustained a laceration over the left frontal region. The wound seemed to heal kindly after suturing. Two weeks later, however, there was some pain at the site of the injury and the wound opened in part spontaneously and discharged pus. About this time there developed chills, fever and a throbbing headache. On admission the patient did not look sick in spite of a temperature of 104°. There was a swelling three centimetres above the left eyebrow and some œdema of that eyelid. From the centre of a six-centimetre scar at the summit of the swelling, pus was escaping through a small opening. The general physical examination was negative. On the day of admission the scar was opened widely to afford drainage. Bone denuded of periosteum was exposed but it appeared normal. There was an immediate drop in temperature following operation, but forty-eight hours later following a chill it rose to 105°. A blood culture was taken at this time. Two days later the patient was re-operated upon. It was thought that possibly an abscess deep to the temporal muscle had been overlooked. On extending the previous incision downward, a drop of pus was seen escaping from the bone just above the orbital ridge in its outer third. When an opening was made in the bone an epidural abscess was uncovered, overlying dura which was thickened and grey in appearance. Pus was seen in the bone. After the removal of bone over an area about six centimetres in diameter, normal bone was encountered toward the vertex, but though the removal was extended down to include part of the external angular process and greater wing of the sphenoid, the limit of disease

was not reached. The patient's temperature remained between 105° and 106° and he died two days later. The blood culture and the pus from the operative site contained a *Staphylococcus albus*. The post-mortem examination showed extensive osteomyelitis of the temporal, frontal, and sphenoid bones, a retrobulbar cellulitis, purulent exudate in the frontal and sphenoid sinuses, and a meningeal exudate localized over the frontal and temporal lobes at the site of the epidural collection of pus.

The widespread bone infection in this case was not secondary to a fracture. One must assume an infection of the diploic veins through a communicating branch, probably in the region of the supra-orbital notch, the source of the trouble being an infected hematoma at the site of the injury.

The grouping of the cases, as has been done in this paper, is purely an artificial one. The disease exhibits much the same characteristics in all the groups. McKenzie uses the term "spreading osteomyelitis of the skull" in writing of the cases following sinus infection, but it is just as applicable to any type. Fleming states that in children periosteal partitions may limit the process to one bone. In the infant, Case III, the disease was limited and though she lived only six months there was ample time for involvement of the contiguous bones. A characteristic of the spread of the disease is that the extension may show itself by an abscess often several inches distant from the last known focus. Thus if the first abscess makes its appearance over one frontal eminence, the second may appear over a corresponding point on the opposite side. These secondary abscesses often contain a small flake-like sequestrum, or show a small erosion of one or both tables of the skull without sequestra. Frequently the intervening bone to all appearances is normal, and subsequent events prove this to be so. This peculiarity is one argument in favor of the spread by means of thrombosis of the veins, at least in some instances. When there is mass destruction with the formation of sequestra, several centimetres in diameter, involvement of the entire diploe is probable.

When a scalp abscess is incised a little roughness of the outer table may be all that is found, or there may be a sequestrum, a flake of that table. At other times, especially when a perforation through both tables is present, the destruction of the inner table can be more widespread than the outer. It is in such instances that granulations cover the dura, or pus is found between the bone and dura. The pus here bears the same relation to the inner table that the abscess under the scalp bears to the outer, that is, a small collection of pus well localized to the operative site. This is not always the case, especially when there is extensive bone disease. A large epidural abscess may be encountered or a sinus track marked by granulations may lead from the site of perforation of the skull to a true epidural abscess several inches away. In some instances a perforation through the dura will disclose a subdural abscess. A brain abscess is more likely to occur than a large extracortical abscess. As McKenzie points out, the inflammatory reaction in the dura causes an agglutination of the dura and the subdural membranes. Brain abscess occurred as a complication in six of the thirteen cases in this series. Only Cases III and XII did not have an epidural collection of pus directly overlying the brain abscess. This suggests strongly that the brain

abscess in the other four cases resulted from direct extension In Case III the brain abscess finally appeared at the site of the skull perforation although there was no epidural collection. In Case XII there was a large subdural collection of pus on one side and at post-mortem a small brain abscess in the opposite hemisphere.

Bacteriology.—There are available data on the bacteriology in ten cases. In seven *Staphylococcus aureus* was grown from the pus, in two the *Staphylococcus albus.* A streptococcus was the organism in one case; it was recovered both from the site of the bone disease and from the brain abscess.

The *symptomatology* of osteomyelitis of the skull is largely that of its complications. The primary cases present malaise, or even prostration, local pain and fever. The onset of the secondary cases is often overshadowed by the picture of the nasal sinus involvement. After that condition is cared for, and in the absence of other complications, high fever is not the rule even with relatively widespread extension. The abscess of the scalp marking the site of an extension makes its appearance insidiously. It lacks heat and may not be particularly tender. Prior to its appearance the patient often complains of generalized headache. This same picture was found in the metastatic abscesses that appeared during a chronic sepsis. For the very reason that extensions of the disease take place without general manifestations and without subjective symptoms, they must be watched for constantly. The same holds true for the intracranial complications. For a time headache and lassitude may be the only signs of a brain abscess. Careful and repeated neurological examinations and eye-ground studies must be made on such patients.

The usual X-ray picture is that of a moth-eaten bone. Areas of rarefaction may be separated by several centimetres of normal-looking bone. With extensive disease these areas are close together. Sequestra are difficult to visualize, but may at times be seen. A productive process is usually not observed, but in Case VII there was noted an increased density of the frontal bone involving the horizontal as well as vertical plates and extending into the lesser wing of the sphenoid. This osteosclerosis is comparable to that seen in chronic osteomyelitis of the long bones.

The course of the disease, in the absence of brain complications, is usually long drawn out, and in that respect does not differ from osteomyelitis elsewhere. But because of the proximity to the brain and the dangers of intracranial complications, osteomyelitis of the skull has its own peculiar problems. Case VIII first showed evidence of skull involvement by an abscess of the scalp three years after her post-abortive sepsis. It was another twelve years before the symptoms of brain abscess were manifest. Thrombosis of the sagittal sinus was met with in Case XII, a traumatic case. Fischer (quoted by Shilling) reports sinus thrombosis as a complication thirty times in traumatic osteomyelitis. Blair and Brown[2] give one instance in forty-six collected cases. With the involvement of the veins in the diploe it is surprising that this complication is not seen more frequently.

Treatment.—When the source of the osteomyelitis lies in the nasal sinuses these must be cared for adequately by a rhinologist. This procedure was carried out in the seven cases of nasal infection in this series. From the standpoint of treatment of the osteomyelitis of the skull, the question arises, as stated by Blair and Brown,[2] whether to follow the plan advocated by McKenzie[9] or to adopt a more conservative method. McKenzie advises, in those cases arising from a nasal sinus infection, a wide removal of the frontal bone in an effort to go beyond the disease and prevent its spread. Blair and Brown make a plea for very conservative treatment. They collected thirty-seven cases with twenty-five deaths under radical measures, and nine cases with three deaths treated conservatively. The latter therapy consists in opening scalp abscesses as they arise and in the removal of sequestra as they may be found in these abscesses. Additional bone is removed when an approach is made to an underlying abscess. There seems to be some difference in the behavior and tendency to spread of primary osteomyelitis, and that associated with nasal sinus disease. The spread of the former is often limited. That infection from sinus disease may be just as limited is apparent in Cases III and V. The ultimate destruction of bone in these patients was limited to an area not larger than a ten-cent piece. Both of these patients developed frontal lobe abscesses beneath the site of the osteomyelitic process. The most widespread involvement occurred in Case XI, in which the etiology is not clear. There is no difference in spread directly traceable to the type of infecting organism. It may be that the answer is to be found in the virulence of the organism in question. Certainly in the two metastatic cases cited, the behavior of the infection was that of an attenuated organism. McKenzie makes a distinction between osteomyelitis which develops following a sinus operation, and that which is concomitant with the sinus infection. One would be inclined to believe this classification artificial (especially since the secondary type usually follows operation on the acute and not the chronically infected sinuses) were it not for the fact that McKenzie reported twenty cases of the post-operative type all ending fatally, while seven recoveries took place in the spontaneous group of twenty-one cases. Munro[10] recently made a careful analysis of 231 cases. His figures show a higher percentage of deaths occurred under conservative treatment, while in the recovered cases the percentages were more nearly equal, being slightly in favor of the conservative treatment.

In so far as the radical treatment means the removal of obviously diseased bone, it is rational. But the removal of bone *en bloc* in an effort to go beyond the disease and prevent its spread does not seem warranted. Since the spread of the process is by diploic channels, by the time the first localization shows itself in the typical swelling of the scalp, the infection may well have reached a place three or four or more inches distant to show itself by a similar swelling days later. This does not mean that the intervening bone is destroyed. Neither does the onset of an osteomyelitic process mean that of necessity there will be any spread. Case V is a good illustration of this. I, therefore,

take a middle course, if it can be called this, removing such bone as is grossly and obviously diseased. On the one hand one cannot be sure of preventing a spread by more radical removal *en bloc*, nor can one prognosticate which case will need it; on the other hand to leave bone oozing pus from its edges to await sequestration is inviting intracranial complications.

There were seven deaths in this series of thirteen cases. One death occurred two years after all symptoms referable to the osteomyelitis had subsided, and is included only for the sake of completeness. One patient died within twenty-four hours after coming under observation with a subdural abscess, a brain abscess and a sinus thrombosis. Three others died of brain abscesses. One patient died with an acute spreading osteomyelitis and a meningitis. The seventh death was not fully explained; it may have been due to toxæmia or an unproven basilar meningitis. Of the living patients two had brain abscesses. One of these still has an unhealed sinus leading to the skull. Three are perfectly well. The boy with the sclerosing type of osteomyelitis is an unfinished case.

Whether one studies a small series, as in this paper, or reviews a large number of cases, the seriousness of the disease is manifest. It threatens both from the standpoint of the bone involvement and from the extreme probability of intracranial complications. The insidiousness of its spread and of the onset of its complications make most careful observation imperative. One should be prepared for prompt action in a case that has gone along satisfactorily for months or years.

BIBLIOGRAPHY

[1] Bergmann, A.: Ueber Acute Osteomyelitis Speciell der Flachen Knochen. St. Petersburger Med. Woch., vol. i, pp. 381, 389, 1884.

[2] Blair, V. P., and Brown, J. B.: Septic Osteomyelitis of the Bones of the Skull and Face. Annals of Surgery, vol. lxxxv, p. 1, 1927.

[3] Broca, A.: Chirurgie Infantile, p. 330, 1914.

[4] Bryan, J. H.: Report of a Case of Extradural and Subdural Abscess Following Suppurating Frontal Sinusitis and Osteomyelitis of the Frontal Bone. Am. Jour. Med. Sci., vol. clx, p. 687, 1920.

[5] Bulson, A. E., Jr.: Osteomyelitis of the Frontal Bone as a Complication of Frontal Sinusitis. Trans. Am. Acad. Ophthal. and Otolaryng., p. 103, 1925.

[6] Fleming, H.: Osteomyelitis of the Skull. Calif. and West. Med., vol. xxiii, p. 985, 1925.

[7] Fischer, H.: Die Osteomyelitis Traumatica Purulenta Cranii. Deut. Zeit. Chir., vol. lvi, pp. 100, 449, 1900.

[8] Lemere, H. B.: Progressive Osteomyelitis of the Frontal Bone. Jour. Am. Med. Assn., vol. lxxx, p. 596, 1923.

[9] McKenzie, Dan.: Diffuse Osteomyelitis from Nasal Sinus Suppuration. Jour. Laryng., Rhinol. and Otol., vol. xxviii, p. 6; vol. lxxix, p. 129, 1913; Further Observations on Spreading Osteomyelitis of the Skull., Jour. Laryng. and Otol., vol. xlii, p. 293, 1927.

[10] Munro, D.: Non-traumatic Osteomyelitis of the Flat Bones of the Skull. South. Surg. Trans., vol. xliii, p. 403, 1930.

[11] Schilling, R.: Ueber die Osteomyelitis der Flachen Schadelknochen im Anschlusse an Entzündungen der Stirnhohle und des Mittelohres. Zeit. f. Ohrenheilk., vol. xlviii, p. 52 (Supplement), 1904.

THE USE OF CONTINUOUS INTRAVENOUS INFUSIONS IN ACUTE ABDOMINAL CRISES*

By Isidor S. Ravdin, M.D., and Charles G. Johnston, M.D.
of Philadelphia, Pa.

FROM THE DEPARTMENT OF SURGERY (DIVISION E) OF THE HOSPITAL OF THE UNIVERSITY OF PENNSYLVANIA

A REVIEW of the literature of some years ago on various types of acute abdominal crises will show that the clinician had focused his attention primarily on the method of operation, once the diagnosis of a surgical condition had been established. Within the past few years more attention has been directed at two other equally important measures, the pre-operative and the post-operative care, the adequate conduct of which bear a close relationship to the mortality of the lesion under consideration.

That water is a necessary component of all living cells is accepted by all biologists. In man it accounts normally for 70 per cent. of the body weight. The maintenance of good health demands that the cells be bathed in a fluid medium which normally remains remarkably constant in its organic and inorganic constituents. Any variation in the normal chemical constitution of the fluids bathing the cells vitally affects cell activity. Furthermore, cell activity is affected when the total water content is varied greatly in either direction from the normal.

As a result of an appreciation of these facts the clinician has focused his attention more and more on the fluid and salt requirements of the surgical patient. In few conditions is an appreciation of this subject more necessary than in the acute abdominal crises of an obstructive or suppurative character.

The disordered intestinal peristalsis prohibits the administration of fluids by mouth. Not only is ingested fluid vomited but in addition to this the fluids secreted into the gastro-intestinal tract may also be lost in large amounts. Thus, the many methods suggested for administering fluids through tubes placed in the stomach, gall-bladder or common duct are of no use in peritonitis, dynamic or adynamic ileus.

The withholding of an adequate fluid intake by mouth for a short period is not in itself dangerous. Simple restriction of fluid intake is usually partially compensated for by a restricted loss. Such a state of mild dehydration can, if no contra-indications exist, be corrected by the simple ingestion of water. The severely ill, dehydrated patient, however, presents another problem.

The loss of fluid from intestinal fistulæ or by vomiting is associated not only with water loss but also with a loss of various salts. The restriction of food intake during the period of acute illness when oral feeding is impossible, or contra-indicated, results in a further drain on the tissue stores of the

* Read before the Philadelphia Academy of Surgery, October 3, 1932.

body. It, therefore, becomes a problem of major importance for the successful outcome of the case to consider not only the simple water balance, but also the metabolic and the chemical balance of the patient. Indeed, it is impossible in patients of the type under discussion to separate these three factors. In the majority of instances of vomiting, the major ions lost are sodium, chloride and bicarbonate. The persistent loss of these ions ends in a disturbance of the acid-base balance so that the environment of the cells is no longer a normal one. Whether the final condition is one of alkalosis or acidosis depends on the degree to which acid or base ions are lost. The restricted intake of carbohydrate at a time when body tissues are being rapidly broken down may result in an associated ketosis.

The storage of tissues in the body necessitates fluid. The breakdown of tissues results in a liberation of water and the loss of water from tissues undoubtedly results in tissue breakdown. The dehydration so frequently observed in these cases causes an increased viscosity of the blood, added work on the heart with a tendency to a reduction of the blood-pressure; a decrease in the oxygenation of tissues; a disturbance of the heat-regulating mechanism which in turn aggravates the dehydration by increasing the loss of water by evaporation and sweating. Associated with these disturbances is a restriction of kidney output and a piling up of certain metabolites in the blood which in themselves detrimentally affect cell activity.

Under normal conditions the saliva, gastric juice, bile, pancreatic secretion and succus entericus account for as much as 7,000 to 8,000 cubic centimetres of fluid entering the gastro-intestinal tract per day. When it is considered that these fluids contain salts and that in part the salts and nearly all of the fluids are reabsorbed together with those ingested before the fæces are expelled, it is easy to realize what a highly important part the intestine plays exclusive of the part it takes in the absorption of foods.

When, therefore, it is impossible to take fluids by mouth and when added to this there occurs an actual loss of fluid and salt by vomiting, the successful outcome of an operation may depend upon a partial restoration of the fluid and salt balance previous to operation and its maintenance thereafter. In the simple surgical case the loss of fluid may be considerable but in an illness of short duration the water stores in the skin, subcutaneous tissue and muscle may not be exhausted. It is in the bad-risk case, whose easily available water stores have been depleted, that an adequate consideration of the biological requirements of the individual is essential.

In a discussion of fluid balance, where the disease is of short duration, it has been a practice to measure the intake of fluid, by any route, and to compare this with the loss through the urine and any other directly and easily measured route, as for example the vomitus. This comparison, however, is not accurate since it fails to take into account the insensible loss of fluid and that lost by sweating. In the very sick patient and especially in the suppurative abdominal cases, in which vomiting or regurgitation is a prominent and persistent feature, one must also take into consideration the insen-

sible loss of water and solids as well as that lost through other channels. These patients who only too frequently have dilated peripheral capillaries, whose skin is more often than not leaking considerably, may, as Wiley and Newburgh[1] have pointed out, lose more fluid through the skin and lungs than through the kidneys. Recently, Coller and Maddock[2] have reëmphasized this factor in a study of surgical patients. To depend solely on the sensible loss of fluid may result in a fluid intake far too small for the basic requirements of the patient. The insensible loss of water through the skin and lungs may, as Wiley and Newburgh[1] have shown, vary from 1,000 to over 3,000 cubic centimetres per day and this does not include that which is lost by sweating.

Fortunately, we have at our disposal simple methods for determining the salt and fluid requirements of the patient. The determination of base is unnecessary, while that of chloride and urea nitrogen and occasionally of bicarbonate is important. These substances, plus a careful study of the urine for ketone bodies, will in nearly every instance give the chemical data which the surgeon requires for treatment.

The existence of dehydration can often be determined by the texture of the skin and mucous membranes. Daily hæmoglobin estimations are also of considerable value and if to these is added the determination of the plasma protein we have as a rule all the information necessary. Recently, Dolch and Poechmuller[3] have described a simple method for determining the water content of blood and serum and it may if it continues to prove satisfactory be added to the above studies. If simple intake and output studies are depended upon, an adequate amount should be added to the intake to compensate for the insensible loss and the loss through sweating.

In patients with acute abdominal crises only three routes for the administration of fluid are available—the rectal or colonic, in which we include the administration of fluid through a cecostomy, the subcutaneous, and the intravenous. The method adopted must consider the fluid, the salt and the metabolic requirements of the patient.

It is rarely possible in acute abdominal crises to administer sufficient fluid by proctoclysis over a prolonged period to maintain basic requirements. Furthermore, the introduction of large amounts of fluid may not only be poorly tolerated but may set up peristalsis which other treatment is attempting to overcome. Where the indications exist for the rapid introduction of fluid as in a short pre-operative period the time limitations preclude its use. And lastly, where it is also advantageous to give glucose along with water and sodium chloride the total amount of glucose which can be absorbed from the colon in any concentration is too small, as Ebeling[4] and others have shown, to be of any material value.

The method of subcutaneous injection has many advocates. The fluid may be given intermittently or continuously. Large amounts of normal saline can be introduced by either method. The use of glucose even in low concentrations, by this method, is not without danger to the tissues. The method even when used as advocated by Bartlett is not painless. Febrile

reactions of moderate or severe grade frequently follow its prolonged use as the tissues react to the continued injury. In the presence of a failing circulation fluid is not absorbed in appreciable amounts.

About eleven years ago, Dr. George P. Muller and one of us began the sporadic use of continuous intravenous infusions in certain of our bad-risk abdominal cases. We were favorably impressed with its possibilities but our set-up was not very good, and, what was more important, we were discouraged by the high percentage of post-infusion reactions. Nevertheless, we continued to use the method from time to time.

In the meantime, other surgeons had written on the usefulness of the method. Matas,[5] Penfield and Teplitzky,[6] Hendon,[7] Horsley[8] and others have published data which supported the contention that in certain instances the method is superior to any other. In 1929, we began to reinvestigate the subject and adopted a method which is a modification of that used in the Presbyterian Hospital in New York. Intravenous reactions still discouraged us and it was not until Rademaker,[9] following the investigations of Florence Seibert,[10] conducted a series of studies and revised our technic for preparing the solutions that the method has shown its true worth.

The assurance that the fluid enters the blood-stream at a predetermined rate, which will not tax an embarrassed circulation, increasing evidence that the absorption of material amounts of glucose by the rectum and colon is not possible, and the ease with which posture can be changed if the proper technic is utilized, have all contributed to make this method increasingly popular.

In the vomiting associated with peritonitis and adynamic ileus the blood composition is practically the same as that seen in high intestinal obstruction. These patients frequently have an actual alkalosis from the prolonged loss of chloride in excess of base. The frequent diagnosis of acidosis in these cases merely because of the presence of acetone and diacetic acid in the urine is incorrect. The intravenous administration of sodium bicarbonate to such cases is reprehensible. It is just as possible to have alkalosis with ketosis as acidosis with ketosis and it should be remembered that the number of cases of true acidosis which the surgeon sees is indeed few.

We believe that when fluids are given intravenously the constant slow drip is more satisfactory than the rapid introduction of large amounts which result in the activity of certain types of cells which ordinarily are not called upon to play a part in the process of adjusting to ingested fluid. Swale Vincent[11] has demonstrated that the transitory fall in blood-pressure which may accompany intravenous injections of saline is more rapid the greater the rapidity of the injection. When the infusion is given slowly the circulation is not further suddenly taxed by a large amount of fluid rapidly injected.

There are as yet certain theoretical disadvantages of the method even when carried out by the best technic. We as yet know very little of the changes which occur in the individual tissues secondary to the changes induced in the blood. These would appear to vary with differences in renal

or hepatic function, the presence or absence of fever, the recent history of the organism with respect to water and salt balance, the influence of drugs and perhaps other undetermined factors. Data concerning these changes are still scanty and generalizations are premature. Nevertheless, clinical experience has shown that in certain pathological conditions its value has been established. Each extension of this field of therapy should, however, be considered as an experiment and should be conducted with due caution.

The important thing to remember in dehydration in the cases associated with continued vomiting, whether there exist alkalosis or acidosis, with or without ketosis, is that it is much more important first to correct the dehydration as Gamble and his coworkers[12] have shown than it is to attempt to correct blood reaction. The keystone of the situation is a properly functioning kidney. Given this, normal sodium chloride will correct the dehydration and at the same time correct blood reaction. Ketosis in the acute abdominal crises usually can be corrected by the simultaneous administration of glucose. In alkalosis, base will be eliminated and chloride retained and in acidosis base will be retained and chloride eliminated following the administration of sodium chloride. The use of sodium bicarbonate is only rarely indicated. Unless the depletion of bicarbonate is extreme, a condition which as a rule is rare in surgical practice, sodium chloride will provide the base or acid ions necessary. Gamble,[12] whose studies have done much to enlighten this subject, has used sodium bicarbonate in certain cases of nephritis in children but even here its use was of little value.

If there exists an impairment of renal function the introduction of hypertonic glucose solution should precede the infusion of sodium chloride, so as to stimulate renal activity.

With this method, the control of dehydration, as met in cases of the type under discussion, is relatively simple as far as the solutions to be used are concerned. There may be advantages in the use of Ringer's solution as practiced by Horsley,[8] but we have found that sodium chloride is quite satisfactory. The glucose as a rule is used in a 5 per cent. concentration in the saline. If additional glucose is desired the concentration can be increased.

The amount of fluid administered varies with the individual case but in the majority of instances it has, in our cases, approximated from 3,000 to 3,500 cubic centimetres in twenty-four hours. We have, however, in patients who were vomiting very large amounts and whose loss through the skin was considerable, had to give as much as 7,000 cubic centimetres in a twenty-four-hour period. With a 3,000-cubic-centimetre intake, 150 grams of glucose are given the individual in a day. This, of course, provides a very low caloric value to a patient whose metabolic rate is speeded up by infection, but it spares the tissues to a really amazing degree.

In only the rarest of instances is a cannula placed in a vein. Generally a No. 22 Luer needle which is perfectly clean is used. The flask containing the solution is placed on a high stand. Into the flask is placed a piece of rubber tubing which is fastened to a bent glass tube. This is connected

to a piece of tubing which in turn is connected to a glass tube which passes through a rubber stopper fitting into the barrel of a twenty-cubic-centimetre Luer syringe. The tip of the syringe has rubber tubing attached to it, into the other end of which is fitted a Luer adapter. The syphonage is started by suction and the rate regulated by a Hoffman clamp. A Luer syringe is used to make sure that the needle is in the vein and then the adapter is connected to the needle and the system functions. Small adhesive straps fix the needle and a portion of the tubing to the forearm or leg, depending on the vein that is used. The extremity is then enclosed in a pillow for immobilization. The solutions we have used are not heated above room temperature. It is true that the temperature of the solution is slightly elevated as it slowly flows through the rubber tubing fixed to the arm and enclosed in the pillow. This is accomplished by the patient's own heat. The actual heat expended in heating the solution once it enters the vessel is when calculated per hour of time infinitesimal when compared to the heat lost by surface irradiation during the same time period. Furthermore, since many of these patients have a marked elevation of the temperature the introduced fluid assists in a minor degree in reducing the body temperature.

The system will frequently function for twenty-four hours or more without changing the needle. Thrombosis of the vein occasionally occurs. We have never had infection of the soft parts result after the use of the method, although we have continued the method for as long as twenty-one days using at alternate periods the veins in either anticubital fossa. The position of the patient can be changed at will. The method causes no pain unless the needle slips out of the vein. We are convinced that it offers advantages which cannot be obtained by any other means. With this method the inorganic constituents of the blood, especially chlorides and base, can be maintained at normal or nearly normal levels over a long period. The occasional use of hypertonic glucose solution to stimulate kidney activity will tend to reduce the increase in urea nitrogen which is so frequently elevated in these patients. If the kidneys have been previously damaged one must be cautious in the use of large amounts of saline since salt retention may result. In such cases glucose in distilled water should be used as the major fluid and the saline given in amounts which can be readily handled.

The plan which has been outlined cannot be used as a routine procedure. Each patient must be studied during the progress of the disease and the fluid, salt and caloric requirements must be adjusted to meet the exigencies of the case.

Case Reports—Case I.—*Diagnosis.*—Acute intestinal obstruction, A. S., female, aged thirty-nine years. Sixty-six hours before admission she was seized with sudden severe pain in the right lower abdomen. The site of this pain was an incisional scar the result of a laparotomy performed nine years previously at which time she had a salpingo-oöphorectomy, appendectomy and cholecystectomy. Soon after the onset of the pain she began to vomit and this continued until the time of admission, at which time the vomiting was fecal in type. The patient was semi-comatose, her skin was dry and the tongue was parched and coated.

Systolic blood-pressure, 100 mm. of mercury; diastolic, 88 mm.; pulse, 140; temperature, 99° F.; respiration, 38; hæmoglobin, 118 per cent.; white blood-cells, 6,700. Abdomen markedly distended. Peristalsis loud and tinkling.

A Jutte tube was passed into the stomach and 1,120 cubic centimetres of dark brown, fecal-smelling material were removed. A continuous intravenous drip was established and the patient was given 1,000 cubic centimetres of 5 per cent. glucose in normal saline. She was taken to the operating room with the Jutte tube in place and the intravenous drip continuing to flow. She was so drowsy that she would not respond to questions. We decided that spinal anæsthesia would permit of a more rapid operation with less trauma. She was given fifty milligrams of ephedrine sulphate about twenty minutes before introducing the anæsthetic and fifty milligrams more just previous to the introduction intrathecally of 150 milligrams of neocaine. Within twenty minutes it was impossible to record either the systolic or diastolic pressure. Adrenalin injected subcutaneously did not prevent the fall and she was thereupon given 310 cubic centimetres of 10 per cent. glucose and three minimums of adrenalin intravenously when the blood-pressure slowly began to return.

Exploration of the abdominal cavity disclosed a dark reddish-blue loop of ileum which was caught under a broad adhesion extending from the abdominal wall to the uterus. The adhesion was resected and the loop freed, whereupon the color of the intestine improved rapidly.

An enterostomy was performed just proximal to the site of the obstruction and 300 cubic centimetres of fluid were immediately drained into a receptacle. The intravenous drip was continued during the operation and at the time of closure of the wound the systolic pressure was 160 and the diastolic pressure ninety millimetres of mercury. Her pulse was 120 at this time.

During the first eleven hours she received 3,500 cubic centimetres of 5 per cent. glucose in normal saline. It was only then that the plasma chlorides were estimated. These were found to be 5.28 grams per liter. The loss of fluid from the Jutte tube, enterostomy and through the kidneys amounted to 3,350 cubic centimetres. At this time the patient was conscious and could answer questions rationally.

In the succeeding twenty-four hours she received 4,450 cubic centimetres of 5 per cent. glucose in normal saline by intravenous drip and had an output of 2,065 cubic centimetres exclusive of the insensible loss and the loss through sweating.

She began to perspire freely so that in the following twenty-four hours she was given a total of 5,690 cubic centimetres, 3,800 cubic centimetres being 5 per cent. glucose in normal saline and 1,890 cubic centimetres normal saline without glucose. Her visible output during this period was 3,335 cubic centimetres. The hæmoglobin under this therapy dropped to 75 per cent. and the plasma chlorides rose to 6.15 grams per liter. Her condition improved rapidly.

On the third post-operative day the urine output increased to 1,920 cubic centimetres and the Jutte tube drainage was only 100 cubic centimetres. She drained 850 cubic centimetres from the enterostomy tube. Forty-five hundred cubic centimetres of 5 per cent. glucose in normal saline were given during this period by the continuous intravenous drip. On the fourth day she had a normal stool and fluids were begun by mouth, the intravenous drip being discontinued. She subsequently made an uneventful recovery.

Case II.—*Diagnosis.*—Acute appendicitis with peritonitis. A. G., male, aged fifteen years. Seventy hours previous to admission he complained of pain around the umbilicus for which he was given a cathartic. His pain subsided during the day but then became more acute and he began to vomit. He continued to vomit and became feverish, but was given another cathartic. His symptoms increased and on the third day after onset he was admitted to the University Hospital.

The facies were anxious. The skin and mucous membranes were extremely dry. Respiration was rapid and shallow and there were no abdominal respiratory move-

ments. The abdomen was distended, rigid and tender throughout. Peristalsis was barely perceptible.

Temperature, 105° F.; pulse, 134; respiration, 34. White blood-cells, 14,000; hæmoglobin, 97 per cent. Plasma chlorides were 4.86 grams per liter.

Operation was under nitrous oxide and oxygen anæsthesia reinforced with ether. Through a McBurney incision a perforated, gangrenous appendix and 800 cubic centimetres of pus were removed from the abdominal cavity. Drainage was established and the wound closed. A pure culture of *B. coli* was obtained. He was given 750 cubic centimetres of normal saline to which forty grams of glucose were added during the progress of the operation.

In the twenty-four hours following operation he was given 1,350 cubic centimetres of normal saline and seventy grams of glucose by intravenous drip. On this day he showed ketone bodies in the urine. During this period we were troubled with frequent post-infusion chills so that an additional 600 cubic centimetres of normal saline were given by hypodermoclysis. The plasma chlorides rose to 5.50 grams per liter. The sensible output was 1,000 cubic centimetres. On the following day he was given 1,500 cubic centimetres of normal saline and 5 per cent. glucose. The intravenous drip was continued for twenty-four more hours at which time he was markedly improved.

On the seventh post-operative day he began to vomit and on the tenth post-operative day a jejunostomy was performed for obstruction. The plasma chlorides dropped to 4.74 grams per liter. He was given 1,500 cubic centimetres of normal saline and 1,500 cubic centimetres of 5 per cent. glucose in normal saline intravenously. To this was added 2,000 cubic centimetres by mouth which could be syphoned through the Jutte tube. The total sensible output was 4,800 cubic centimetres.

On the second day after the jejunostomy he was given 3,300 cubic centimetres of 5 per cent. glucose in normal saline, 750 cubic centimetres of normal saline by proctoclysis and 750 cubic centimetres of water by mouth. The total sensible output was 3,300 cubic centimetres. The plasma chlorides rose to 6.30 grams per liter on the third post-operative day.

On the nineteenth day after the appendectomy he developed a second obstruction with persistent vomiting, necessitating an ileostomy. At this time the intravenous drip was reëstablished. He was given 3,000 cubic centimetres of 5 per cent. glucose in normal saline during the first twenty-four hours. The plasma chlorides were 5.60 grams per liter on the day after the second enterostomy. He was given 2,500 cubic centimetres of 5 per cent. glucose in normal saline on both the second and third days after operation. The plasma chlorides at this time were 6.08 grams per liter. During this period he, on three occasions, had ketone bodies in the urine for which additional glucose was intermittently administered. His condition rapidly improved and he was discharged fifty days after the initial operation.

BIBLIOGRAPHY

[1] Wiley, F. H., and Newburgh, L. H.: Jour. of Clin. Investigation, vol. x, p. 723, 1931.
[2] Coller, F. A., and Maddock, W. G.: Jour. of Am. Med. Assn., vol. xcix, p. 875, 1932.
[3] Dolch, M., and Poechmuller, E.: Hoppe-Seyler's Ztschr., vol. cxcv, p. 28, 1931.
[4] Ebeling, W. W.: Arch. of Surg., vol. xxvi, p. 134, 1933.
[5] Matas, R.: Annals of Surgery, vol. lxxix, p. 643, 1924.
[6] Penfield, W. S., and Teplitsky, D.: Arch. of Surg., vol. vii, p. 111, 1923.
[7] Hendon, G. A. M.: Med. Arts and Indianapolis Med. Jour., vol. xxxiv, p. 491, 1931.
[8] Horsley, J. S., and Horsley, G. W.: Arch. of Surg., vol. xxii, p. 86, 1931.
[9] Rademaker, L.: Annals of Surgery, vol. xcii, p. 195, 1930.
[10] Seibert, F.: Amer. Jour. Physiol., vol. lxvii, p. 90, 1923.
[11] Vincent, S.: Jour. Pharm. and Exper. Therap., vol. xxxvi, p. 107, 1929.
[12] Drake, T. G. H., Marsh, P., and Gamble, J. L.: Amer. Jour. Dis. of Children, vol. xl, p. 705, 1930.

TROPACOCAINE HYDROCHLORIDE IN SPINAL ANÆSTHESIA

OBSERVATIONS BASED ON ONE THOUSAND OPERATIONS

By Joseph A. Lazarus, M.D., Chas. J. Pick, M.D., and
Arthur A. Rosenthal, M.D.
of New York, N. Y.

This contribution is based on the use of tropacocaine hydrochloride in 1,000 cases of spinal anæsthesia. It is submitted with the view of placing on record our experiences with this product, to point out its advantages in urological and general surgery and to present a technic which in our hands has given most satisfactory results.

A satisfactory preparation for the induction of spinal anæsthesia must have a low toxicity, be soluble in small quantities of water or spinal fluid, and not decompose when sterilized. Tropacocaine hydrochloride was found by us to fulfill all of these requirements.

The committee on therapeutics of the British Medical Association has recently conducted experimental investigations of the various drugs used for spinal anæsthesia, and found tropacocaine hydrochloride to be satisfactory and safe.

The term "spinal anæsthesia" is really a misnomer, since no actual anæsthesia of the spinal cord takes place. What does occur is an extensive regional nerve block. Although we may use the words interchangeably in this paper, the process is one of spinal analgesia.

History.—Tropacocaine (benzoyl pseudotropeine) was first isolated by Giesel in 1891 from Javanese coca leaves. Liebermann was later able to successfully synthesize tropacocaine, while Willstätter produced it from tropine.

The physiological effects of tropacocaine hydrochloride were studied by A. P. Chadbourne,[1] in 1892, who found it to resemble cocaine in its physiological properties. Experimentation by Chadbourne showed it to be a powerful local anæsthetic, similar in action to cocaine, but differing from it in the following respects:

(1) Tropacocaine is much less toxic than cocaine. (2) The depressant action on the heart is less. (3) Anæsthesia is more complete and lasting. (4) Cocaine produces ischæmia while tropacocaine gives rise to an evanescent hyperæmia. (5) Tropacocaine solutions are slightly antiseptic and retain their strength for a period of at least six months. Cocaine solutions are less stable, retaining their strength for a much shorter period. (6) The relation between toxicity and dosage is more constant with tropacocaine than with cocaine. (7) Recovery from the effects of tropacocaine is much more rapid.

The first mention of the use of tropacocaine in spinal anæsthesia was made by K. Schwartz,[2] in 1901, who strongly advocated its use in place of

cocaine and eucaine. Acting upon his suggestion, Meyer,[3] Neugebauer,[4] and Kopfstein,[5] used tropacocaine and found decided advantages over other preparations used for spinal anæsthesia.

Physiological and Pharmacological Properties.—Tropacocaine Hydrochloride Merck is an alkaloidal salt having the formula $C_8H_{14}NO.C_6H_5CO.HCl$, and occurs as colorless crystals readily soluble in water. It destroys the vasoconstrictor action of epinephrine. Its toxicity is stated by Sollmann[6] to be one-half that of cocaine. The preparation used by us is in the form of a 10 per cent. solution of tropacocaine hydrochloride Merck in an 0.6 per cent. sodium chloride solution. Commercially it is supplied in 5 per cent. and 10 per cent. solution ampuls of one cubic centimetre each, sterile, and hermetically sealed, ready for administration. The solution is colorless, and is easily drawn up into the syringe through a needle of any gauge. In this respect it is decidedly more advantageous than other spinal anæsthetics, because of the facility of administration without resorting to the necessity of dissolving any crystals in an ampul with spinal fluid.

Tropacocaine, like other spinal anæsthetics, produces a physiological block of the nerve roots when the solution comes in contact with them. It primarily produces a block of the posterior or sensory roots and to a lesser degree the anterior ones. The extent of involvement depends chiefly upon its diffusion, which in turn is dependent on the dosage, the level of injection, the force with which it is injected and the individual susceptibility of the patient. Tropacocaine is excreted chiefly through the kidneys.

Duration of Tropacocaine Anæsthesia.—The duration of anæsthesia depends upon the strength of the solution and the dosage employed. In the majority of our cases (intra-abdominal operations) one and one-quarter cubic centimetres of a 10 per cent. solution were used, and gave an average duration of the anæsthesia of from one hour to one and one-quarter hours. For more extensive operations one and one-half to two cubic centimetres were used, which prolonged the anæsthesia to two hours. For extra-abdominal operations, the larger doses are unnecessary, as anæsthesia produced with one cubic centimetre lasts fully an hour.

Selection of Patients for Tropacocaine Spinal Anæsthesia.—We were guided in the selection of our patients for spinal anæsthesia by the type of operation to be performed, the age and the physical condition of the patient. The same careful evaluation of the risk involved must be made as with general anæsthesia. In most operations below the diaphragm, tropacocaine hydrochloride intraspinally was the anæsthesia of choice.

Among the types of operative procedures conducted in this series of 1,000 cases were the following: prostatectomy, orchectomy, plastic operation on the penis, varicocele, plastic repair of vagina, ectopic gestation, salpingectomy, oöphorectomy, hysterectomy, plastic repair of urethra, appendectomy, intestinal resection, herniotomy, suprapubic cystotomy, nephrectomy, pyelotomy, nephrotomy, ureterotomy, cholecystectomy, cholecystoduodenostomy, gastro-

enterostomy, gastrectomy, excision of hæmorrhoids, operations for osteomyelitis and reduction of fractures.

Indications for the Use of Tropacocaine.—We have found tropacocaine particularly useful in the following classes of operations and complications:

(1) *Intestinal Obstruction.*—Its advantages here are due to its tendency to produce complete relaxation of the abdominal muscles and the viscera.

(2) *Emergency Surgery.*—We have found tropacocaine particularly useful in emergency operations, where time did not permit of a complete evaluation of the patient's physical condition prior to operation.

(3) *Upper Respiratory Infections.*—Tropacocaine proved of particular value to us in operations which were complicated by pulmonary tuberculosis, emphysæma, pneumonic processes, and other infections of the respiratory tract. The reduced incidence of post-operative pneumonitis following intraspinal anæsthesia is well known.

(4) *Metabolic Complications.*—We have found tropacocaine to be of value in operations complicated by metabolic disorders such as diseases of the liver, pancreas, kidneys and glands of internal secretion, where ether anæsthesia has a tendency to produce marked degenerative cellular changes.

(5) *Hypertension.*—In cases associated with hypertension, tropacocaine hydrochloride is particularly useful. It is our custom to give three-quarters of a grain of ephedrine sulphate one hour preceding its administration, and a second dose of the same quantity immediately preceding the operation, as a means of reducing the tendency to any sudden and marked drop in the blood-pressure. Failure to follow this routine resulted in a drop in pressure in one of our cases, from 230 systolic to a point where it was not readable. In this particular instance the pulse became imperceptible, skin cold and clammy, and a true vasomotor collapse ensued, which quickly responded to the administration of three-quarters of a grain of ephedrine. Since this experience we have never deviated from the routine of pre-operative administration of ephedrine.

(6) *Use with Cautery.*—There is no contra-indication to the use of this type of anæsthesia when employing the actual cautery or any electrical apparatus producing a spark.

Contra-indications to the Use of Tropacocaine.—(1) *Neuroses.*—We have found in cases of highly nervous patients that the anæsthesia frequently had to be supplemented with inhalation narcosis because of the failure of the patient to coöperate. Morphine administered before the induction of anæsthesia has a tendency to allay apprehension in some of these cases.

(2) *Cerebrospinal Lesions.*—Although the consensus of opinion among investigators has been that spinal anæsthesia is contra-indicated in diseases of the cerebrospinal system we have found the use of tropacocaine in patients both with recent and long-standing hemiplegias and in a number of cases with cerebrospinal lues not accompanied with any untoward results.

(3) *Hypotension.*—Spinal anæsthesia has been considered as contra-indicated in hypotension, but we have found that, since adopting our routine

of the preliminary administration of ephedrine, patients with a systolic pressure as low as 100 or even 90 suffered no ill effects following the use of tropacocaine hydrochloride.

(4) *Diseases of the Spinal Column.*—Deformities of the spine, suppurative changes and osteo-arthritis are, as a rule, contra-indications to the use of spinal anæsthesia, because of the technical difficulties which may be encountered and the added danger of infection.

(5) *Diseases of the Skin over the Spine* offer a definite contra-indication to this type of anæsthesia.

(6) *Shock.*—Any anæsthetic is poorly borne by patients who are in shock; moribund patients and those with profound cachexia or uræmia do not stand spinal anæsthesia well. We have, as will be demonstrated later, found shock to be the chief contra-indication to the use of tropacocaine.

(7) *Sepsis.*—Blood cultures showing the presence of sepsis definitely contra-indicate the use of spinal anæsthesia, due to the danger of exposing the meninges to bacterial contamination.

(8) *Massive Pleural Effusions and Intrathoracic Growths.*—These are contra-indications to spinal anæsthesia because of the possibility of respiratory embarrassment.

Preparation and Technic for Spinal Anæsthesia.—On the evening preceding the operation the patient is given a sedative, preferably one and one-half grains of luminal or three grains of amytal. As previously stated, all patients are given three-quarters of a grain of ephedrine sulphate by mouth forty-five minutes to one hour before operation, to be repeated immediately preceding the operation. The usual one-sixth grain of morphine sulphate with 1/150 of a grain of atropine sulphate is given one-half hour before operation.

Patients with hypertension are no exception to the rule of the preliminary use of ephedrine, since our experience has taught us that to omit it may lead to a sudden and marked drop in blood-pressure. Should it occur that during the course of the operation the systolic blood-pressure drops below 50, an additional dose of ephedrine is administered, sometimes with the addition of caffeine sodiobenzoate, depending upon the degree of shock.

Although the average drop in the systolic blood-pressure has been found to be from twenty to twenty-five millimetres in this series, we have noticed on a few occasions a drop to such an extent as to make the pressure unreadable, yet in these latter cases it was remarkable how quickly the pressure was elevated after an injection of ephedrine.

Spinal injection is usually made with the patient in the sitting posture. The lateral position is employed in patients who are too sick to sit upright. The level of injection chosen depends upon the type of operation to be performed. For operations below the level of the umbilicus, the site of injection was between the third and fourth or the second and third lumbar vertebræ. For operations above the umbilicus to the level of the diaphragm, the injection was made between the first and second lumbar vertebræ under

pressure, or between the twelfth dorsal and first lumbar vertebræ without pressure. We do not use spinal anæsthesia in operations involving structures above the level of the diaphragm.

In considering the degree of anæsthesia produced by tropacocaine hydrochloride, our records indicate that in 99 per cent. of our cases the anæsthesia was complete. The 1 per cent. of these cases in which the drug failed to produce anæsthesia may be attributed either to a possible non-susceptibility of the patient to tropacocaine or to a failure of the drug to reach the nerve roots because of anatomical hindrances to free circulation within the intra-arachnoid space. We do know, however, that when any difficulty is encountered in the course of the introduction of the needle into the spinal canal so that there is no free flow of spinal fluid into the barrel of the syringe before injecting the drug, that we do not get anæsthesia, or, at best, only an incomplete one. Inability to obtain a free flow of spinal fluid indicates that the tip of the needle has failed to enter the intra-arachnoid space, or the opening in the needle is partially occluded by a small shred of tissue, so that the solution upon injection does not come in direct contact with the nerve roots.

We have also observed that the presence of blood in the spinal fluid has a marked tendency to counteract the action of tropacocaine with no anæsthesia resulting. This is difficult to explain, although it is possible that blood has a neutralizing chemical effect upon the drug so that it fails to be absorbed by the nerve roots.

In about 95 to 96 per cent. of our cases, anæsthesia occurred either almost immediately or within three minutes after the injection of the tropacocaine solution, and lasted from one hour to one hour and fifteen minutes. In the remaining 4 to 5 per cent. the anæsthesia was delayed or did not occur.

Operative Complications.—Minor untoward effects which we have observed were retching and vomiting which occurred in about 10 per cent. of our cases. The more serious complications were anæsthetic shock and respiratory embarrassment.

Anæsthetic shock may be caused by a meningeal reflex from lumbar puncture, position shock occurring when the patient is suddenly changed from one position to another or from intracranial pressure. Varying degrees of shock were observed in 3 per cent. of the cases in this series, most of them incident to a sudden drop in the blood-pressure, which was controlled in most cases by increasing the Trendelenburg position, and the administration of ephedrine with or without caffeine sodiobenzoate.

Shock was manifested by a fall in blood-pressure, rapidity of the pulse, extreme pallor, shallow breathing and coldness of the extremities. In three of our cases, however, shock was the cause of death. Respiratory failure has been the cause of two deaths and was due to a paralysis of the motor nerves of respiration.

Post-operative Complications.—Headache.—Although in our early experience headaches were frequent complications, we now see them less frequently and in a milder form. Such headaches occur within a short time after

operation and may persist for some time. Since using the smaller calibre needles and adopting the Trendelenburg posture for at least forty-five minutes after the patient's return to the ward, the incidence has dropped to less than 5 per cent.

In order to understand the rationale of the treatment of headache, two types must be differentiated—the so-called lumbar puncture headache and the meningitic type.

(A)—*The Lumbar Puncture Headache.*—The more common headache is the lumbar puncture type, which is caused by the reduction of intraspinal pressure due to the seepage of spinal fluid through the opening in the dura made by the needle. The pain is, as a rule, referred to the occipital or parietal regions and appears within twenty-four hours after operation and has a tendency to increase in severity. Evans[7] recommends in such patients the Trendelenburg posture for at least twenty-four hours, maintaining that in this position there is a greater tendency for the opening in the dura to be sealed by fibrin, thereby preventing further leakage of spinal fluid. The incidence of this type of headache can be greatly minimized by careful attention to technic and the use of small-calibre needles, thus reducing the danger of trauma.

(B)—*The Meningitic Type of Headache.*—This may be due to a meningismus, or to a low-grade meningitis, and most frequently follows a breach of technic. The incidence in this series of cases was one-fourth of 1 per cent. The headache is accompanied by rigidity of the neck and photophobia, and is not relieved by the Trendelenburg posture. The use of caffeine and sodiobenzoate intravenously has proven of great benefit in this type of headache, being used in conjunction with concentrated solutions of salines either by rectum or intravenously. Von Jaschke[8] believes that such headaches occur less frequently when using simple aqueous solutions of tropacocaine than with solutions containing sodium chloride.

Nausea and Vomiting.—Nausea and vomiting occurred in approximately 3 per cent. of the cases in this series, and are thought to be the result of a cerebral anæmia. Gastric lavage and intravenous injections of a 10 per cent. glucose in saline solution are the methods we have employed in cases where nausea and vomiting have persisted for more than twenty-four hours.

Hiccup.—Hiccup may become annoying and intractable. It was encountered in 1.5 per cent. of the cases in this series and persisted for several days in each case. The condition may not have been the result of the anæsthesia, but rather of a uræmia or a diaphragmatic irritation of reflex origin.

Paralytic Ileus.—Paralytic ileus was encountered in only one case in this series. The condition may be difficult to distinguish from a generalized peritonitis.

Palsies.—Trauma to the nerve roots or cauda equina may produce transitory or permanent paralysis, with or without sensory disturbances. The transitory type which usually subsides in a few days occurred in one-half of

1 per cent. of our cases, with permanent motor disturbances of the lower extremities resulting in but one case. The patient, white, male, aged fifty years, was laparotomized under general anæsthesia after an attempt was made with spinal technic. Due to a marked deformity of the spine, lumbar puncture was impossible. The usual small-calibre needle could not be used because of its flexibility. In this case the cord may have been injured in the course of the manipulations with the larger calibre needle. This patient, when examined about a year following the operation, was found to have a spastic paraplegia of the lower extremities.

Parotitis.—This complication is difficult to explain in view of the fact that it occurs also in inhalation anæsthesia. Parotitis has been met with in four of our cases. It was bilateral in one patient. We are of the opinion that it is in no way related to the use of tropacocaine.

Hyperpyrexia.—Hyperpyrexia occurred in one patient who was operated upon for an extensive carcinoma of the base of the bladder. It is our opinion that the anæsthetic was responsible for this condition since no other cause could be found to account for it. The elevation of temperature began immediately after operation, reaching 107° F. within thirty-six hours. The exact mechanism involved in this complication has never been clearly defined, but in our opinion may be due to a toxic action of the drug on the optic thalamus or heat centre.

Pulmonary Complications.—Pulmonary complications following operative procedures, although markedly reduced since our employment of spinal anæsthesia, have not been completely eliminated. We feel certain, however, that where pneumonia has followed the employment of tropacocaine hydrochloride, it was in no way related to the anæsthesia but to the debilitated condition of the patient prior to operation. The few cases of pneumonia or pneumonitis that have been observed in this series were always found in old men who had been operated upon for disease of the prostate gland.

Mortality.—In this series of 1,000 administrations of tropacocaine hydrochloride, there were only five deaths.

One of them was undoubtedly from shock due to hæmorrhage rather than from the effect of the anæsthetic. This occurred in a woman who died during the course of a subcapsular nephrectomy for recurrent calculous pyonephrosis. The operation was extremely difficult and prolonged because of the extensive adhesions due to a previous nephrotomy, and was accompanied by more than the usual amount of hæmorrhage. Death occurred at the close of the operation.

The second fatality was in a male, fifty-three years of age, with diabetes of long standing and gangrene of the right leg. His condition was extremely grave and he was practically moribund at the beginning of the operation. Death occurred before the completion of the operation and was due to respiratory failure. This patient was operated upon during our early experience with tropacocaine, and we feel that were he to present himself to us at the present time, spinal anæsthesia would not be our choice.

The third death in this series occurred in a man about fifty-six years of age, with an empyæma of the gall-bladder, who was referred for an emergency operation. He was short and stout, and his condition poor. Two ampuls of tropacocaine were given between the eleventh and twelfth dorsal vertebræ. Following the skin incision the blood-

pressure dropped below the reading point, and in spite of stimulation the pressure could not be elevated. The patient died of respiratory failure.

The fourth death occurred in a man fifty-four years of age with bilateral ureteral obstructive lesions, bilateral renal calculi, and an extremely poor kidney function. A pyelo-ureterotomy was performed on one side under tropacocaine anæsthesia with no untoward effect. About two weeks after the operation the temperature began to rise and the patient showed signs of an impending uræmia. Operation was undertaken to remove a large obstructing calculus from the left ureter. One and one-quarter ampuls of tropacocaine were administered between the first and second lumbar vertebræ. Following the skin incision there was an immediate drop in blood-pressure, the patient became cyanotic and death ensued immediately.

The fifth death occurred in a man fifty years of age, who had large obstructing calculi in the left ureter with pyonephrosis, and who had had two previous ureterotomies of that ureter for calculus. The temperature at the time of operation was 105° and the general condition of the patient was poor. One and one-half ampuls of tropacocaine were given in the first lumbar interspace. Following the skin incision, the patient became cyanotic and developed convulsive twitchings of the fingers and forearms, followed by respiratory embarrassment and finally respiratory paralysis. Death ensued within five minutes.

It is our belief that deaths which occur during spinal anæsthesia are primarily due to cardiac dilatation and respiratory failure. We are of the opinion that debility associated with high temperatures are factors definitely unfavorable to the employment of this type of anæsthesia. We believe that fever produces changes in the cardiac musculature and in the respiratory centre in the brain which tend to make patients more susceptible to the drug.

Final Analysis of Deaths.—Case I.—Undoubtedly shock due to hæmorrhage. Case II.—Anæsthetic death, due to respiratory failure. Patient was in pre-operative shock, and was a third-degree anæsthetic risk. Case III.—Anæsthetic death due to respiratory failure. Patient in pre-operative shock. In this case two ampuls of tropacocaine were given and there is a possibility that the patient may have had an idiosyncrasy to the drug. Case IV.—Death in this case was due to pre-operative shock (uræmia) with the anæsthetic as the contributing cause. A third-degree anæsthetic risk. Case V.—Anæsthetic death due to respiratory failure.

In these five casualties we have only two outstanding anæsthetic deaths. Two of these patients (Cases II and IV) would probably have died no matter what type of anæsthesia had been used. In the final analysis of all cases, we must consider, for our guidance in the future use of tropacocaine, all factors that may have an unfavorable as well as favorable bearing on our judgment. Our experience in this series has left us with a distinctly favorable impression and we feel assured that, in the knowledge we have gained, tropacocaine in the future will show even better results.

One of the writers of this paper is a recognized anæsthetist of over thirty years' experience in the practice of anæsthesia as a specialty who, having tried spinal anæsthesia some twenty-five years ago without much success, was rather reluctant to employ it again about five years ago, but

numerous requests from surgeons for this method of anæsthesia made it obligatory that he perfect himself in the technic.

After using various agents recommended for spinal anæsthesia, he, with the co-authors of this paper, has come to the conclusion that the best results in spinal anæsthesia are obtained from the use of tropacocaine hydrochloride, their judgment being based on the following observations:

(1) Tropacocaine is a safer and more dependable agent for spinal anæsthesia than other agents we have employed.

(2) The ease with which it is administered is of decided advantage.

(3) It is free from marked untoward effects.

(4) Compared with other agents there is a diminished degree of shock, both operative and post-operative, which is noteworthy.

(5) There is a lessened degree of nausea and vomiting when tropacocaine is used compared with other products.

(6) A lessened incidence and severity of headaches is also noted in comparison.

(7) It is rapid in action. In 95 per cent. of our cases, anæsthesia occurred either immediately or within three minutes after the injection of tropacocaine.

(8) In 99 per cent. of our cases the anæsthesia was complete.

(9) The satisfactory duration of the anæsthesia.

(10) Finally, the marked contrast of the physical comfort and mental attitude of the patient as compared to general anæsthesia.

BIBLIOGRAPHY

[1] Chadbourne, A. P.: Uber Tropakokain, ein Benzoyl-pseudotropein, eine neue Kokabase, und dessen Wert als lokales Anesthetikum. Therap. Monatsh., p. 471, 1892.

[2] Schwarz, K.: Zur Frage der medullaren Narkose. Vorl. Mitt. Centralbl. f. Chir., No. 9, 1901.

[3] Meyer, Willy: Tropacocaine Hydrochlorate—A Substitute for Cocaine Hydrochlorate in Spinal Anæsthesia. Med. News, pp. 569–572, April 13, 1901.

[4] Neugebauer, F.: Uber Ruckenmarksanalgesie mit Tropakokain. Wien. klin. Woch., Nos. 50–52, 1901.

[5] Kopfstein, W.: Erfahrungen mit der spinalen Anesthesie nach Bier. Wien. klin. Rundsch., No. 49, 1901.

[6] Sollmann, Torald: A Manual of Pharmacology. Fourth edition, p. 2, Saunders & Co., 1932.

[7] Evans, Charles H.: Spinal Anæsthesia, Principles and Technic. First edition, p. 127, Hoeber, N. Y., 1929.

[8] von Jaschke, Rud. Th.: Lumbar Anæsthesia—the Best Anæsthesia Procedure in Gynecology. Schmerz-Narkose-Anesthesia, No. 1, April, 1931.

TORSION OF THE OMENTUM *

By Charles E. Farr, M.D., and R. F. Bachmann, M.D.
of New York, N. Y.

Torsion of any organ is rather uncommon. It is of interest chiefly from the etiological standpoint and from the variety of symptoms produced. The pathological findings are fairly simple, the end-results well known. The prognosis depends upon the tissue or organ involved and upon timely surgical intervention.

Torsion of the omentum is probably more common than is generally appreciated. Corner and Pinches,[10] in 1905, were able to collect only fifty-one authentic cases. Morris,[16] in 1932, added 160. Probably every surgeon of experience has had one or more but few are reported. For this reason the following seven cases are given in some detail—five collected from the First Surgical (Cornell) Division of the New York Hospital and two observed by one of us (Bachmann) at the Burbank Hospital, Fitchburg, Massachusetts. Our most appreciative thanks are hereby expressed to the various operating surgeons for the privilege of reporting their cases.

Case I.—(Doctor Farr, New York Hospital.) D. C., an obese Italian male of twenty-one years, a chauffeur, entered the hospital January 31, 1932, complaining of a sharp pain in the right upper abdomen of three days' duration. Onset acute while driving auto. Pain constant, unrelated to meals, non-radiating, unaccompanied by nausea and vomiting or symptoms of collapse, but gradually increasing in severity until admission. At no time was there any nausea or vomiting, jaundice, gaseous eructations or other symptoms of gastric distress. Bowels slightly irregular of late; stools normal in color and consistency. Moderate tenderness in the right upper quadrant. No history of previous attacks. His abdomen was rather obese with a firm anterior wall. Tenderness with slight rigidity in the right upper quadrant where an indefinite sensation of a mass was elicited. Rebound tenderness was referred to the right upper quadrant. No herniæ. Leucocytes 15,400; polymorphonuclears, 72 per cent.; temperature, 99.2°; pulse, 80; blood-pressure, 116/32; icteric index, 10.3; urine, negative. A provisional diagnosis of acute cholecystitis was made and operation performed.

Operative Findings.—Moderate amount of free clear fluid on opening abdomen. The great omentum was divided into strands of which one had a very large terminal portion. This had become twisted about five times clockwise. It was gangrenous and the gangrenous portion was a flat disc about ten by eight by one-half centimetres. To this gangrenous omentum was attached another of the tongues of the healthier omentum, evidently a recent attempt to protect the gangrenous portion. Both pieces of omentum resected by double ligation. Exploration negative except for the appendix which was somewhat injected. There was a raw area on the appendix which was bleeding slightly, suggesting that the omentum had been attached to it and torn loose by manipulation. Appendix was removed by double inversion. Closure without drainage.

Pathological Report.—Chronic obliterative appendicitis and twisted omentum with hæmorrhage. Microscopical examination of omental tissue showed congestion of vessels and scattered small extravasations of red blood-cells.

* Read before the New York Surgical Society, November 9, 1932.

Post-operative Course.—Uneventful except for development of slight cough on third day. Stitches removed and dressing changed on sixth day. He was seen May 12, 1932, and was in excellent health.

CASE II.—(DOCTOR FARR, New York Hospital.) H. P., a male adult of forty-eight years, admitted to the hospital July 6, 1931, complaining of acute pain in epigastrium of one day's duration, severe and constant with no radiation. He continued to work and slept that night. The next day he tried to work and could not stand erect because of the pain. There was no vomiting.

The past history showed much belching of gas for three years with periods of freedom from discomfort. He was troubled with constipation for about one year.

Physical examination was negative except for definite rigidity in the right upper quadrant and epigastrium. There was severe pain on pressure in the epigastrium and rebound tenderness. No masses were felt. The leucocytes were 10,700; polymorphonuclears, 69 per cent.; temperature, 100.6°; pulse, 76; respirations, 20. Urinalysis was negative. The flat plate of the abdomen was negative save for hypertrophic changes in the lower lumbar spine. A preliminary diagnosis was made of subacute cholecystitis or perforating peptic ulcer.

Operative Findings.—No ulcer could be found and there was no free gas. The gall-bladder was normal. In the mid-line of the epigastrium was an omental tag of the lesser omentum, about three inches long, which hung down in the region of the pylorus and was slightly adherent to the adjacent viscera. It was freed and elevated and was found to have twisted 720° clockwise; three centimetres of the distal portion were gangrenous. The omental tag was removed after ligation of the base. Complete exploration of the abdomen was negative except for a small Meckel's diverticulum about two feet above the ileocecal valve. It bore no relation whatever to the gangrenous omentum. The appendix was normal and was not disturbed.

Pathological Report.—Only a hæmorrhagic tag of omentum. It is brown-red due to hæmorrhage beneath the surface and deep in. On frozen section there is much necrosis. The outlines of the fat cells are not distinct, but are suggested by the network of capillaries.

CASE III.—(DOCTOR CORNELL, New York Hospital.) H. W., a male adult of thirty-three years, admitted to the hospital September 10, 1927, complaining of sharp pain in the right lower abdomen of three days' duration. Onset of pain was sudden; pain was intermittent in character, but gradually increased in severity. He was slightly nauseated, but did not vomit. Bowels were constipated; no urinary symptoms.

Rigidity in the right lower quadrant of abdomen with tenderness and a suggestive mass. There was slight resistance in the left side of the abdomen, but very little tenderness. Rectal examination was negative except for tenderness in the right gutter. Temperature, 100°; pulse, 80; leucocytes, 12,000; polymorphonuclears, 76 per cent.; urine, negative. *Diagnosis.*—Acute appendicitis.

Operative Findings.—Appendix long, adherent and containing concretions; it was removed. Exploration of abdomen revealed that omentum was twisted and tip bluish-red in color. This was delivered into wound and found twisted nine times. Ligated and removed gangrenous area.

Pathological Report.—Infarcted fat—hæmorrhage and twisting of the omentum; sclerosed appendix.

Post-operative Course.—Patient had some discomfort (pain) first two days. After that recovery uneventful. Patient discharged cured on ninth day.

CASE IV.—(DOCTOR WEEDEN, New York Hospital.) L. S., a woman of thirty-two years, admitted to the hospital September 29, 1925, complaining of abdominal pain of forty-eight hours' duration. She had had a mild pain in the right lower quadrant two days before; twenty-four hours later it became severe, localizing in the right lower quadrant and epigastrium. Pain did not radiate to the shoulder, back or groin. No nausea nor

vomiting. Appetite, good; constipated. No jaundice. No previous attacks. Family and past histories negative.

Marked tenderness and moderate rigidity to deep palpation in the right lower quadrant over McBurney's point. The tenderness extended up the right side as far as the umbilicus. There was slight tenderness in the right upper quadrant over the gall-bladder. Left side negative. Urine showed trace of bile; leucocytes, 12,200; polymorphonuclears, 72 per cent.; temperature, 101°; pulse, 96. *Pre-operative Diagnosis.*—Acute appendicitis.

Operative Findings.—As peritoneum was opened a mass of omentum about six inches long and three inches wide which came from the transverse colon was found to be very much inflamed and somewhat necrotic. No reason for this condition could be found, as the omentum was not in contact with any other organ and there was no demonstrable twist of the pedicle. It was removed after ligation. Gall-bladder was swollen to half again normal size, walls were considerably thickened and it contained numerous stones. It was removed. Closure with drainage.

Pathological Report.—Cholecystitis subacute and cholelithiasis; peritonitis fibrinopurulenta—piece of omentum eight by five centimetres, much thickened, dark brown in color and in parts almost black. Microscopically showed marked engorgement of vessels, large blood extravasations in the interlobular connective tissue of omentum. Peritoneal covering of omentum much thickened by a fibrinopurulent infiltration of subendothelial connective tissue. This infiltration extended into neighboring fatty tissue.

Post-operative course.—Uneventful recovery. Discharged cured on fourteenth day.

Case V.—(Doctor Hitzrot, New York Hospital.) A. F., a woman of forty years, admitted to the hospital September 23, 1920, with intense pain in the right upper quadrant of the abdomen radiating to the right scapular region and left side, existing ever since discharge following first admission two months previously, at which time a diagnosis of cholelithiasis was made, although no definite evidence of gall-stones could be shown by X-ray. X-ray at that time was also negative for renal calculus, and any organic change in stomach or duodenum. Pain had existed for past seven months, especially after eating. She had considerable gas on stomach; unable to raise it. Nauseated but did not vomit. No jaundice except in scleræ. Difficulty in breathing during attacks. Since last admission pain has increased in severity and frequency. A very well-developed and well-nourished female of forty years, appearing in some pain. Abdominal examination showed moderate tenderness in the right upper quadrant, very severe in epigastrium just below xiphoid. Upper half of right rectus rigid. No organs palpated; no masses definitely felt, though there was an indefinite sense of a mass in the right upper quadrant. Stools normal. Urine showed a trace of bile. Leucocytes, 15,000; polymorphonuclears, 81 per cent.; temperature, 99°; pulse, 80. *Pre-operative Diagnosis.*—Acute cholecystitis.

Operative Findings.—On opening abdomen, gall-bladder seemed a little distended, but it was not adherent, contained no stones, and emptied quite readily. Further exploration showed an inflamed piece of fat attached to the gastrohepatic omentum and adherent to the suspensory ligament of the liver. After freeing this from the ligament an inflamed piece of fat was found plastered down on the anterior wall of the stomach in the region of the lesser curvature. After freeing it from this region, the stomach wall, except for a superficial irritation, was not involved and there was no evidence of any lesion in the stomach wall on careful examination. The piece of fat evidently originated from a pedicle which had become twisted, there being at least three turns in the pedicle. The fat itself was hæmorrhagic. Fat was excised between ligatures. Further exploration of the abdomen showed an appendix which was bound down at its base by a band of adhesions. The appendix was removed and its base inverted by double row of chromic. Examination of the uterus was negative. No cause for the symptoms was found other than the piece of strangulated fat above described. Abdomen closed without drainage.

Pathological Report.—Appendix showed nothing remarkable. Piece of fat, dark red

in color, one and one-half by three by three centimetres; it had a short pedicle, around which the specimen had rotated, producing infarction of the fat.

Post-operative Course.—Recovery uneventful. Discharged cured on the thirteenth day.

CASE VI.—(DR. P. O'DEA, Burbank Hospital, Fitchburg, Mass.) M. H., a female of fifty-six years, entered the hospital in August, 1931, complaining of abdominal pain of four days' duration. Onset gradual, beginning as a dull ache in the lower abdomen, aggravated by walking. No nausea. Pain relieved by lying down. Bowels regular. No previous attacks. On morning of admission while walking she was seized by a very acute pain in the right lower abdomen, so severe she felt faint. She went to bed and the pain subsided; but she had a feeling that if she got up and walked she would have a recurrence of pain.

Some tenderness on palpation over the whole lower abdomen, most marked over right groin. No spasm. Rectal examination showed uterus to be small and movable; a mass was felt posterior to uterus, very tender, quite hard and not attached to uterus. Temperature, 97.4°; pulse, 99; respirations, 20. Urine showed one plus albumen, many leucocytes and pus, much epithelium. Leucocytes, 11,600; polymorphonuclears, 75 per cent. *Pre-operative Diagnosis.*—Undetermined; exploratory laparotomy decided upon.

Operative Note.—(Dr. R. H. Miller, of Boston.) Uterus contained one fibroid in fundus, size of cherry. Behind uterus a firm boggy mass which turned out to be a lump of semi-necrotic omentum about the size of an egg. Pedicle twisted on itself three to four times. Mass easily removed. Fibroid enucleated. Appendix not remarkable; removed.

Post-operative Course.—Uneventful recovery.

CASE VII.—(DR. G. P. NORTON, Burbank Hospital, Fitchburg, Mass.) G. Q., a woman of thirty-seven years; admitted to the hospital August 7, 1931, complaining of abdominal pain of a few hours' duration. She was suddenly seized with pain in the epigastrium, and vomited; the pain continued, but two hours later it localized in the right lower quadrant with tenderness throughout. Patient gave history of previous attacks of abdominal pain. Abdominal examination revealed tenderness in the right lower quadrant with some spasm; otherwise negative. Temperature, 100.4°; pulse, 76; respirations, 20; urine, negative; leucocytes, 12,000; polymorphonuclears, 85 per cent. *Pre-operative Diagnosis.*—Chronic appendicitis.

Operative Findings.—Twisted piece of omentum that was very much discolored and beginning to become gangrenous, about size of an egg. This mass was ligated and removed. Appendix long and inflamed, and tied down almost its entire length; removed in routine manner. Uterus and adnexia normal in size and position. Gall-bladder palpated; it was tense and stones could be palpated in it. Because of patient's condition and the great amount of fat, it was deemed advisable not to do any further operative procedure. Abdomen closed in layers.

Post-operative Course.—Uneventful recovery. Discharged on thirteenth day.

None of the cases were associated with hernia; it is true that in some of them the presence or absence of hernia is not stated, but it is assumed that such a pathological finding was not present. The same may be said of the presence or absence of free fluid in the peritoneal cavity upon opening the abdomen. Thus, the torsion was either idiopathic or associated with some other intra-abdominal pathological process, although in some of the cases it seems a little difficult to decide the exact status.

In addition to the above cases the senior author has seen on several occasions omental and epiploic tags which gave some, but not conclusive, evidence of having undergone torsion. It is quite probable that such occurrences are not rare. They may account for some of the evanescent attacks of abdominal pain, slight fever and malaise which are so difficult to explain.

To us the most interesting feature of torsion is its etiology. All torsions seem to occur in closed cavities, with low atmospheric pressures and smooth gliding surfaces. Such factors are common to torsion of the ovary, perhaps the most common of all, the testis, the tubes, the appendix, the bowel and finally the omentum. All are attached at one or both ends. The shape of ovary and testis is not unlike, the others are quite diverse. All have some sort of pedicle formation. All contain arteries, veins, lymphatics and nerves. All are subject in varying degree to external forces and changes in pressures, by muscular action, by the diaphragm, by the abdominal wall or by peristaltic wave. External violence as from blows, falls, manipulations, *etc.*, is common to all. Change of body position affects all alike.

Change in tissue structure or density preceding torsion may conceivably be a factor, for example, mild inflammations, œdema, adhesions, excess deposit of fat. Surely such factors are pre-disposing only.

The inciting cause of the first quarter turn (90°) is very easy to understand. Any change in body position, in intra-abdominal pressure, or any sudden increase in peristalsis, could easily rotate an organ in unstable equilibrium one-quarter turn. Why does the twisting continue, even to the point where untwisting becomes difficult or impossible? Many theories have been advanced, mostly based on the continued application of the forces above mentioned. Aside from peristaltic action, which is very impressive to one who has observed it on the operating table, these forces do not appear sufficient. They are either too feeble or not continuous enough, or have too little point of application, to effect complete torsion and strangulation.

Our only remaining common factors in organs subject to torsion are the structures themselves, namely the blood-vessels, lymphatics and nerves. Of the last it may be stated that we know little. It is conceivable, however, that they are able to send messages of distress which call for increase or at least change of action, principally as to blood supply and peristaltic motion.

Lymph flow must have considerable bearing. When retarded by even one-quarter turn of the pedicle, stasis results, œdema begins, the weight of the organ increases, and a tendency to sag, possibly even to twist can easily be imagined.

This tendency is much more pronounced in the case of the blood-vessels. The arteries are shorter than the veins, firmer, thicker walled. A beginning twist will cut off venous return long before arterial supply is greatly impeded. The veins distend, become tortuous and begin to wind around the arteries. The process of rotation is thus carried on, probably accentuated by hyperperistaltic action in neighboring organs, possibly aided also by muscular overactivity of the diaphragm, the abdominal wall, *etc.* In the meantime, passive congestion increases the weight of the organ and hinders any tendency to right itself. Œdema is increased, hæmorrhages occur and finally infarction. Atrophy, complete necrosis or gangrene, or infection and peritonitis may be the end-results.

We must confess that no one of these various hypotheses seems adequately to account for torsion of the extreme degree not rarely seen. Probably a combination of forces, rather than any one, is responsible.

Elaborate classifications of torsion of the omentum have been proposed by several authors, notably Morris.[16] They are, in general, based on the presence or absence of hernia as an underlying cause and on the question of one pedicle or two, that is, whether the omentum is attached by adhesions to a hernial sac or ring, or to some other part of the peritoneal lining. The natural classification of acute or chronic or recurrent type is also used.

The symptomatology of torsion of the omentum presents no outstanding characteristic or pathognomonic features. Perhaps the one striking observation in our series is that the surgeon was never convinced of the accuracy of his pre-operative diagnosis. The signs and symptoms, the history and the laboratory findings pointed to an intra-abdominal surgical emergency but never to a definite positive diagnosis. The correct diagnosis was never made, never even suggested or considered. It is perhaps only fair to state that in this series hernia did not appear.

Diagnosis of torsion of the omentum has seldom been made pre-operatively. The presence of a hernial orifice, a history of pre-existing, easily reduced hernia, and the finding of a soft, rather doughy mass in the right abdomen, are suggestive. The remaining signs and symptoms with the laboratory findings point only to an intra-abdominal lesion of moderate intensity but without indications as to the specific organ involved. The absence of nausea and vomiting, the low leucocyte and polymorphonuclear percentage, the relatively mild reaction to palpation in our series are interesting observations.

The prognosis in omental torsion is quite favorable if timely surgical intervention is instituted. There was no mortality in our cases. The natural risks from anæsthesia and laparotomy in stout people of adult years must be considered. Post-operative pneumonia, embolism, wound infection, peritonitis are ever-present dangers.

The treatment is purely surgical. It consists of removing the strangulated mass and covering the stump with peritoneum if possible. Any attempt at untwisting is unwise, usually is impossible.

Conclusions.—(1) Torsion of the omentum is an abdominal condition occurring more frequently than is ordinarily supposed; it is difficult to diagnose pre-operatively, but would probably be recognized more frequently if considered more often in the differential diagnosis of abdominal pain.

(2) Torsion may occur without apparent cause (so-called primary idiopathic torsion) or may be secondary to other pathological processes, such as inflammation, neoplasia and hernia.

(3) The condition is especially apt to occur in obese or well-nourished individuals, and may be initiated by abdominal trauma or severe physical exertion.

(4) The symptoms and signs are those of peritoneal irritation plus the rapid formation of a mass, palpable in many cases.

(5) Torsion is most often confused with acute appendicitis with appendiceal abscess; less frequently with acute cholecystitis. In cases associated with hernia it is often diagnosed as incarcerated or strangulated hernia.

(6) The prognosis is excellent with timely surgical intervention. Stout, middle-aged patients are poor surgical risks at best. The mortality is due to complications.

BIBLIOGRAPHY

[1] Aimes: Quoted by Morris[16]; also Cowell.[3]

[2] Mauclaire: Quoted by Mullen.[13]

[3] Cowell: Abdominal Torsion of the Omentum. Brit. Surg. Jour., vol. xii, pp. 738–751, 1924–1925.

[4] Oberst: Quoted by Morris[16]; also D'Errico.[15]

[5] Demons: Quoted by Morris.[16]

[6] Bayer: Quoted by Jeffries.[17]

[7] Eitel: Quoted by Morris,[16] D'Errico,[15] *etc.*

[8] Hochenegg: Quoted by Cowell.[3]

[9] Scudder: Intra-abdominal Torsion of the Entire Great Omentum. ANNALS OF SURGERY, vol. xl, p. 916, 1904.

[10] Corner, and Pinches: Amer. Jour. Med. Sci., vol. cxxx, pp. 314–329, 1905.

[11] Lejars: Quoted by Cowell.[3]

[12] Fuller: Quoted by Mullen.[43]

[13] Mullen: Torsion of the Great Omentum. Surg., Gynec., and Obst., vol. xl, pp. 635–641, 1925.

[14] McWhorter: Torsion of the Omentum without Hernia. Arch. Surg., vol. xvi, pp. 569–582, February, 1928.

[15] D'Errico: Primary Torsion of the Great Omentum. N. E. Jour. of Med., vol. cciii, No. 24, pp. 1181–1188, December 11, 1930.

[16] Morris: Torsion of the Omentum. Arch. Surg., vol. xxiv, No. 1, pp. 40–76, January, 1932.

[17] Jeffries: Torsion of the Great Omentum. ANNALS OF SURGERY, vol. xciii, No. 3, pp. 761–765, March, 1931.

[18] Picquet: Quoted by Cowell.[3]

[19] Bierman, and Jones: Surg., Gynec., and Obst., vol. xxxvi, p. 708, 1923.

[20] Studebaker: Quoted by Morris.[16]

[21] Palmer, and Hardman: Strangulated Epiploic Appendix Simulating Appendicitis. ANNALS OF SURGERY, vol. xciv, pp. 1118–1120, 1931.

[22] Watson: Quoted by Mullen.[13]

[23] Anderson: Torsion of the Great Omentum. Jour. Am. Med. Assn., vol. xcvi, pp. 1227–1228, April 11, 1931.

[24] Thorek: Primary Torsion with Report of Case. Med. Jour. and Rec., vol. cxxxiii, pp. 526–528, June 3, 1931.

[25] Huff: Torsion. Va. Med. Monthly, vol. lvii, pp. 583–584, December, 1930.

[26] Tait: Quoted by Mullen.[13]

[27] Robinson: Quoted by Mullen.[13]

[28] Baldwin: Quoted by Cowell.[3]

[29] Draper, and Johnson: The Pathologic Omentum. Jour. Am. Med. Assn., vol. lxxxviii, pp. 376–379, February 5, 1927.

BILATERAL SNAPPING THUMBS

By Edward L. Compere, M.D.

of Chicago, Ill.

FROM THE DIVISION OF ORTHOPÆDIC SURGERY OF THE UNIVERSITY OF CHICAGO

Chronic traumatic and inflammatory lesions of the tendons and tendon sheaths of the hand are not uncommon and are often quite disabling, yet there are few reports of these cases and the American literature is surprisingly silent upon the subject. Snapping index or "trigger fingers" are occasionally seen in any large clinic, while the stenosing tendovaginitis at the radial styloid process which was first reported by de Quervain, in 1895, and recently reviewed with an excellent résumé of the cases in the literature by Finkelstein, is still more common. De Quervain declared that the condition occurred only in the tendon sheath of the abductor longus and extensor brevis pollicis tendon. A similar lesion which involved the tendon or tendon sheath of the flexor pollicis longus muscle was described by Paulson, Nussbaum, Troell, and Finkelstein (Case X), while Hauck, in 1923, and Kroh, in 1925, described the only cases of bilateral tendovaginitis of the m. flexor pollicis longus with snapping thumbs that I have been able to find in the literature. These authors have also noted similar lesions of other tendons of the hand.

Because there is so little general knowledge of this subject the condition has been erroneously diagnosed as rheumatism, neuritis, periostitis, tenosynovitis, tuberculous osteitis, or, as in the case reported here, chronic recurring dislocation at the distal interphalangeal joint.

Report of Case.—A woman, aged twenty years, came to the University of Chicago clinics on April 15, 1930, because of "locking" of the distal phalanx of both thumbs. The patient stated that since the age of three or four years she had had difficulty in flexing the distal phalanx of both thumbs, and, when flexed, she was often unable to extend this phalanx without assistance from the opposite hand. Upon either flexion or extension there was always a visible jerk and a snap or click was often noted. The patient was a skilled pianist and not only was the disability a handicap to her but after an hour or more at the piano the thumb became quite painful and the difficulty in either flexion or extension became much more marked. Numerous medical consultations had failed to explain or relieve the condition. As a result of the disability she had been compelled to give up her position as a teacher of the piano. With the exception of the disability described, the past history was not relevant.

An examination of the hands revealed an entirely normal appearance, but flexion of the distal phalanx of either thumb was possible only with considerable effort and was accompanied by a snap or click. The initial impression was that this was a case of recurrent dislocation which accompanied each *flexion* of the phalanx. However, when the tendon of the flexor pollicis longus muscle was palpated, a firm nodule was detected near the base of the thumb which moved with the tendon and seemed to snap abruptly back and forth in the sheath with a palpable click upon flexion or extension of the distal phalanx. It seemed probable that this was a condition analogous to the more common one of snapping index finger, or "trigger finger." Since there is a transverse band

across the tendon sheath just at the level of the tendon nodule, it was thought probable that the phenomenon was due to the difficulty in passage of the nodule through the narrow portion of the tendon sheath. The nodules proved to be radiolucent. Other laboratory tests were normal. A diagnosis of tendonitis stenosans of the flexor pollicis longus tendons, bilateral, was made.

Operation was performed on both hands May 27, 1930. The approach was through an incision on the outer side of the thumb, extending from the distal interphalangeal joint proximally to the base of the first metacarpal bone. By reflecting the medial flap the sheath of the flexor pollicis longus tendon was exposed. The sheath was opened longitudinally to the transverse volar ligament which was incorporated in the tendon sheath as a dense transverse band of fibrous tissue which constricted the sheath and tendon. When traction was applied to the tendon distal to the constriction band, there was a definite resistance and then with an audible click a nodular, fusiform

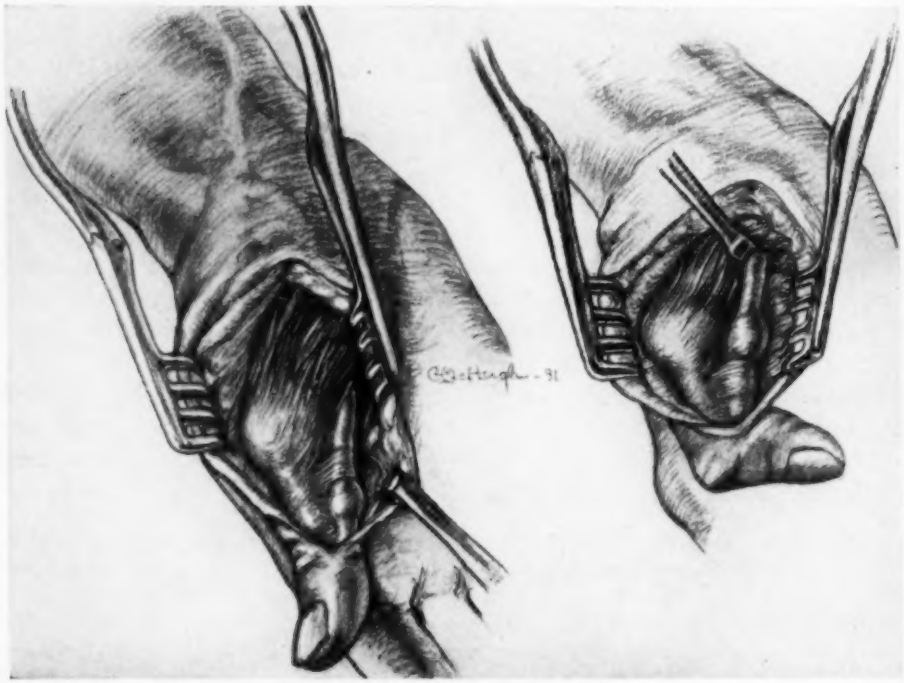

FIG. 1.—Diagram illustrating the nodule in the tendon of the flexor pollicis longus muscle. When the distal phalanx of the thumb was extended the nodule was distal to the transverse fibrous band. When the thumb was flexed at the distal interphalangeal joint the nodule was drawn through the constricted portion of the sheath to the proximal side of the fibrous band.

swelling in the tendon snapped into view. This nodule was one centimetre in length and more than twice as thick as the diameter of the tendon itself. The tendon fibres were rough and frayed from the constant friction of forcing this nodule through the narrow portion of the tendon sheath. When the thumb was now forcibly extended the nodule was pulled up out of sight and again the snap or click was both heard and palpated. (Fig. 1.)

The tight transverse band was divided and part of the sheath was cut away as far as the point at which the tendon disappeared beneath the short muscles of the thumb. (Fig. 2.) The tendon was then split open through the fusiform swelling and about half of the nodular portion of the tendon was excised and the slit in the tendon was closed. It was then possible to extend and flex the thumb without any difficulty and both the jerk and the click had disappeared.

A similar procedure was carried out on the right hand and an identical condition was found, although the nodule in the tendon was larger than that on the left side.

The patient made an uneventful recovery and she was discharged from the hospital six days after the operation.

Physiotherapy was continued for two weeks and when she returned to the clinic on June 25, 1930, one month after operation, the range of motion was normal and there was no "click." Two months after operation, July 25, 1930 (Fig. 3), there was no pain, stiffness, or tenderness in either thumb and she reported that she played the piano with greater freedom than she had ever been capable of before the operation. In December, 1930, seven months after operation, the patient reported that she was again teaching piano and that there had not been the slightest return of the disability. At the time of the last visit, September 28, 1931, the range of motion and function of the thumbs was entirely normal.

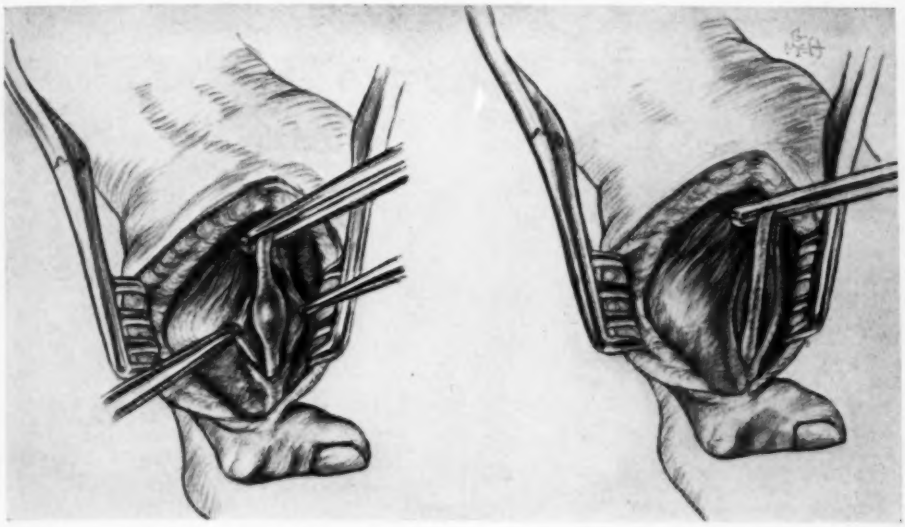

FIG. 2.—The sheath has been opened and part of the constricting band has been cut away. The second illustration shows the appearance of the tendon following excision of the central portion of the "tumor."

A microscopical study of some of the tissue removed from the fusiform nodules revealed numerous cartilage-like cells among the dense fibrous tissue of the tendon.

Comment.—The etiology of tendonitis stenosans has been attributed to chronic trauma and in cases previously reported the onset of the symptoms has usually been in older patients. Finkelstein's case was fifty years of age and the disability had been noted only sixteen months. At operation a fusiform swelling one centimetre long was found in the m. flexor pollicis longus tendon at the metacarpo-phalangeal joint of the right thumb. Troell studied the case of a piano teacher, sixty-four years of age, who had, in addition to tendovaginitis at the radial styloid process, a "doigt á ressort" or snapping finger on the middle finger of the opposite hand. A second case, also a woman, aged fifty-six years, had for four years had a snapping of the flexor pollicis longus tendon as well as a tendovaginitis stenosans at the radial styloid process. Troell also felt that chronic trauma was the most obvious etiological factor.

Poulsen reported fifteen similar cases, and in five of these a small tendon tumor was found in the long flexor tendon of the thumb. Nussbaum reported stenosis of the sheath of the flexor longus pollicis tendon without a tendon tumor.

Kroh described seven cases with involvement of the long flexor of the thumb with difficulty in flexion or extension of the distal phalanx and definite "snapping"

upon such motion. Of seven additional cases involving the flexor tendons of the fingers, the audible snapping was noted in four while in three there was only difficulty in flexion and extension associated with pain upon motion without the snapping. Kroh's cases included a male child aged two and one-half years with involvement of the left thumb and a female aged three and one-half. The duration of symptoms in each case was two to three weeks and in each instance a nodule was found in the flexor pollicis longus tendon. In a third case, aged forty-eight years, the disability was bilateral and had been present for six weeks on the left hand and two years on the right. Hauck also found this condition in two young children, both females, aged two and three and one-half years, respectively. In a total of four cases the disability was due to a nodule in the flexor pollicis longus tendon and was associated with definite snapping. In eight additional cases there was snapping and difficulty upon flexion and extension of the distal phalanx of the thumb, but the pathology present at operation consisted of thickening or contracture of the sheath of the m. flexor pollicis longus tendon without a nodule or tumor of the tendon itself.

FIG. 3.—Normal voluntary flexion and extension of the thumb, July 25, 1931, two months after operation.

In a review of the literature forty cases were studied. In each of these cases the disability consisted of difficulty in flexion and extension of distal phalanx, associated with pain and "snapping" upon motion. In seventeen of the forty cases nodules were found in the flexor pollicis longus tendons, and, in two of these, one reported by Kroh, aged forty-eight years, and a second by Hauck, aged three years, the condition was bilateral.

The ages varied from two years to seventy-one years. There were eight patients six years or younger, but only two of the other patients were less than forty years of age.

The disability is far more common in the female, since there were only four males in the series, thirty-three females and three cases in which the sex was not clearly stated.

Most of the patients were treated by operation in which part of the sheath was cut away, permitting free motion of the enlarged portion of the tendon.

In every instance complete relief from symptoms was reported, while attempts to treat the condition conservatively before advising operation had been uniformly unsuccessful.

The etiology of the condition is doubtful. The occurrence in very young children would indicate a congenital basis but most of the patients were more than forty years of age and the duration of the symptoms in these patients was from four weeks to two years. In some of the cases, as in our own, the slight enlargement of the tendon may have dated from intra-uterine life, while the constant use of the thumb not only may have contributed to irritation, thickening and narrowing of the tendon sheath, but caused further enlargement of the tendon nodules themselves.

SUMMARY

(1) The literature describing cases of snapping thumbs due to involvement of the flexor pollicis longus tendons has been reviewed.

(2) A case of bilateral snapping thumbs has been reported.

(3) These cases do not respond to conservative treatment and should be treated surgically.

BIBLIOGRAPHY

[1] De Quervain, F.: Über eine Form von chronischer Tendovaginitis. Cor.-Bl. f. schweiz. Aerzte, vol. xxv, p. 389, 1895.

[2] Finkelstein, H.: Stenosing Tendovaginitis at the Radial Styloid Process. Jour. Bone and Joint Surg., vol. xii, p. 509, July, 1930.

[3] Poulsen, K.: Doigt á ressort. Bibliot. f. Laeger, p. 55, 1908; Tenosynitis i förste Kuliss paa antibrachium. Hospitalstidende, p. 66, 1911; Sehnenscheidenentzündung im ersten Fach des Antibrachium begleitet von Tractionsperiostitis am Processus styloideus radii. Deutsch. med. Wchnschr., vol. xxxvii, p. 843, 1911.

[4] Nussbaum, A.: Beitrag zur Tendovaginitis stenosans fibrosa des Daumens (de Quervain). Bruns' Beitr. z. klin. Chir., vol. civ, p. 140, 1917.

[5] Troell, A.: On Tendovaginitis and Tendinitis Stenosans. Acta chir. Scandin., vol. liv, p. 7, 1921–1922.

[6] Hauck, G.: Über eine Tendovaginitis stenosans der Beugesehnenscheide mit dem Phänomen des schnellenden Fingers. Archiv. f. klin. Chir., vol. cxxiii, p. 233, 1923.

[7] Kroh, F.: Schnellender Finger und stenosierende Tendovaginitis der Finger beugesehne. Archiv. f. klin. Chir., vol. cxxxvi, p. 240, 1925.

TRANSACTIONS

OF THE

NEW YORK SURGICAL SOCIETY

STATED MEETING HELD NOVEMBER 9, 1932

The President, Dr. John Douglas, in the Chair

SYMPATHECTOMY FOR HIRSCHSPRUNG'S DISEASE

Dr. Edward J. Donovan presented a man, twenty-three years of age, who was first admitted to Saint Luke's Hospital May 2, 1921, at the age of twelve years, complaining of constipation since birth. His past history, aside from the chief complaint, was negative except for the fact that he had passed a small amount of blood by rectum one year before. X-rays at this admission showed a very large descending colon. In spite of the fact that no anal obstruction was found, the diagnosis of acquired, rather than congenital, megacolon was made. He was discharged from the hospital with his bowels moving daily as the result of cascara and milk of magnesia.

He was readmitted one year later with fecal impaction, and with the history that the above-mentioned régime was successful for only two months after leaving the hospital. Constipation became so bad that he often had but one bowel movement a week. Daily colon irrigations and cathartics removed the impaction. X-rays at this time showed a very great dilatation of the descending colon, sigmoid and rectum.

He was then operated upon by Doctor Bolling July 24, 1922, at which time descending colon, sigmoid and rectum were found greatly dilated. Forty-eight centimetres of sigmoid were then removed, and lateral anastomosis done between descending colon and rectum. Convalescence was uneventful, and he was discharged to the country on the eighteenth post-operative day.

He was admitted three years later with fecal impaction, stating that operation had given relief for about two years. For past year constipation has returned and now is as bad as before. X-rays at this time show prodigious dilatation of lower colon.

Readmitted with fecal impaction January 15, 1932, with history that the rectum feels full all of the time, and that he has no expulsive force in the rectum to empty it. Thinks that he has lost twenty-five pounds in the past few months. Advised at this time to have a sympathectomy, nearly ten years after resection of intestine. He was given an anæsthetic and the fecal impaction was removed manually.

He returned to the hospital February 2, 1932, for the sympathectomy. In preparation for this, he was kept in bed for one week on a low residue diet with a colon irrigation twice a day. February 9, 1932, pre-sacral nerve and part of two inferior mesenteric nerves were removed by transperitoneal

approach. The descending colon and sigmoid were so large that they had to be mobilized to remove them from the site of the operation. Also a lateral anastomosis had been done between the descending colon and rectum. This fact could not be determined by examination of the anastomosed structures at this time. Peritoneum over the sacrum was incised in the mid-line, and the pre-sacral nerve located just beneath this incision in the region of the left common iliac vein. It was cut below the brim of the pelvis just above the hypogastric ganglia and dissected upward, cutting the branches from the fourth, third, second sympathetic ganglia until the inferior mesenteric nerves, found one on either side of the inferior mesenteric artery, were reached. One inch of each inferior mesenteric nerve was resected with the pre-sacral nerve. The patient's convalescence was most uneventful. On the third day after operation the first enema was given. This was expelled with great force and was accompanied by a very satisfactory bowel movement. (Remember that he complained of a lack of expulsive force in the rectum.) Enema daily and mineral oil caused a satisfactory bowel movement each day for the twelve days that he remained in bed. The thirteenth day, or the first day that he sat out of bed, his bowels moved without an enema. He has had no bladder disturbances at any time.

HIRSCHSPRUNG'S DISEASE

Dr. Edward W. Peterson, remarked that Hirschsprung, in 1886, described the disease which has since borne his name as "a condition of congenital high-grade dilatation of the colon, with thickening of all its tunics, especially the tunica muscularis, and retention of large quantities of fecal matter." The dilatation and hypertrophy may affect a part of or the whole of the large bowel. To the cardinal symptoms—dilatation of the colon, abdominal distention and obstipation—may be added languor, apathy, loss of weight, anæmia and general muscular weakness. Occasionally there may be abdominal discomfort, vomiting, fever and evidences of auto-intoxication. Usually when diarrhœa occurs it is merely the over-flow of fecal retention.

The treatment of idiopathic dilatation of the colon in the past, by both medical and surgical measures, had, for the most part, proved unsatisfactory. Following the work of Hunter and Royle, of Sydney, Australia, Wade and Royle, in 1927, reported a case of Hirschsprung's disease treated by ramisection of the lumbar sympathetic ganglia, with excellent results. Later Judd, Adson, Rankin, Learmouth, of The Mayo Clinic, Wade and others had given encouraging accounts of their experience with this operation. There were no deaths recorded. All cases, it seems, were benefited, and the end-results, in properly selected cases, were "spectacular." He himself could add three cases to the growing list of satisfactory results following sympathetic neurectomy.

Case I.—A boy, fourteen years of age, had shown obstipation since birth. Frequent purgatives, enemata and irrigations were always required to move the bowels. The boy never had a natural bowel evacuation. The abdomen

was distended and pendulous and the colon was greatly dilated. In July, 1931, he was admitted to the Babies' Wards of the Post-Graduate Hospital for observation and study. While there he developed acute intestinal obstruction. Dr. R. F. Carter saw him then in consultation, and performed an emergency cecostomy, and introduced a Paul's tube. Rectal and irrigations through the cecostomy opening relieved the obstruction, but had to be continued daily to empty the colon. This treatment was carried out for a long period following the operation and caused considerable decompression of the greatly distended abdomen, but the obstipation persisted. January 14, 1932, the abdomen was opened and the whole colon, and even the appendix, found dilated. The pre-sacral, inferior mesenteric nerves and left lumbar ganglia were resected. Following operation, mineral oil, cascara and irrigations were given as a daily routine. Spontaneous bowel movements began February 2, 1932. At present the patient has one or two normal stools a day without any medication, abdominal distention is no longer present, his general health is excellent, and his whole outlook on life has improved.

Fig. 1.—(Case II.) Hirschsprung's Disease. Distention two days before operation, after weeks of attempts to reduce the size of the abdomen.

Case II.—A boy, four years and eight months of age, was admitted to the Babies' Wards of the Post-Graduate Hospital, August 20, 1932, with a history of constipation during infancy, requiring the frequent administration of cathartic drugs for its relief. After the first year of life normal bowel evacuation rarely occurred, and cathartics and enemata were always necessary to empty the colon. Abdominal distention and colon dilation gradually became more and more marked. (Fig. 1.) Loss of appetite, abdominal discomfort, slight fever and occasional vomiting would always follow if laxatives and enemata were neglected. A röntgenogram, taken September 14, 1932, showed marked dilatation of the whole colon. Preliminary treatment, aimed at decompression of the abdomen, was given for several weeks

before operation. The distention was reduced considerably, but in spite of active mineral oil, cascara and colon irrigation treatment, the obstipation persisted. September 16, 1932, the pre-sacral and inferior mesenteric nerves were resected. Convalescence was very satisfactory. A stool was passed spontaneously on the ninth post-operative day, since which time one or two movements a day have occurred. There has been a marked improvement in the general health of the boy, but the abdomen, while greatly improved, is still larger than normal.

Case III.—A boy, four years and eight months of age, was admitted to the Babies' Wards of the Post-Graduate Hospital, September 21, 1932, with a history of constipation since birth. He had had very few natural bowel movements during his life, and would go for days without a stool, unless laxatives or enemata were given. Of late the obstipation had become much more troublesome. Some abdominal distention, but not marked. A röntgenogram, taken October 16, 1932, showed dilatation of the rectum and sigmoid. October 18, 1932, a laparotomy was performed and the pre-sacral, inferior mesenteric nerves, and the left lumbar ganglia were resected. On the third day after operation there were three spontaneous bowel evacuations, since which time the bowels have continued to act naturally. Aside from an upper respiratory infection, convalescence has been most satisfactory.

It is now ten months since sympathectomy in Case I. The patient has never felt so well. His bowels now move spontaneously daily without even taking mineral oil. He has gained about twenty pounds in weight.

His X-rays at the present time show a rather large colon. They also show very good emptying of the part affected by this operation.

Dr. Henry F. Graham reported the case of a child recently admitted to the Brooklyn Methodist Hospital. The child was in very bad condition and an effort was made on the Pediatric Service to clean out the bowel and improve the condition generally. A transfusion was advised, to be followed later by sympathectomy. The child, however, died before anything could be done. At autopsy the findings were a large dilated sigmoid and rectum which terminated sharply below at a spastic hypertrophied sphincter. A microscopical examination of the hypertrophied portion showed merely normal muscle tissue.

Dr. Charles L. Janssen said that one should keep in mind that not all results are as gratifying as the ones presented. He recently had the opportunity to observe a case in a girl of twenty-four years. After lumbar sympathectomy performed by one of the leading surgeons of this city, the symptoms became considerably more severe, so much so that the digital extraction of fæces was the only way an evacuation could be obtained. However, under conservative treatment there has been marked improvement. In this case the lower extremity of the operated side showed an increase of surface temperature. The maximum difference recorded by the thermo-couple

was 7°. This inequality of temperature was a source of real discomfort to the patient.

Doctor Donovan said that he was disappointed in the last X-ray of his patient to find that there was no evident decrease in the size of the colon. In spite of this fact the patient had a splendid functional result. Doctor Peterson had told him, however, that in his cases where he had resected the ganglia as well as the pre-sacral and inferior mesenteric nerves that there was little evident decrease in the size of the colon.

The speaker had been surprised to find what a simple matter it was to resect the pre-sacral in his case. Some of the recent articles on the anatomy of this nerve show that this varies a great deal but in this case it was a single cord. Regarding bladder disturbances after resection of the pre-sacral nerve, some cases have been reported that had frequency and urgency but of very short duration.

Doctor Peterson added that at present, one did not know how much or how little to do, in resecting the lumbar sympathetic nerves, in Hirschsprung's disease. Wade advocated, through a long incision in the flank, an extra-peritoneal division of the mesially directed branches and the main chain itself below the fourth lumbar ganglion. Judd and Adson have advised, through a transperitoneal operation, the resection of the second, third and fourth lumbar ganglia on both sides. Rankin and Learmouth believe that resection of the pre-sacral and the inferior mesenteric branches will sever all the nerves to the parts of the bowel chiefly affected, thus avoiding the minor disadvantage of disturbing the neurovascular supply of the lower extremities.

Doctor Peterson felt inclined, from his very limited experience, to advocate the resection of the pre-sacral and inferior mesenteric nerves, and also to remove the sympathetic ganglia on the left side.

BIBLIOGRAPHY

Royle: Med. Jour. of Australia, vol. i, p. 77, 1924.
Hunter: *Ibid.*, p. 86.
Wade, and Royle: Med. Jour. of Australia, vol. i, p. 137, 1927.
Judd, and Adson: Annals of Surgery, vol. xxviii, p. 479, 1928.
Scott, and Morton: Jour. of Clinical Investigation, vol. ix, p. 247, 1930.
Rankin, and Learmouth: Annals of Surgery, vol. xcii, p. 710, 1930.
Wade: The Lancet, vol. i, p. 136, 1930.
Rankin: Am. Jour. Surg., vol. xv, No. 2, p. 219, 1932.
Mayo, Charles: Annals of Surgery, vol. xcvi, p. 486, 1932.

ADENO-CARCINOMA IN A CYST OF THE TRANSVERSE MESOCOLON

Dr. Edward W. Peterson presented a woman, sixty-four years of age, who was admitted to the Post-Graduate Hospital, September 19, 1932, complaining of attacks of nausea, vomiting and diarrhœa, and the presence of a movable tumor in the upper abdomen. Twenty years ago she was treated for gastric ulcer and was confined to her bed for six weeks at that time. A gastro-intestinal X-ray study was made thirteen years ago in a Brooklyn hospital. She was told that she had no ulcer but that a chronic appendicitis was responsible for her gastro-intestinal upsets. One and one-half years ago

a tumor, just above and to the left of the umbilicus, was discovered. The tumor gradually grew larger and was about the size of a small grape-fruit when she was admitted to the hospital. This growth appeared to be cystic, was movable in all directions, and pressure upon it caused slight nausea and discomfort. Patient weighed but eighty-five pounds, having lost about fifteen pounds in weight during the past year.

Wassermann, blood-chemistry, and urine negative. Blood count showed only a slight degree of anæmia.

Operation.—September 22, 1932, under spinal anæsthesia, the abdomen was opened through a left rectus incision over the tumor mass. The growth was situated in the mesentery of the transverse colon, was filled with dark fluid superficially, and broken-down, soft material in the depths of its cavity. Some of this material was sent to the laboratory and the report came back that it was "papillary adeno-carcinoma, of a highly malignant nature." It was impossible to remove the tumor without resecting the colon, so marsupialization and gauze packing of the cavity were carried out. The poor condition of the patient did not warrant any more radical procedure.

No other focus of malignancy was found in the abdomen or elsewhere. Doctor Meeker, who made the pathological study in this case, stated that the growth could have been of ovarian origin or possibly could have arisen from sequestrated intestinal tissue in the mesentery. A definite opinion, however, could not be given from the material examined as to the origin of the mesenteric cyst.

In ANNALS OF SURGERY, September, 1932, five cases of mesenteric and one case of omental cyst were reported by the speaker. It is desired to add another case to this relatively rare group of abdominal cysts.

DR. CHARLES E. FARR remarked that mesenteric cysts apparently are either false or true in type. The false cysts may be caused by trauma, by infection, or by invasion with echinococcus. True cysts may take their origin in congenital anomalies, or they may be due to cystic changes in the normal structures in the mesentery or to accidental implantations from surrounding structures, or they may result from the closing of intestinal diverticula.

The diagnosis of mesenteric cyst is rarely properly made before operation.

The diagnostic feature of the mesenteric cyst is a freely movable tumor, evidently intra-peritoneal or retro-peritoneal and of a cystic feel. The use of a contrast meal and pneumoperitoneum would be of great assistance. However, it is difficult, if not impossible, to rule out the soft, cystic feeling but really solid sarcomata.

The treatment of mesenteric cysts is preferably by excision. This is not always feasible, however, and proper treatment may require excision with resection of bowel—a much more formidable operation. Marsupialization should be used as a last resort only, but it is occasionally necessary and the results are at times quite satisfactory. In malignant cysts wide excision is theoretically the ideal but as in Doctor Peterson's case it may not be practicable.

TORSION OF THE OMENTUM

DR. CHARLES E. FARR read a paper with the above title for which see page 766.

Dr. Frank S. Mathews recalled one case of irreducible omental hernia in which acute symptoms developed and at operation there was found a mass of omentum in the scrotal sac which was adherent and not rotated. On making traction upon it a large mass of rotated omentum was found just within the abdominal cavity.

Rotation of the omentum is a particular under the general subject of visceral rotation, the cause of which has always seemed obscure. It is not difficult to understand the very beginning of rotation; but the difficulty seems to be to visualize any kind of mechanism which can continue to exert a rotating influence to the degree of two or three complete revolutions. The commonest structures to rotate are the ovarian tumors, which in themselves have considerable weight and a small pedicle. The testis also at times rotates, but nearly always it is a partially descended testis with a looser attachment than normal.

Two of the most vivid recollections of visceral torsion have been: First, a case of volvulus in a case of megacolon, the abdomen distending to an enormous size in the course of a few hours. The second was a case of volvulus of the small bowel secondary to a Meckel's diverticulum. In this case a profound shock developed in a few hours from the beginning of the symptoms. At operation the abdomen contained much blood-stained fluid; the Meckel's diverticulum was rotated, swollen and plum-colored and about two feet of adjacent ileum were rotated. Here appearances would indicate that the diverticulum first rotated and then acted as a rotator of the bowel. But just how the diverticulum with an attachment only to the bowel could twist it is difficult to see.

Doctor Mathews once assisted Dr. Charles N. Dowd to operate on an acute volvulus of the caput coli in a young man. When it was reduced its attachment proved to be unusually lax. The appendix almost never rotates. Among the less frequent varieties one might mention an axial rotation of an ovary and Fallopian tube in a child. The tube was the seat of a previous pathological process, the end being closed and possibly the seat of a tuberculosis. Dr. William Berry has reported a rotation of a gall-bladder which was not the seat of stones or other previous pathology, but was attached by an unusually long mesentery.

Bland Sutton, in his "Diseases of the Ovary and Fallopian Tube," gives a chapter to axial rotation and mentions two conditions which predispose ovarian tumors to rotation. These are first bilateral tumors, and second ovarian tumor and pregnancy. The termination of the pregnancy in these cases is especially prone to lead to a rotation of the tumor. Fibroids seem to rotate infrequently considering the number of pedunculated ones which are seen. Probably this depends on the rigidity of their attachment.

Doctor Mathews once operated on a case of volvulus shortly after a confinement. There was a fibrous band from the uterus to the side of the pelvis. The small bowel had very largely passed under this band. When the band was divided it was found that the bowel with the root of the

mesentery had rotated through nearly a complete circumference in passing under the band.

Dr. John H. Garlock stated that he had seen three cases of torsion of the great omentum at the New York Hospital during the past few years. All three simulated acute appendicitis and were diagnosed as such before operation. Two of them he had operated upon personally, and the third was operated upon by Dr. Frank J. McGowan. In two instances the torsion was of the free variety; that is, without any attachment peripherally. In the third case, the distal end of the twisted omentum was attached to an inflamed ovary. Judging from this experience and from the cases presented tonight, one would say that the free variety of torsion of the great omentum was more common than that type in which the distal end of the omentum is attached to some abdominal organ or hernial sac.

Dr. Frank B. Berry said his impression was that the torsion is more common where there is an attachment. He had seen one case in a boy fourteen years of age in which the omentum was free and quite thin. The peritoneal cavity contained considerable bloody fluid plus a mass of omentum which had rotated on itself. He has often wondered whether an incarcerated hernia suddenly giving symptoms of strangulation may not be due in part to partial torsion of the omentum.

Dr. Percy Klingenstein, speaking of Doctor Farr's reference to other forms of omental torsion, called attention to torsion of the appendices epiploicæ which can occur intra-abdominally or in a hernia. Particularly is this more common in femoral herniæ. These appendices may undergo complete necrosis and calcification, become detached and appear as loose free bodies (corpora aliena) in the peritoneal cavity.

Dr. John H. Morris remarked that the etiology is the most interesting phase of this condition and in this respect one must consider the bearing of the individual and the physical development. For example, at one time he had four patients, all males, all weighing about 200 pounds, all with full abdomens and considerable subcutaneous fat and diffusely infiltrated omentums. Many theories have been advanced, but the speaker thought the evident infiltration by fat of the omentum and their conformity to a definite stature may be significant. As to the classification Doctor Morris considered that one can divide them into those associated with hernia and those of intra-abdominal origin which were either related to associated pathology or were idiopathic in origin. There is another side to be considered in these days of workmen's compensation. He cited a case of a man riding in a motor truck over a rough road, suddenly seized with severe abdominal pain, put in a hospital, observed for two or three days, operated on and a gangrenous omentum found. He died of peritonitis. The medico-legal question came up as to whether the trauma induced was sufficient to cause torsion of the omentum and, if so, was this a compensable injury.

TRANSACTIONS

OF THE

PHILADELPHIA ACADEMY OF SURGERY

STATED MEETING HELD OCTOBER 3, 1932

The President, Dr. John Speese, in the Chair,

Calvin M. Smyth, Jr. M.D., Recorder

AN EVALUATION OF THE TANNIC-ACID TREATMENT OF BURNS

Dr. James B. Mason, by invitation, read a paper with the above title for which see page 641.

Dr. Isador S. Ravdin said that some years ago Doctor Ferguson and himself wrote several papers advocating adrenalin and novocaine dressings in the treatment of burns, but the tannic-acid method has supplanted every other used at the University Hospital.

Dr. George M. Dorrance said that he is called upon to treat a large number of burn cases at Saint Agnes' Hospital. The reduction of the mortality especially interested him. The general care of the patient is an important factor in this respect. Transfusions are of great value. For dressings he uses ½ per cent. acetic acid. Where there is a definite area of slough, lattice-like slits are made through it and the area covered with acetic acid and it is surprising to see how quickly the slough disappears. The débridement treatment in his experience is too severe. The death rate is higher from burns than from appendicitis. He considers burn cases as emergencies and sees them immediately. If the patient is seriously burned, a blood count is ordered and if the leucocytes are 50,000 or over, a fatal outcome is inevitable. It is a common occurrence to find the hæmoglobin to be 110 and the erythrocytes 6,000,000 in these cases.

Dr. Walter Estell Lee said that tannic acid possessed one advantage over any other method in the treatment of burns to which Doctor Mason has only indirectly referred, namely, the relation of the final scar tissue to the type and duration of the infection of the granulating surface of the wound. The amount of scar tissue which follows burns treated with tannic acid is almost nil because of the short period of suppuration. From a long experience with burns he had been convinced that the scar tissue which follows the usual treatment of burns with unsterile dressings and medicaments is largely (estimate 80 per cent.) due to replacement of tissue lost by the suppuration and that tissue destroyed by the burn itself plays a minor rôle in the formation of this scar tissue. Since the use of tannic-acid treatment scar tissue in their wounds has been almost negligible, and it is a rare

exception to find it necessary to graft the surfaces with skin. It cannot be too frequently emphasized and restated that burns treated with tannic acid show less infection and suppuration and scar tissue than with any other treatment.

USE OF CONTINUOUS INTRAVENOUS INFUSIONS IN ACUTE ABDOMINAL INFECTIONS

Dr. Isador S. Ravdin and (by invitation) Dr. Charles Johnston read a paper with the above title for which see page 749.

Dr. Frank Mogavero (by invitation) remarked that in Doctor Muller's service at the Misericordia Hospital, extensive use was made of continuous intravenous infusion. In their experience the needle is unsatisfactory on account of the tendency for it to slip out of the vein and for this reason the canula was employed. The apparatus which they use, the speaker does not believe is as complicated as that described by Doctor Ravdin. It consists only of an ordinary Kelly bottle with a Murphy drip regulator interposed between the bottle and the canula. The rate of flow is controlled by a screw clamp which is placed above the drip regulator. This simple form of apparatus has given great satisfaction and requires the minimum amount of nursing care.

Dr. Isador S. Ravdin said that Dr. George Muller and himself used a method similar to that referred to by Doctor Mogavero a number of years ago. In their experience it was not as satisfactory as the method described. The side holes in the Murphy bulb must be closed. The method which he now uses is not complicated and, furthermore, it does not necessitate an additional flask for the introduction of the fluid, since the Erlenmeyer flask in which the solution has been sterilized can be used. Some trouble was formerly encountered with the needle slipping out of the vein, but since using the adhesive straps for retention and fixing the arm in a pillow, this rarely occurs. However, it is not the method so much as an appreciation of the problem of fluid and salt requirements which is essential.

PERFORATION OF DUODENAL DIVERTICULUM

Dr. J. Walter Levering (by invitation) reported the case of a man eighty years of age who was seized with severe abdominal pain causing him to collapse. He was immediately brought to the Abington Hospital. He gave a previous history of indigestion for many years with epigastric pain about one hour after meals which was relieved by taking food or soda. There was nothing else in the history of importance. He was apparently in extreme shock; cyanotic and dyspnœic; cold, clammy skin. The heart was enlarged to the left and the sounds were weak. The abdomen was tender and rigid, the rigidity being board-like and general. No peristalsis was heard. No masses were felt. There was no dullness in flanks. A diagnosis of perforated duodenal ulcer was made.

At operation a small perforation of the duodenum was located, the perforation being just beyond the pyloric sphincter. Duodenal contents were leaking out. The first portion of the duodenum seemed to bulge for-

FIG. 1.—The site of the perforation is marked with a probe.

FIG. 2.—Interior of duodenum, showing multiple diverticula.

ward. The liver and gall-bladder appeared normal. The pancreas and appendix were not visualized. The perforation was repaired with purse-string and mattress sutures and a piece of omentum sewed over it. A jejunostomy was done in the usual manner. A suprapubic puncture was made and a cellophane cigarette drain inserted.

Except for a weak irregular pulse the patient's first three post-operative days were normal. Blood chemistry was normal. On the fourth day, he vomited some greenish material and a Jutte tube was inserted. Glucose was given intravenously daily. Peristalsis was present from the fourth day and enema were effective. The pulse, however, continued poor and on the eighth day after operation he died, having vomited blood some hours previous.

Autopsy Findings.—Lungs.—Œdema, emphysema. *Heart.*—Calcareous infiltration of the mitral orifice leading to regurgitation. Chronic aortic valvulitis, fibrosis of the myocardium and fatty degeneration. *Abdomen.*—Localized peritonitis under lobe of liver. Multiple diverticuli of the duodenum, one of which has a necrotic base with a pin-point perforation which has been walled off. (Figs. 1 and 2.) Acute dilatation of the stomach. Chronic glomerular nephritis. Interstitial splenitis. Moderate arterio-sclerosis.

The speaker remarked that in the literature, one is impressed first with the antiquity and later with the frequency of this condition. The first period, as Lockart suggests, the "mortuary" period of 200 years, dates from 1710 to 1910. During this period, less than 100 cases were described at autopsy. Morgagni knew of the existence and mentions a case in 1711. One would expect this reference of Morgagni to be the first, but Chomel, of the Academy of Paris, in 1710, gave an account of a woman, aged eighty, who had a pouch or pocket in her duodenum with stones found at autopsy. For two years previous to her death she had complained of pain and gas two hours after eating.

The second period, known as the period of "röntgenology," from 1910 on, abounds with reports of cases diagnosed by the X-ray, some confirmed at operation and others at autopsy. Therefore incidence is frequent. Regarding position, it has been found in all three portions of the duodenum, usually the second projecting from the median surface. The diverticula may be multiple or single, as high as six are reported.

It is more often found in the relatively old. The size of the sac may vary from very small to three to four centimetres deep and one to two centimetres wide. They consist of mucous membrane and connective tissue, and are devoid of a muscular layer. Except in complications they are devoid of signs of inflammation. Other writers claim that they have a complete muscular coat.

Symptoms are probably due to complications. While they may give symptoms it is practically impossible to diagnose them without the X-ray, as the symptoms are usually similar to those of inflammation of the other anatomically adjacent viscera as in inflammation of the stomach, duodenum, gall-bladder or pancreas.

Lucinian reports a diverticulum perforated into the pancreas. His patient, a woman, thirty-eight years of age, had been operated upon two years previously for

gall-bladder disease. A gall-bladder full of stones had been removed but her symptoms of indigestion, pain after eating, and gas, showed no improvement for two years, after which she was X-rayed and the diagnosis made of duodenal diverticulum perforating into pancreas. This was confirmed by operation. Operation cured her of her symptoms.

Gask (St. Bartholomew's Hospital Report, vol. lxii, 1929) advises against operation in these cases merely because they may be picked up in the X-ray and believes the large majority give no trouble. He tells of a case that was operated upon and no inflammation found. Two years later, because of a continuance of symptoms, upon reoperation an ulcer on the lesser curvature was found, which he felt was overlooked at the time of the first operation.

There are many complications but only a few are reported with serious result. Prolonged retention of material in the sacs favors diverticulitis. Inflammation favors ulceration. Ulceration favors perforation.

Monsarrat in the British Journal of Surgery, 1926, reports an acute perforation in a woman, aged fifty-eight, with recovery following operation. Bauer (Geneva, 1912), reports a fatal obstruction.

The speaker remarked that perhaps the most interesting phase of this subject discussed in this literature is the etiology. Most of the writers conclude that the cause is congenital. The studies of Falcomer and Tandler all support the view that duodenal diverticula are congenital in nature, representing abortive attempts at the formation of a supernumerary pancreas. Linswanger holds that they are congenital only in the sense that these pancreatic anlage cause local defects in musculature. Lockart gives the following reasons for attributing diverticula to congenital defects: (1) The condition has been found in infants. (2) It may be multiple. (3) It may be associated with similar changes in other parts of the alimentary tract. Otto Hahn, in a very complete review of the literature of duodenal diverticula (1931), quotes exhaustively the different writers with their congenital arguments, but, nevertheless, groups the "divertikel" later into headings such as: Das Papillen divertikel; das Ulcers divertikel; das Traktions divertikel; das gallenstein; das sogenante kingenitali; das stenosen divertikel an der flexur duodeno-jejunol—thus concluding that some are congenital, some acquired. Odgers, of the University of Oxford, suggests calling them primary when there is no obvious cause for their appearance. This includes congenital; secondary when there is some cause, such as ulcer, adhesions, or stricture.

CONGENITAL DUODENAL ADHESIONS

Dr. Harry E. Knox remarked that adhesions were spoken of by Neff and Haden in the American Journal of Diseases of Children in 1925 as "Transduodenal Adhesion of Congenital Origin," when they reported the autopsy findings in three infants who died of vomiting from unknown cause. Again, Higgins and Patterson, of England, in the Archives of Diseases of Childhood, in 1926, reported a like condition which they described as "Congenital Duodenal Stenosis Due to Peritoneal Bands." In February, 1931, the speaker reported to the Philadelphia Pediatric Society a series of six cases which he designated as "Congenital Duodenal Adhesions." Since then Dr. Ralph M. Tyson, of Philadelphia, reported four cases. Dr. W. Estell Lee, of this Academy, in a personal communication, recorded another case and to these already reported Doctor Knox now adds the following two:

Case I.—Male, white, eight days old, with a history of having vomited from birth. A diagnosis of pyloric stenosis was made and operation performed on the fifth day of life. Vomiting continued, was bile stained, and the infant continued to lose weight and became extremely dehydrated. Seen

in consultation three days after operation a diagnosis of congenital adhesions was made and a second operation was performed on the eighth day. No difficulties were encountered and after exposing the duodenum many dense adhesions were found and separated. The immediate post-operative condition of the infant was far beyond expectation. Vomiting ceased, the child began to have green stools and a slight gain in weight occurred. However, œdema of the lower extremities developed, the urine showed red blood-cells, and the child died six days after the second operation from acute nephritis, a condition which is frequently seen after operations upon the very young. Autopsy was refused.

Case II.—White, male, eighteen days old, weight five pounds and fourteen ounces, with a history of vomiting since birth, and jaundice; marked dehydration, sunken fontanelles; chest and heart negative. Liver and spleen not palpable. There were slight gastric peristaltic waves, but not the typical golf ball type, but more of a general gastric wave. There was a temperature range of 99° to 100°. When seen in consultation congenital adhesions were strongly suspected and operation advised. Operation was performed on the eighteenth day, after pre-operative preparations of three hypodermoclyses under ether anæsthesia. An upper right rectus incision was employed. Upon opening the peritoneum, a rather thick purulent fluid escaped. The duodenum was identified and numerous adhesions extending from the under surface of the liver to the duodenum were found. These were separated by blunt dissection. All hæmorrhage was carefully controlled. A half-inch incision was made suprapubically and a small rubber tube drain inserted into the pelvis. Wounds were closed. The patient left the operating room in fairly good condition. The next morning it was discovered that a loop of small bowel had escaped around the rubber tube drainage; this was replaced. After this the child appeared to improve greatly, vomiting ceased, the temperature reached normal for the first time since birth, and the infant began to have green stools. But this improvement was short lived, as vomiting recurred, dehydration became marked and the child died eight days after operation. The incision was reopened after death and a small fecal fistula found in the loop of bowel which had herniated. The subhepatic fossa showed the adhesions had reformed, but the purulent peritonitis recovered from.

This second case presents evidence which tends to support the speaker's theory that the cause of the adhesions may be the result of infection which originates from intra-uterine sources, traveling through or along the umbilical vessels or portal vein to the subhepatic fossa. In reviewing the symptoms that have been outstanding, and by which one may have their attention called to this most interesting and important and rather common surgical condition of early infancy, Doctor Knox mentioned the following:

(1) Vomiting. Occurs immediately after birth. In the early stages regurgitation rather than actual vomiting is the rule. Liquids are rejected almost as soon as they are taken, while as time goes on, vomiting becomes cumulative as well as projectile. Bile-stained vomitus is fairly common and bile is not seen in vomitus from a case of hypertrophic stenosis.

(2) Peristaltic waves occur, but the waves are a general gastric type at first, later becoming hour-glass in type as the gastric distension increases due to the obstruction beyond the pyloris.

(3) Loss of weight, dehydration, constipation and lessened urine output complete the picture.

(4) X-ray examination is very helpful in some cases, but when these little patients are greatly dehydrated, as most of them are, very little is gained and risk is added by the time required for the examination and the necessity for lavage afterward. If in operating upon a supposed case of hypertrophic stenosis no hypertrophy is found the subhepatic fossa should always be explored.

Dr. Walter Estelle Lee asked that Doctor Bromer discuss this subject from a radiological standpoint because he has probably had more experience with these lesions in infancy than any one else in Philadelphia. At the Children's Hospital a child presenting all of the symptoms of congenital hypertrophic pyloric stenosis, diagnosed as such by another radiologist, was correctly diagnosed by him. This child was nine months of age, a rather unusual period for congenital hypertrophic pyloric stenosis. The child was a Mongolian idiot and had the physical development of a baby of three months. X-ray pictures confirmed the clinical symptoms of obstruction of the pylorus. At operation there was found an enormously dilated pylorus, measuring one inch in diameter when the stomach was distended with air, and beyond this pylorus a duodenum distended to the size of a golf ball. Distal to this were adhesions of the second portion of the duodenum to the gall-bladder, liver and hepatic flexure producing the obstruction.

Dr. Ralph Bromer (by invitation) demonstrated the röntgenograms of a number of cases of duodenal adhesions and discussed the interpretation of the findings.

RHEUMATIC PERITONITIS

Dr. Edgar H. Weber (by invitation) reported the case of a boy, age seven, who was admitted to the emergency ward of the Episcopal Hospital in February, 1932, with the diagnosis of appendicitis and peritonitis. Two days previously he had returned from school feeling tired and was feverish; the boy was purged. The following day, severe abdominal pain with vomiting occurred and these persisted until admission. Except for headache, during the examination there were no other complaints. The bowels had moved several times following the laxative. He had had a definite attack of acute rheumatic fever one year previously. Otherwise, the past and family histories were irrelevant.

The throat was reddened; the heart revealed no demonstrable lesion. Abdominally, the findings were those of a lower abdominal peritonitis. There was well-marked bilateral rigidity with acute tenderness throughout the lower one-half of the abdomen. Peristalsis was faintly audible. The child was tender throughout the pelvis on rectal examination. He seemed reliably certain that sharp motion of the left ankle was painful. The temperature was 101°. The leucocyte count was 35,000.

Because of the atypical appendiceal history, the throat condition and possible significance of pain on motion of the ankle, the possibility of a systemic infection, was seriously considered. The abdominal manifestations possibly being only part of the picture, laparotomy was postponed, a decision

the wisdom of which the speaker still questions. On the following day there was an acute arthritis of the left ankle, beginning involvement of the right knee without appreciable change in the abdominal findings. On the third day the original joint improved but arthritis of both knees and the right ankle developed. In addition, the boy became semi-stuporous, very irritable and had moderate rigidity of the neck with retraction of the head and a bilateral Kernig's sign.

Large doses of salicylates were begun at this time and within twenty-four hours the meningeal and peritoneal phenomena had almost entirely abated. Joint pains subsided but a three-weeks' course of typical rheumatic fever ensued. A mitral regurgitant murmur developed on the seventh day, increased in intensity and was present on discharge three weeks subsequently.

That this boy had at the onset of his illness a peritonitis, clinically, could hardly be questioned. Doctor Weber realized the absence of essential proof in the form of operative findings and histological sections, but contended that it was a serous membrane phenomena of acute rheumatic fever, basing this contention upon the following: (1) Its occurrence in a young individual having had a previous attack of rheumatic fever. (2) The subsequent course of the illness. (3) Its spontaneous resolutions apparently hastened by the administration of salicylates. These features are in complete accord with those of other reported cases of rheumatic peritonitis.

It is unusual to have such pronounced involvement of the peritoneum at the onset of acute rheumatic fever, and quite rare to have the meninges participate in this polyserositis. This case was presented entirely as a matter of interest and without thought of encouraging its consideration in the etiology of acute peritonitis. It might possibly be considered when abdominal complications occur in the course of this acute infection.

Dr. Edgar H. Weber said that the term "rheumatic" is here used in its most limited sense, namely, pertaining to the acute infectious disease, acute rheumatic fever. Thus, rheumatic peritonitis indicates an inflammation of this serous membrane incited by the organism of acute rheumatic fever.

Dr. Calvin M. Smyth, Jr., recalled a case of a little girl six years of age, who was brought in to the Abington Hospital one night with typical history of acute appendicitis. She was operated upon a few hours after admission, at which time a comparatively normal appendix was found but the lumen was packed with round worms. Her symptoms were, therefore, thought to be due to mechanical rather than inflammatory conditions. Three days after operation she complained of pain in both hips and thereafter ran a typical three-weeks' course of rheumatic fever. Dr. Joseph Stokes, who saw her at that time, was inclined to attribute her original symptoms to the rheumatic involvement of the lymphatic tissue in the appendix or else that the appendix had nothing whatever to do with the picture.

BRIEF COMMUNICATIONS

AN INTER-RINGED CLAMP

A SPECIALLY designed ring clamp to hold and secure tissues and viscera has proved satisfactory in many diverse operations after extensive trial.

The usual ring clamp has two equally grooved rings which, when closed, fix the tissue between them in an actual bite or crush. It is required that all the grooves and bars match and set exactly, otherwise the entire clamping surface is disturbed and the instrument fails to function properly.

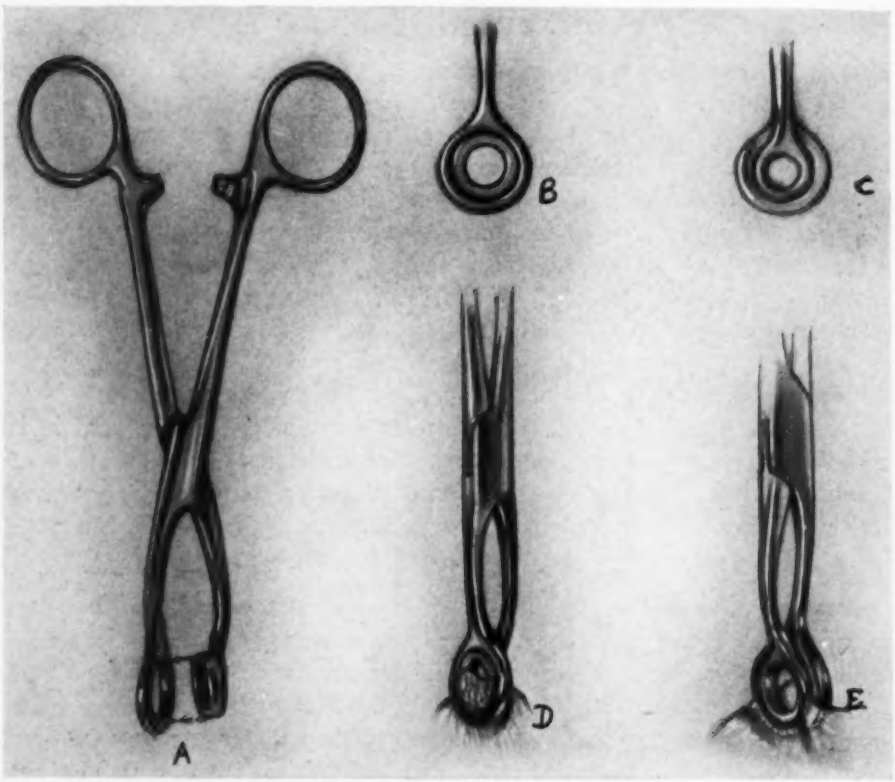

FIG. 1.—Use of the inter-ringed holding clamp in hemorrhoidectomy. A, B, C, D and E—views of the grasping parts of the instrument.

The mechanical principle involved in the type of ring clamp we have developed is not new; its non-slip quality has been employed in the Mathieu's tongue forcep, and it is commonly used in almost all catches for hose supporters.

The instrument has two rings of unequal size. The smaller ring (diameter ½ inch) insets into the larger one (diameter ¾ inch) leaving a free space of 1 millimetre between their nearest circumferences. (Fig. 1.) It is into this free space or circular niche that the grasped tissue or viscera is firmly held

with a minimum of trauma by the opposing and counteracting rings in a grip secure and non-slipping; although without direct pressure and crush.

A clamp with unequal rings has advantages peculiarly useful for special operations. For hemorrhoidectomy, the smaller ring is applied to the skin surface of the hemorrhoid and the larger ring to mucous-membrane part of the hemorrhoid within the rectum. (Fig. 2.) This facilitates skin conserva-

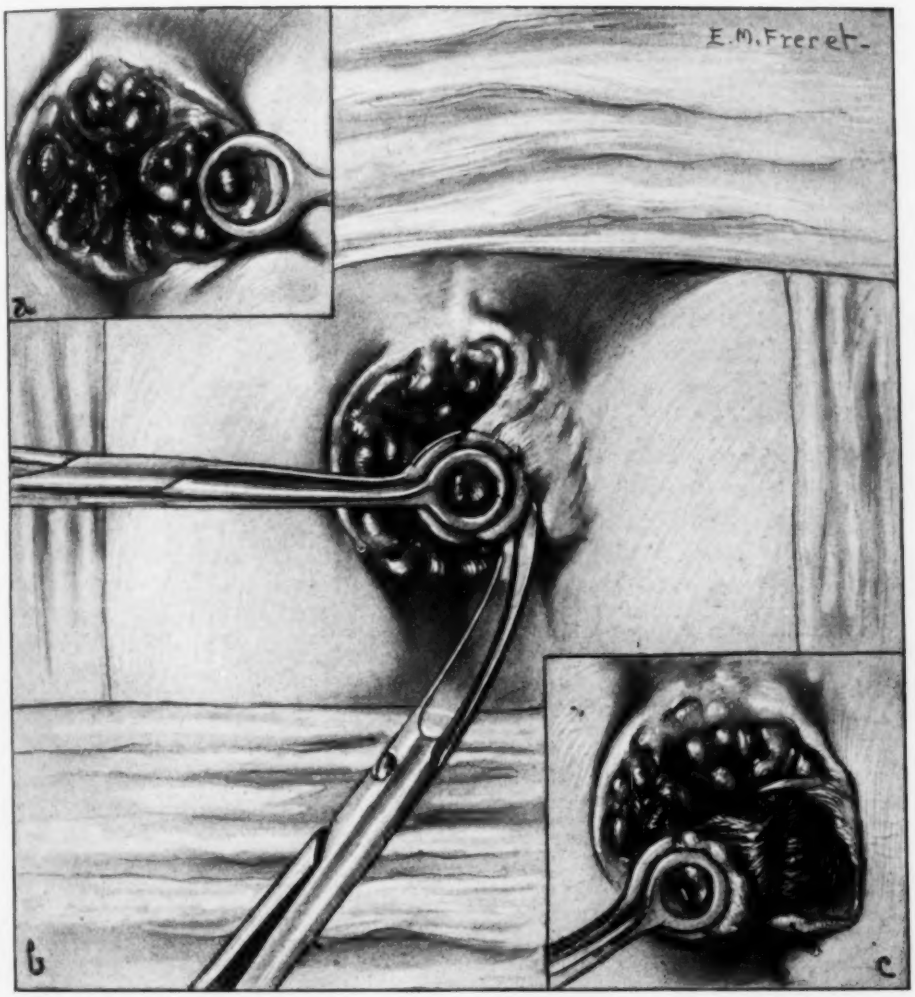

FIG. 2.—The inter-ringed clamp grasping one of the hemorrhoids. *a.*—The larger of the rings is applied to the internal or mucous membrane. *b.*—To show the smaller ring applied to a small skin surface. *c.*—The dissection of the hemorrhoid which is held firmly with this non-slipping clamp.

tion and permits a large amount of slack mucous membrane of the rectal wall to be removed. Two essential requirements of the hemorrhoidal operation are thereby accomplished.

I have often demonstrated the helpfulness of this inter-ringed clamp in deep and difficult dissections of the ampulla of the gall-bladder to free it from intimate adhesions and viscera. The application of the larger ring to the

right side of the ampulla and the smaller ring to its opposite side permits a competent hold of this organ and helps to a clearer exposure of the cystic artery and the cystic duct. For this purpose I have provided the clamp with a long handle (10-inch).

For vaginal operations, necessitating flap elevations and dissection, this instrument has proved extremely useful. It is helpful and comfortable to maintain a purchase on these tissues without the annoyance of their escape by slipping or tearing during the steps of mobilization.

Cystic tumors and organs distended by fluid or gaseous contents may be grasped with comparative security by this inter-ringed clamp. The applied tension can be easily regulated by the pressure exercised through the handles and its notched catches.

WILLIAM L. WOLFSON, M.D.
Brooklyn, N. Y.

PROGRESSIVE LENTICULAR DEGENERATION

WILSON'S DISEASE

WILSON'S DISEASE, known as progressive lenticular degeneration, is a rare condition. Banti's disease likewise is of comparatively rare occurrence and has hepatico-splenic symptoms in common with Wilson's disease. Standard works of pathology and systems of surgery have neglected to cite the similarity and even mention Wilson's disease with Banti's disease.

REPORT OF A CASE.—A boy, aged fourteen, was admitted to hospital May 6, 1931, complaining of his head feeling heavy. April 12 he had had a chill with fever and remained in bed until May 1 when he noticed his feet were swollen. There were red spots on his abdomen and blood in his urine. No history of sore throat. Epistaxis since age of three years. He was of Portuguese birth; apathetic in appearance, temperature 100, pulse 100, respirations 20. *Eyes.*—Pupils react to light and accommodation. *Eyegrounds.*—Negative. *Ears.*—Negative. *Throat.*—Chronic inflamed tonsils. One carious tooth. *Lungs.*—Negative. *Heart.*—$A_2 > P_2$. A soft systolic murmur transmitted to axilla. *Abdomen.*—Liver enlarged 6 centimetres below costal margin. *Spleen* felt, enlarged and tender. No varicosities. *Extremities.*—Marked œdema of both feet and ankles. Patellar reflexes, ankle clonus and Babinski test normal. No petechiæ or discolorations of skin or mucous membranes.

Laboratory Findings.—Röntgenogram of chest and heart showed no changes present. Stool negative. No typhoid organisms isolated. Widal negative. Repeated urinalysis showed heavy albumin and many red blood cells which disappeared after June 2.

On admission blood picture showed hæmoglobin 80 per cent., red blood cells 4,160,000, white blood cells 7,100 (normal differential except for 10 per cent. eosinophilia). On May 24 the eosinophilia was absent.

Discharged June 4 as suffering from acute hæmorrhagic nephritis, with possible Banti's disease.

Readmitted June 23 complaining of constant headache. Appeared sluggish and lethargic, not interested in surroundings. Temperature, pulse, and respiration normal. Liver enlarged to 8 centimetres below costal margin. The lower pole of spleen was felt at level of umbilicus. Icteric color of skin. Vandenbergh test normal, urine showed no bile but heavy albumin and many red blood cells. Œdema of legs absent. Epistaxis daily. Sinus röntgenograms normal. Blood count between July 29 and August 11 remained normal with white blood cells varying from 7,200 to 9,200. Platelets 200,000. Blood clotting and bleeding time normal. Wassermann and Kahn negative. Spinal fluid

8 millimetres mercury pressure, fluid clear and colorless. Cell count 6, globulin very slight trace. Sugar positive. Blood chemistry showed non-protein nitrogen 34 milligrams and sugar 77 milligrams per 100 cubic centimetres of blood. Blood-pressure 100/80.

July 24 subconjunctival hæmorrhages appeared. No wedge-shaped conjunctival thickening as in Gaucher's disease. Patient had a severe vomiting attack. Skin had a brownish-yellow appearance.

With the epistaxis, subconjunctival hæmorrhages, the oncoming emaciation the enlarging spleen and liver, it was decided that surgical intervention was necessary.

July 26, *pre-operative diagnosis,* Banti's disease. *Operation,* splenectomy.

The spleen was four times normal size, smooth of surface and with a few adhesions which were separated with ease from both poles. Gall-bladder thickened with pearl-gray coat and about 14 centimetres in length, greatly enlarged, but emptied easily. Liver enlarged a hand's breadth below the costal margin, surface hobnail, stony hard and suggestive of advanced portal cirrhosis. Small amount of free fluid in abdomen. *Post-operative diagnosis,* Banti's disease.

Post-operative course.—Stormy for three days and then uneventful recovery. White blood cells rose from 6,800 the day before operation to 14,600 on August 3. Discharged August 25 as improved though liver still remained enlarged.

October 21 he was readmitted to hospital after attending school for six weeks. His teacher noticed he was extremely nervous, often crying aloud in the class room. He was ataxic and his hands trembled on effort. There was hypertonicity of all muscles, the elbows were flexed, knees drawn up and the feet held in pes cavus position with toes spread out. Patellar reflex increased, no sensory disturbances, negative Romberg and Babinski tests.

There was an increasing dysphagia with loss of body weight from 98 to 65 pounds in two months. Saliva dripped from mouth, tears would stream from eyes. Violent spasms of facial muscles. The fingers were in hyperflexion, the nails burying themselves into the palmar surfaces and the hands twisted to marked ulnar abduction.

Emaciation rapidly followed and he expired February 16, ten months after onset of subjective symptoms.

Microscopical Report.—Spleen, weight 1,010 grams. There was a diffuse hyperplasia of the pulp with an increase of fibrous connective tissue. No evidence of Gaucher's cells could be found.

Liver.—Section showed advanced atrophic cirrhosis of the liver lobules, the entire field being replaced by fibrous connective tissue. Blood-vessels showed similar overgrowth of fibrous tissue.

Brain.—The areas of the putamen and globus pallidus were necrotic and had the appearance of a tuberculous excavation of the lung. Sections showed no normal parenchymatous tissue; increased vascularity at periphery. No giant cells could be found.

The family history showed this interesting background: *Mother,* age thirty-two. Convulsions in early childhood and again at age of sixteen. One illegitimate child before marriage. Mental age nine. Binet I.Q. 54. Is now in Territorial Hospital for the feeble-minded.

Father, age fifty-four. Heavy alcoholic. Confined to penitentiary for incest with daughter (*a*) at age of twelve.

Siblings.—(*a*) Daughter, age fifteen, in Detention Home for gonorrhœa. No nervous symptoms.

(*b*) Son, age twelve, in home for feeble-minded, mental age three years nine months. Binet I.Q. 44.

(*c*) Son, age ten, attends school. Work poor; stumbles a great deal. Marked twitching of face and hands.

(*d*) Patient, age fourteen, mental age eleven years. Binet I.Q. 79.

FRANCIS J. HALFORD, M.D.
Honolulu, Hawaii

THE PRINCIPLE OF THE LOOP IN BANDAGING

CERTAIN portions of the human anatomy, because of position and conformation, do not lend themselves readily to bandaging. In these locations the use of adhesive plaster may also be contraindicated because of danger of spreading infection and secondly if wet dressings are indicated adhesive tape will not usually hold the dressings in place.

Specifically we are to describe the use of this principle of bandaging to the neck, axilla and breast. We term this a principle because it has a wide range of application and if the surgeon is ingenious he can use this loop principle of bandaging in many other locations other than those to be described.

In the case of neck bandaging the surgeon is hindered by the fact that a tight bandage cannot be applied and that the usual method of bandaging leaves a loose, slipping dressing. In the case of thyroid surgery an adequate rotary bandage cannot be satisfactorily applied because of the lowness of the incision.

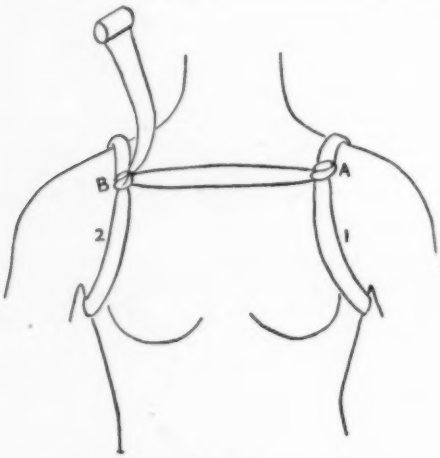

FIG. 1.

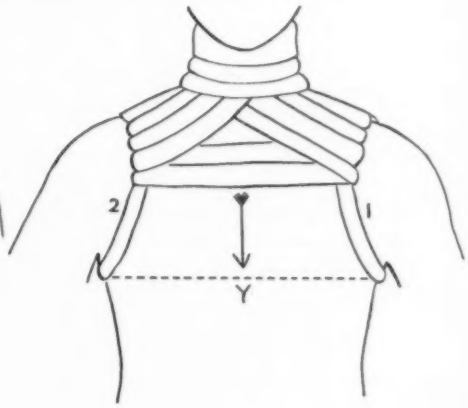

FIG. 2.

Figs. 1 and 2 show the method of application of the loop principle to neck bandaging. Using a 3-inch gauze bandage a loose loop (1) is passed over the shoulder and under the left axilla and tied at point A. The bandage is carried across the chest to point B and loop (2) placed about right axilla and shoulder and tied at point B. It is important that these loops are loosely tied. The bandage (Y) is then used to weave the bandage around neck by figure eight and cross bandaging (Fig. 2), using the loops at each reflection of the bandage to anchor the bandage. The bandaging is done equally anteriorly and posteriorly giving the result as shown in Fig. 2. Arrow (Fig. 2) shows that the bandage can be carried anteriorly if desired as far down as the nipple level and posteriorly to the middle of the scapula. The resulting dressing is fixed without being tight, is comfortable and allows free motion of arms. The dressing can be moistened without any difficulty and there is no adhesive to touch skin. The dressing in our hands has been excellent in surgery of neck, as in thyroid surgery, carbuncles, wounds of upper central portion of chest and shoulders, *etc.*

The axilla is a most frequent site of infection and every one has experienced difficulty in securing a dressing in that location, especially when wet dressings are required. Fig. 4 shows the loop principle of bandaging as applied to the axilla. A loop of bandage is placed loosely around the neck on the side opposite to the axilla to be dressed and a knot tied at the level of the acromial spine on the side of the axilla to be dressed. The bandage is then loosely weaved back and forth as shown in diagram, using the loop for anchoring each turn of the bandage. It is important that the weaving be done to well over the point of the shoulder laterally and to the level of the sternoclavicular joint medially. At first the application of the bandage seems awkward because there is a tendency in the early weaving operation to draw the bandage too tightly and secondly because the weaving is not done uniformly. After several attempts one soon learns to apply a very handsome dressing in this fashion. The arm is given free motion, dressings cannot slip and wet dressings can

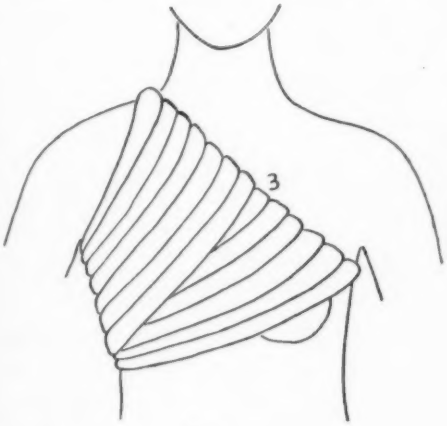

Fig. 3.

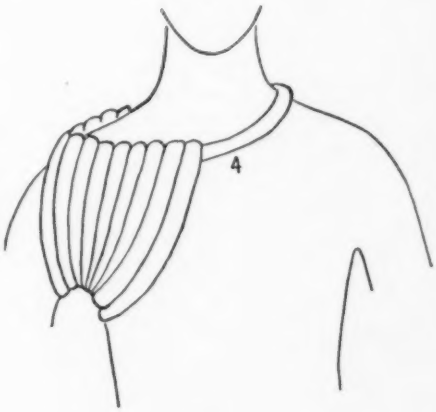

Fig. 4.

readily be maintained. Spreading of infection by tight adhesive dressings to hair follicles and adjacent tissues is eliminated.

Fig. 3 shows the application of the loop principle to breast dressings. A loop (3) is fashioned from the neck on the same side as the breast to be dressed to the axilla on the opposite side. Weaving the bandage from the front to the back over the dressing using the loop as anchor allows the retention of dressings to the breast and again free motion of arms result and wet dressings can be applied.

This form of bandaging has been efficient and a great comfort to us to apply and has been enthusiastically received by the patients. We hope that other surgeons will try not only to use this principle on the specific locations described but also will devise other forms of loop bandaging in other locations.

Victor Carabba, M.D.
Third Surgical Division, Bellevue Hospital
New York, N. Y.

REMOVAL OF BRILLIANT GREEN STAINS

In reply to many inquiries concerning the removal of brilliant green stains from linen, the National Aniline and Chemical Company which manufactures the dye has furnished the following information.

(1) To every 4 ounces of hot soap solution add 1 tablespoon of ordinary hydrogen peroxide. Immerse clothing and leave for some time in the hot solution. Rinse well in cold water and dry.

(2) Stains can also be removed by immersing clothing in a solution prepared by dissolving about 200 grams of sodium perborate in 50 litres of hot water. After immersion the solution should be brought to a boil and allowed to boil for approximately one-half hour. Draw water off and run in fresh water and wash clothing thoroughly. If stains still remain, they can be easily removed by applying good soap or soap powder direct to the stained spots. Then thoroughly rinse and dry clothing.

(3) Almost any common bleaching agent on the market will remove stains.

Joseph K. Narat, M.D.,
Chicago, Ill.

EDITORIAL ADDRESS

The office of the Editor of the Annals of Surgery is located at 386 Park Street, Upper Montclair, New Jersey. All contributions for publication, Books for Review, and Exchanges should be sent to this address.

Remittances for Subscriptions and Advertising and all business communications should be addressed to the

ANNALS OF SURGERY
227-231 South Sixth Street
Philadelphia, Penna.